
Outside-in Meniscal Repair: Technique and Outcomes

12

Jorge Chahla, James Gannon, Gilbert Moatshe,
and Robert F. LaPrade

Contents

12.1	Introduction	129
12.2	Surgical Technique	130
12.3	Outcomes	134
12.4	Discussion	134
	Conclusion	135
	References	135

12.1 Introduction

The menisci play a critical role in the health and longevity of the knee joint. Injuries to the menisci are extremely common, with some attributing it to 75 % of internal knee complications [6]. Historically, meniscus tears were treated by excising part or all of the meniscus. While meniscectomy still remains a viable treatment option in selected cases where a repair is not possible, vast evidence supporting a link between meniscectomy and increased osteoarthritis has prompted further development of repair techniques [13]. Contact pressure in the condyles has been shown to increase by 165 % and 235 % following a partial and total meniscectomy, respectively [9, 13]. This is especially problematic for high-level athletes. Using data from 5047 NFL players from the years 1987 to 2000, Brophy et al. reported that meniscal tears were the fifth most common injury affecting quarterbacks, receivers, offensive line, defensive line, and kickers [2]. While meniscectomies have been found to significantly reduce the career lengths of professional athletes [4], repairs carry high success rates at long-term follow-up. Stein et al. reported on a cohort of 81 athletes that 96.5 % returned to their pre-injury sports activity and expressed significantly less signs of osteoarthritis compared to patients having undergone meniscectomies. They also found a startling contrast between repair and meniscectomy patients, and 96.5 % of repair and 50 % of meniscectomy patients were able to

J. Chahla (✉) • J. Gannon • G. Moatshe
Steadman Philippon Research Institute,
181 W Meadow Drive, Suite 1000, Vail, CO 81657,
USA
e-mail: jachahla@msn.com; jchahla@sprivail.org

R.F. LaPrade
The Steadman Clinic, 181 W Meadow Drive,
Suite 1000, Vail, CO 81657, USA
e-mail: drlaprade@sprivail.org

regain their pre-injury level of activity at a long-term follow-up of 5–8 years [9].

The anterior horn of the medial meniscus has been reported to be particularly important for stabilizing external rotation when the knee is fully extended [3] and also in preventing anterior femoral displacement [12]. In addition, the anterior horn tears of the lateral meniscus were reported to significantly increase tibio-femoral contact pressures in both compartments of the knee [7]. Studies have reported that repair of these tears restores condyle contact pressures to normal values [7]. Consequently, surgical repair is indicated whenever possible for all anterior horn tears. It is also important to recognize and treat anterior horn meniscal cysts, primarily of the lateral meniscus, as complete meniscal tears because solely debridement of anterior horn tears can destabilize the meniscus and lead to pain and decreased function. Current literature regarding the treatment of tears of the anterior horn of the menisci is very limited.

Commonly used techniques for meniscal repair include the inside-out, outside-in, and all-inside techniques. Warren et al. first described the outside-in meniscus repair in 1985, having been prompted to develop a technique that avoids the knee's critical neurovascular structures, specifically the peroneal nerve and saphenous nerve for the lateral and medial meniscus, respectively [1, 4, 8, 10]. Thirty-one years later, the technique has greatly evolved, with improved surgical technique and instrumentation being widely used presently (Fig. 12.1).

This procedure has the benefits of small incisions, low neurovascular risk, and high success rate [1, 4]. The outside-in repair technique is ideal for anterior horn tears because it allows for adequate access to the anterior horn of the meniscus, provides a stable fixation construct, and avoids leaving prominent intra-articular material with a minimal approach. The purpose of this chapter is to describe the surgical technique of outside-in repair of anterior horn meniscal tears, rehabilitation, and outcomes of this procedure.

12.2 Surgical Technique

A diagnostic arthroscopy is first performed through standard anterolateral and anteromedial portals to confirm and evaluate the meniscal pathology, as well as any concurrent pathology. After confirmation of the anterior horn tear, the arthroscope should be placed through the contralateral portal of the compartment of the involved meniscus to visualize the extent and characteristics of the tear. A 3 cm vertical incision is made in line with the portal on the same side of the knee as the anterior meniscal tear. Careful dissection is performed through the subcutaneous tissues to expose the underlying anterior joint capsule (Fig. 12.2).

To begin the outside-in repair, a spinal needle is introduced by piercing the overlying capsule, advancing it under the anterior edge of the medial or lateral meniscus (depending on the case), and through the body of the anterior horn, thus traversing the area of the tear (Fig. 12.3).

The inner cannula of the needle is removed, and a #1 PDS suture (Ethicon, Inc., Johnson & Johnson, Somerville, NJ, USA) is placed through the needle and into the joint (Fig. 12.4).

Similarly, a second needle is passed through the capsule, underneath the anterior edge of the meniscus, and through the body of the anterior horn. The inner cannula is again removed, and a looped suture retriever is passed through the second needle and into the joint. The free end of the previously passed PDS suture is then pulled through the looped retriever using a grasper and the suture pulled back out of the knee creating a mattress suture construct to secure the anterior horn (Fig. 12.5).

Multiple sutures are added to strengthen the construct (Fig. 12.6). Either a horizontal or vertical mattress suture configuration can be utilized, depending on the nature of the tear and the surgeon's preference.

Once the repair is complete, the sutures are tied to the anteromedial/lateral capsule with the knee flexed to 90° (Fig. 12.7). The arthroscope is inserted again, and the final construct is probed and assessed to confirm stability of the repair construct.

Fig. 12.1 Schematic diagram of a left knee (disarticulated from the femur) demonstrating an anterior horn tear of the medial meniscus being repaired with an outside-in technique with spinal needles

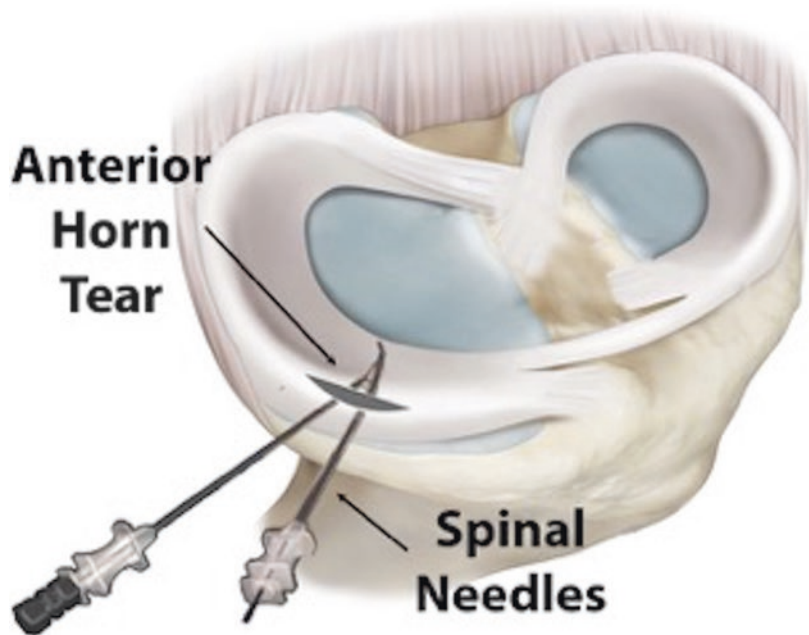
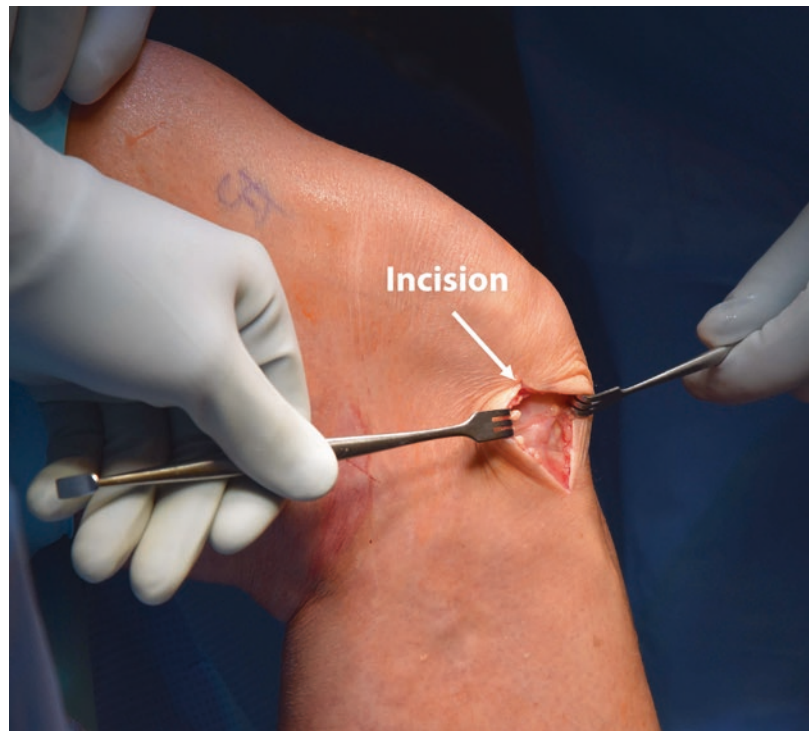

Fig. 12.2 A vertical incision (*arrow*) is made through the skin and subcutaneous tissues on a right knee to expose the joint capsule by extending the lateral portal incision 2–3 cm, which is on the ipsilateral side of the affected (lateral) meniscal tear



Postoperative Recovery and Rehabilitation For repairs performed in isolation, the patient is placed in a knee immobilizer in full extension and allowed partial weight bearing with crutches for

the first 6 weeks. Physical therapy is initiated on postoperative day #1 to begin working on passive range of motion exercises. Knee flexion is limited to 0–90° for the first 4 weeks and then progressed

Fig. 12.3 (a) Intraoperative and (b) arthroscopic view. A spinal needle (*arrow*) is advanced through the lateral capsule, under the anterior edge of the torn lateral meniscus, and through the meniscal body on a right knee. A 30° arthroscope (*arrow*) is placed through the contralateral medial portal for adequate visualization

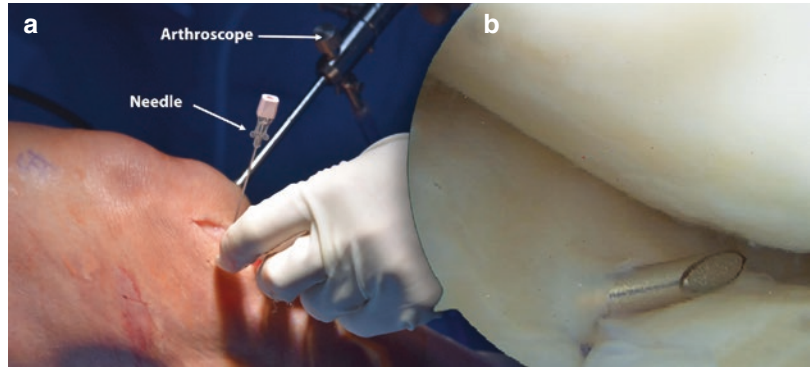


Fig. 12.4 The inner cannula of the needle (*arrow*) is removed, and a PDS suture (*arrow*) is passed through the needle, thus traversing the anterior lateral meniscal tear as visualized using a 30° arthroscope through the contralateral medial portal of a right knee

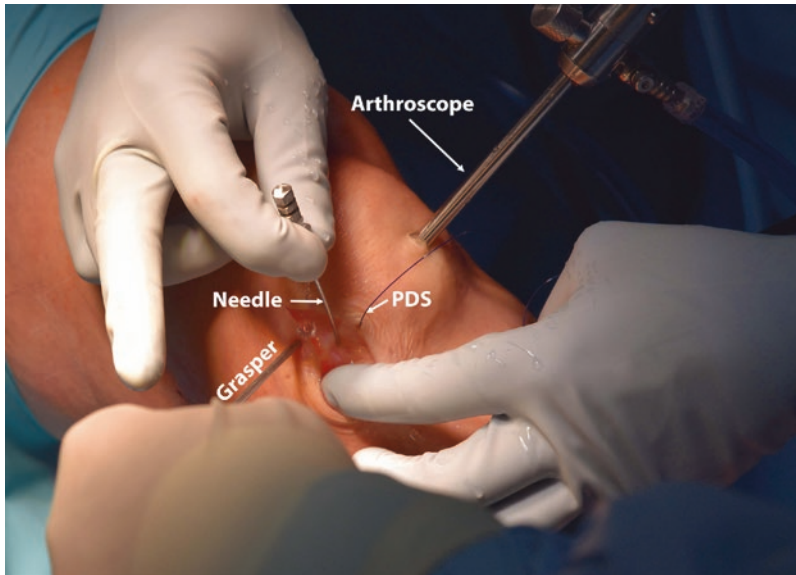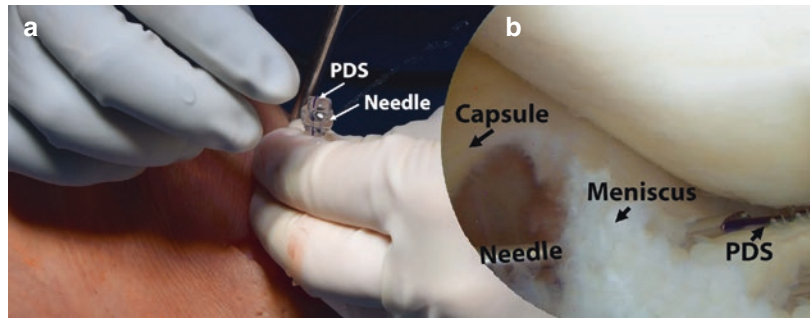


Fig. 12.5 The spinal needle (*arrow*) is passed a second time in a similar manner as before through the lateral incision of a right knee, and the free end of the previously passed PDS suture (*arrow*) is retrieved through the spinal needle using a grasper (*arrow*) and looped suture retriever.

The grasper is placed through a second lateral working portal. This creates a horizontal or vertical mattress suture across the anterior horn of the lateral meniscus, depending on the type of tear and surgeon preference. A 30° arthroscope (*arrow*) is present in the medial portal

Fig. 12.6 Two PDS sutures (*arrows*) have been passed in a horizontal mattress configuration to repair the lateral meniscal tear of a right knee as viewed with a 30° arthroscope through the medial portal

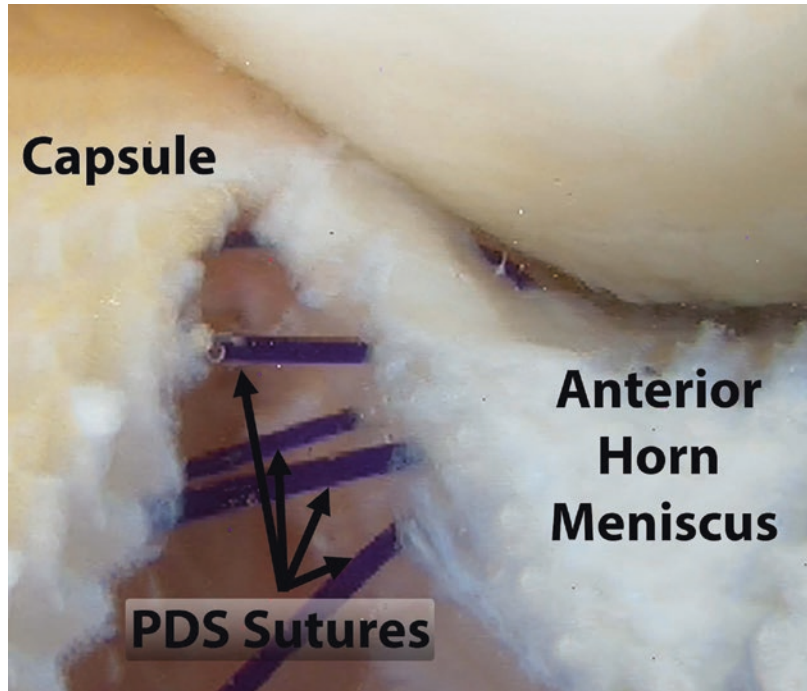
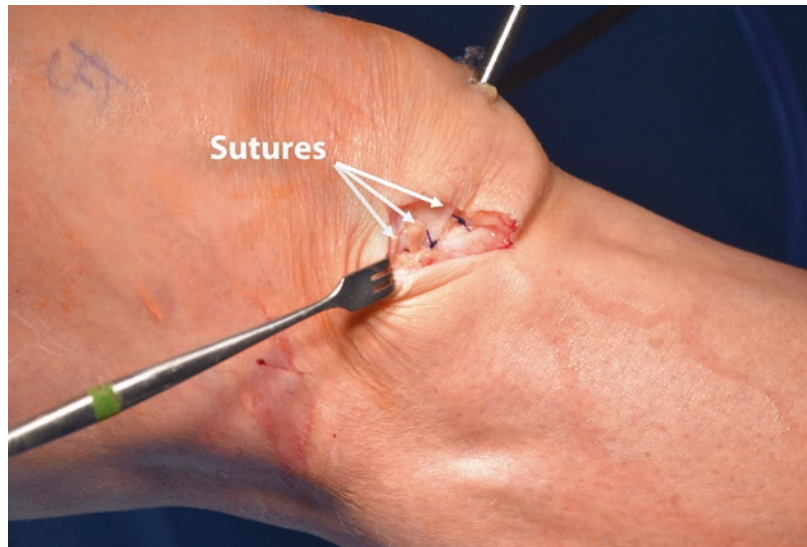


Fig. 12.7 The suture tails (*arrows*) are appropriately tensioned and tied over the lateral joint capsule of a right knee, thus securing the anterior horn of the lateral meniscus to the capsule to allow healing of the tear



as tolerated. Any significant squatting, lifting, or sitting cross-legged is prohibited for a minimum of 4 months to avoid excess stress on the meniscal repair.

12.3 Outcomes

Due to the prevalence of meniscal injuries, many studies have investigated the outside-in technique and how it compares to other repair procedures.

Van Trommel et al. reported a success rate of 76 % with their cohort of 51 patients treated with outside-in meniscus repair, using a combination of radiographs, second-look arthroscopy, and MRI. Patients without these records were excluded. Despite a 76 % reported success rate, only 45 % of these patients had complete meniscal healing, while 31 % had partial healing at the time of follow-up [10]. Morgan et al. found similar results, citing an 84 % success rate out of 74 repairs evaluated by second-look arthroscopy. All 84 % were asymptomatic at final follow-up. The average time from surgery to repair was 8.5 months. Similar to Van Trommel, only 65 % of the repairs completely healed, while 19 % partially healed. It is worth noting that the average time from repair to follow-up for the partially healed group was approximately half of the length of time for the entire cohort. The authors strongly believe that this influenced their results [6]. Abdelkafy et al. reported on a cohort of 41 meniscal repairs at a mean follow-up of 11.71 years (range 2–19 years), using standard clinical evaluation techniques, such as radiographs, to assess knee health. Five of the 41 procedures failed, meaning they received revision repair or meniscectomy [1]. Hantes et al. evaluated 17 outside-in repairs at a mean follow-up of 23 months. Patients were evaluated for joint effusion, sensitivity, and a negative McMurray test, and if these test were negative, the meniscus was considered healed. Based on this scoring system, 100 % of the repairs were successful [5].

Venkatachalam et al. used a cohort of 62 repairs in 59 patients from the years 1994 to 1999. Successful repair in their study had to meet the following criteria: the patient had little to no pain, no locking, and no revision surgeries. The average time until follow-up was 21 months. No clinical evaluation was used. Instead, patients were mailed a self-examination, which they filled out and sent back. The overall reported success rate is 66.1 %, a value we believe to be more realistic than other studies [11]. Lastly, Dave et al. conducted a literature review of outcome studies of the outside-in technique and found that reported success rates ranged from 50 to 91 % [4]. One potential explanation is the varying definition of success.

Meniscal repair outcomes are assessed in a heterogeneous manner. A “failure” does not necessarily imply that the patient is symptom free or that the meniscus completely healed. A failed procedure commonly refers to a patient that received no alleviation of symptoms postsurgery and likely required either a revision repair or a meniscectomy. Upon second-look arthroscopic examination, partial healing usually presents with a mostly healthy appearance but with repeated high-signal intensity in MRI. It is still to be determined what is clinically relevant since many partially healed menisci are asymptomatic [8].

12.4 Discussion

Since its inception in 1985, the outside-in repair technique has become a landmark procedure in the treatment of meniscal tears. The small incisions, low risk of neurovascular injuries, and high success rate make it a reliable method of repair, particularly for tears in the anterior two-thirds of the meniscus. Anterolateral and anteromedial meniscus tears have been shown to drastically increase contact pressure throughout both compartments of the knee, making this technique particularly valuable.

Conversely, success rates for tears to the posterior meniscus are not as high. Several studies have commented on the increased failure and complication rate with tears to the posterior horn [1, 4, 6, 10], which some believe to be due to the difficulty in accessing the region [8]. The outside-in repair has also been recognized as an effective alternative to the meniscectomy, which significantly increases condyle contact pressure and leads to osteoarthritis in the long term [13]. Furthermore, repair has proven to be more effective at returning patients to sport and pre-injury activity level [4, 9]. However, particularly debilitating tears, including radial tears, displaced tears, and tears in avascular zones, may be technically challenging to repair. Due to the deleterious effects of meniscectomy, a meniscal repair should always be attempted first.

Reported outcomes of the outside-in repair are consistently high; however, various authors disagree on how clinical relevance should be defined. But while an exact estimate of success with the outside-in repair is difficult to find, the technique is still highly effective at alleviating symptoms and returning patients to their pre-injury level of activity [1, 4–6, 8, 10, 11].

Conclusion

Meniscal tears are one of the most common knee injuries. If left untreated, this condition can have long-lasting impacts on a patient's knee health and overall activity level. Since 1985, the outside-in repair has been a reliable tool for the treatment of anterior horn meniscal tears. It is our belief that any practicing sports medicine surgeon should be comfortable with this procedure, as it will ensure the best possible short- and long-term outcomes for patient health and quality of life.

References

1. Abdelkafy A, Aigner N, Zada M, Elghoul Y, Abdelsadek H, Landsiedl F. Two to nineteen years follow-up of arthroscopic meniscal repair using the outside-in technique: a retrospective study. *Arch Orthop Trauma Surg.* 2007;127(4):245–52.
2. Brophy RH, Barnes R, Rodeo SA, Warren RF. Prevalence of musculoskeletal disorders at the NFL combine-trends from 1987 to 2000. *Med Sci Sports Exerc.* 2007;39(1):22–7.
3. Chen LX, Linde-Rosen M, Hwang SC, Zhou JB, Xie Q, Smolinski P, Fu FH. The effect of medial meniscal horn injury on knee stability. *Knee Surg Sports Traumatol Arthrosc.* 2015;23(1):126–31.
4. Dave LYH, Caborn DNM. Outside-in meniscus repair: the last 25 years. *Sports Med Arthrosc.* 2012;20(2):77–85.
5. Hantes ME, Zachos VC, Varitimidis SE, Dailiana ZH, Karachalios T, Malizos KN. Arthroscopic meniscal repair: a comparative study between three different surgical techniques. *Knee Surg Sports Traumatol Arthrosc.* 2006;14(12):1232–7.
6. Morgan CD, Wojtys EM, Casscells CD, Casscells SW. Arthroscopic meniscal repair evaluated by second-look arthroscopy. *Am J Sports Med.* 1991;19(6):632–7. discussion 637–8. PubMed PMID: 1781503
7. Prince MR, Esquivel AO, Andre AM, Goitz HT. Anterior horn lateral meniscus tear, repair, and meniscectomy. *J Knee Surg.* 2014;27(3):229–34.
8. Rodeo SA. Arthroscopic meniscal repair with use of the outside-in technique. *J Bone Joint Surg Am.* 2000;82A(1):127–41.
9. Stein T, Mehling AP, Welsch F, von Eisenhart-Rothe R, Jager A. Long-term outcome after arthroscopic meniscal repair versus arthroscopic partial meniscectomy for traumatic meniscal tears. *Am J Sports Med.* 2010;38(8):1542–8.
10. Van Trommel MF, Simonian PT, Potter HG, Wickiewicz TL. Different regional healing rates with the outside-in technique for meniscal repair. *Am J Sports Med.* 1998;26(3):446–52.
11. Venkatachalam S, Godsiff SP, Harding ML. Review of the clinical results of arthroscopic meniscal repair. *Knee.* 2001;8(2):129–33.
12. Walker PS, Arno S, Bell C, Salvatore G, Borukhov I, Oh C. Function of the medial meniscus in force transmission and stability. *J Biomech.* 2015;48(8):1383–8.
13. Yoon KH, Park KH. Meniscal repair. *Knee Surg Relat Res.* 2014;26:68–76.