

# Quantitative Assessment of the Coracoacromial and the Coracoclavicular Ligaments With 3-Dimensional Mapping of the Coracoid Process Anatomy: A Cadaveric Study of Surgically Relevant Structures

Jorge Chahla, M.D., Ph.D., Daniel Cole Marchetti, B.A., Gilbert Moatshe, M.D., Márcio B. Ferrari, M.D., George Sanchez, B.S., Alex W. Brady, M.Sc., Jonas Pogorzelski, M.D., M.H.B.A., George F. Lebus, M.D., Peter J. Millett, M.D., M.Sc., Robert F. LaPrade, M.D., Ph.D., and CAPT Matthew T. Provencher, M.D., M.C., U.S.N.R.

**Purpose:** To perform a quantitative anatomic evaluation of the (1) coracoid process, specifically the attachment sites of the conjoint tendon, the pectoralis minor, the coracoacromial ligament (CAL), and the coracoclavicular (CC) ligaments in relation to pertinent osseous and soft tissue landmarks; (2) CC ligaments' attachments on the clavicle; and (3) CAL attachment on the acromion in relation to surgically relevant anatomic landmarks to assist in planning of the Latarjet procedure, acromioclavicular (AC) joint reconstructions, and CAL resection distances avoiding iatrogenic injury to surrounding structures. **Methods:** Ten nonpaired fresh-frozen human cadaveric shoulders (mean age 52 years, range 33-64 years) were included in this study. A 3-dimensional coordinate measuring device was used to quantify the location of pertinent bony landmarks and soft tissue attachment areas. The ligament and tendon attachment perimeters and center points on the coracoid, clavicle, and acromion were identified and subsequently dissected off the bone. Coordinates of points along the perimeters of attachment sites were used to calculate areas, whereas coordinates of center points were used to determine distances between surgically relevant attachment sites and pertinent bony landmarks. **Results:** The CAL had a single consistent acromial attachment (mean area 77 mm<sup>2</sup> [51.9, 102.2]) and then bifurcated into 2 bundles, anterior and posterior, that separately inserted on the lateral aspect of the coracoid. The footprint areas were 54.4 mm<sup>2</sup> [31.7, 77.2] and 30.6 mm<sup>2</sup> [23.4, 37.7] for the anterior and posterior CAL bundles, respectively. These anterior and posterior bundles attached 10.6 mm [8.4, 12.9] and 24.8 mm [12.3, 27.4] medial and proximal to the apex of the coracoid process, respectively. The minimum distance between the coracoid apex and the trapezoid ligament was 25.1 mm [22.1, 28.1] and was noted to be different in males (28.1 mm [25.1; 31.2]) and females (22.0 mm [18.2, 25.9]). The most lateral insertion of the CC ligaments on the clavicle the AC joint was 15.7 mm [13.1, 18.3]. The distance between the most medial to the most lateral point of the CC ligaments on the clavicle was 25.6 mm [22.3, 28.9], which accounted for 18.2% [15.8, 20.6] of the clavicle length. **Conclusions:** In contrast to previous findings, 2 different coracoid attachments (anterior and posterior bundles) of the CAL were consistently identified in all specimens. Moreover, a coracoid osteotomy for a bone graft for the Latarjet procedure should be performed at less than 28.1/22 mm from the apex of the coracoid in male/female

*From the Steadman Philippon Research Institute (J.C., D.C.M., M.F., G.S., A.W.B., J.P., G.F.L., P.J.M., R.F.L., M.T.P.); The Steadman Clinic (G.M., G.F.L., P.J.M., R.F.L., M.T.P.), Vail, Colorado, U.S.A.; Oslo University Hospital (G.M.); and OSTRC, Norwegian School of Sports Sciences (G.M.), Oslo, Norway.*

*The authors report the following potential conflicts of interest or sources of funding: G.M. has grants/grants pending from Health East, Norway and NIH R-13 grant for biologics. P.J.M. receives consultancy fees and royalties from Arthrex, Medbridge, and Springer; has grants/grants pending from Smith & Nephew, Arthrex, Siemens, and Ossur; owns stock and stock options in GameReady and VuMedi; and receives financial support for a part of his research from Arthrex. R.F.L. receives consultancy fees from Arthrex, Smith & Nephew, and Ossur; has grants/grants pending from Health East, Norway, and NIH R-13 grant for biologics; has patents (planned, pending, or issued) from Ossur and Smith & Nephew; and receives royalties from Arthrex, Ossur, and Smith & Nephew. M.T.P. is a consultant for Arthrex and JRF Ortho; and*

*has patent numbers (issued): 9226743, 20150164498, 20150150594, 20110040339; receives royalties from Arthrex and SLACK (publishing royalties); Steadman Philippon Research Institute receives research support from Smith & Nephew, Arthrex, DePuy Synthes, Siemens, Ossur, and Vail Valley Medical Center. Full ICMJE author disclosure forms are available for this article online, as [supplementary material](#).*

*Received July 7, 2017; accepted November 27, 2017.*

*Address correspondence to CAPT Matthew T. Provencher, M.D., M.C., U.S.N.R., Steadman Philippon Research Institute, The Steadman Clinic, 181 West Meadow Drive, Suite 400, Vail, CO 81657, U.S.A. E-mail: [mattprovencher@gmail.com](mailto:mattprovencher@gmail.com) or [mmpro@mac.com](mailto:mmpro@mac.com)*

*© 2017 Published by Elsevier on behalf of the Arthroscopy Association of North America*

*0749-8063/17784/\$36.00*

*<https://doi.org/10.1016/j.arthro.2017.11.033>*

patients, respectively. The CC ligaments' attachments on the clavicle were located 15.7 mm from the AC joint, which should be considered for reconstruction. **Clinical Relevance:** During the Latarjet technique, to maintain the integrity of the CC ligaments, precise knowledge of differences between male and female anatomy is necessary during a coracoid osteotomy. Furthermore, when reconstructing the AC joint, the distance from the lateral aspect of the clavicle and the size of the attachments areas should be considered to better replicate the native anatomy.

The coracoid process serves as the attachment site for many structures, including the conjoint tendon of the coracobrachialis and the short head of the biceps, the pectoralis minor muscle, the coracoacromial ligament (CAL), the coracoclavicular (CC) ligaments, and the coracohumeral ligament. Given the close proximity and intimate relations of these important structures, a precise, quantitative understanding of their relations is crucial to the successful surgical management of pathology in this region.<sup>1-4</sup> For example, the CAL has been formerly described as a flat triangular band extending from the coracoid process to the acromion.<sup>5</sup> Currently, the literature includes reports of the CAL origin from the apex of the acromion,<sup>6</sup> from the medial or inferior border,<sup>7</sup> or even from the broader extent of the inferior surface of the acromion.<sup>5,8</sup> The precise anatomic location of the CAL is important to consider in the setting of many procedures including acromioplasty and capsular repair in the Latarjet procedure. Furthermore, understanding the intricate anatomy of the CAL may aid surgeons to anatomically repair or reconstruct this structure because the disruption of the coracoacromial arc has been associated with superior migration of the humeral head.<sup>9,10</sup>

Modern techniques in shoulder surgery emphasize the importance of detailed knowledge of the native anatomy to avoid iatrogenic injury to important anatomical structures.<sup>11,12</sup> In the Latarjet procedure,<sup>13</sup> the coracoid process is osteotomized and transferred along with the conjoint tendon of the coracobrachialis and short head of the biceps tendon to the anterior glenoid rim to treat glenoid bone loss and restore glenohumeral joint stability.<sup>14</sup> Limited literature exists regarding the anatomical gender differences pertinent to performing an osteotomy of the coracoid. In addition, in cases of acromioclavicular (AC) joint dislocation,<sup>15-21</sup> in which the CC ligaments are torn, their original attachments may be difficult to identify. In these cases, other landmarks should be used to guide anatomical reconstruction. Rios et al.<sup>4</sup> suggested that the medial edge of the bony tunnels could be calculated as percentages of the clavicular length (as measured from the lateral border of the clavicle). Thus, the tunnels for the reconstructed conoid and trapezoid ligaments should be created on the superior clavicle, at a point representing 30% and 17% of the clavicle length, respectively. In addition, Salzmann et al.<sup>2</sup> found that

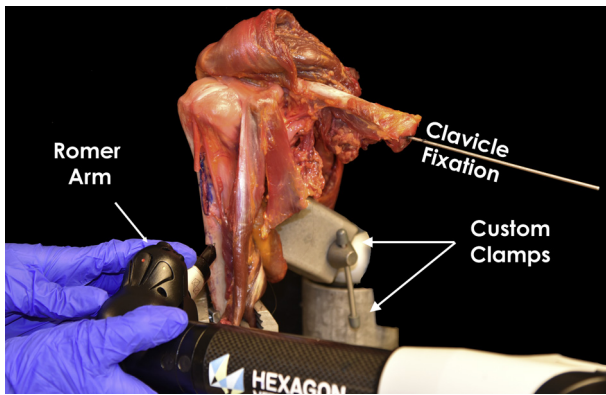
the CC ligament footprints could be reproducibly predicted with respect to the medial border and the "precipice" of the coracoid process. These 2 studies provide baseline data that can be used to guide anatomic reconstruction of the CC ligaments.<sup>2,4</sup>

A limited number of reports<sup>2,4,22,23</sup> have documented the qualitative anatomy of the structures attaching to the coracoid process. Likewise, limited quantitative data exist that characterize the intricate anatomy of this region. Thus, the purposes of this study were to perform a quantitative anatomic evaluation of (1) the coracoid process and more specifically the attachment sites of the conjoint tendon, the pectoralis minor, the CAL, and the CC ligaments in relation to pertinent osseous and soft tissue landmarks; (2) the CC ligaments' attachments on the clavicle; and (3) the CAL attachment on acromion in relation to surgically relevant anatomic landmarks to assist in planning of the Latarjet procedure, AC joint reconstructions, and CAL resections to avoid iatrogenic injury to surrounding structures. We hypothesized that consistent attachment areas and distances to relevant surgical landmarks would be identified.

## Methods

### Specimen Preparation

Ten nonpaired, fresh-frozen human cadaveric shoulders with no prior injury, surgical history, or gross anatomic abnormality (mean age 52 years, range 33-64 years, 5 female, 5 male, 5 right side, 5 left side) were included in this study following the design of previously published anatomic studies.<sup>24-29</sup> The cadaveric specimens used in this study were donated to a tissue bank for medical research and then purchased by our institution. All specimens were stored at  $-20^{\circ}\text{C}$  and thawed at room temperature for 24 hours before preparation. The humeral diaphyses were cut 15 cm from the shoulder joint line. All soft tissue within 10 cm of the joint line was preserved. The clavicle was fixed with 2 Kirschner wires (one from the medial aspect of the clavicle to the body of the scapular and a second wire from the acromion to the clavicle) in an anatomical position, which was verified by 3 orthopaedic surgeons (J.C., G.M., and M.F.). Afterward, the scapula was fixed in a custom shoulder clamp to avoid any further movement throughout data collection (Fig 1).



**Fig 1.** A photograph of a right shoulder illustrating the experiment setup. The clavicle was fixed to the scapula with 2 Kirschner wires, and the scapula was fixed in a custom-made clamp to prevent movement of the specimen during data collection. A coordinate measuring device was used for data collection.

### Quantitative Measurements

A portable coordinate measuring device (7315 Romer Absolute Arm, Hexagon Metrology, North Kingstown, RI) was used to quantify the location of pertinent bony landmarks and areas of the ligament and tendon footprints. All fine dissections were carried out by 2 orthopaedic physicians (J.C. and G.M.), and the measurements performed in agreement by both surgeons (because the ligaments could only be resected once from the attachments).

All pertinent bony and soft tissue landmarks were identified and measured using the coordinate measuring device with the scapula rigidly fixed in place. Sites mapped on the coracoid included the attachments of the conjoint tendon, the pectoralis minor tendon, the trapezoid and conoid CC ligaments, the anterior and posterior CAL bundles, and the line of the anterior CAL bundle occupied by the conjoint tendon. Next, the clavicle was disarticulated from the AC joint. Care was taken to maintain the stumps of the conoid and trapezoid ligaments in place on its inferior surface. The clavicle was then securely clamped in anatomical position, and the attachments were identified, including the most medial and lateral aspects of the CC ligament footprints, the areas of the ligament footprints, and the central points of each individual ligament. The clavicle length was also recorded medially to laterally (as a 2-point measurement) to calculate the distance from the AC joint to the CC ligament perimeter and insertion as a percentage of total clavicular length. Finally, the points of interest on the acromion were identified and collected. These included the CAL acromial attachment and the most anteromedial, anterolateral, and posterolateral aspect of the acromion.

### Data Analysis

Data were analyzed with custom software (MATLAB 2008b, The MathWorks, Natick, MA). Distance

measurements were collected as the 3-dimensional linear distances between structures and were referred to as direct distances. Unless otherwise noted, all anatomical distance measurements were measured between the centers of the 2 structures. Cross-sectional areas were computed by projecting points taken along the circumference of the attachment onto an interpolated plane and calculating the area of the resulting 2-dimensional polyhedron. Average (mean) measurements across the 10 specimens were computed with lower and upper 95% confidence intervals (CIs).

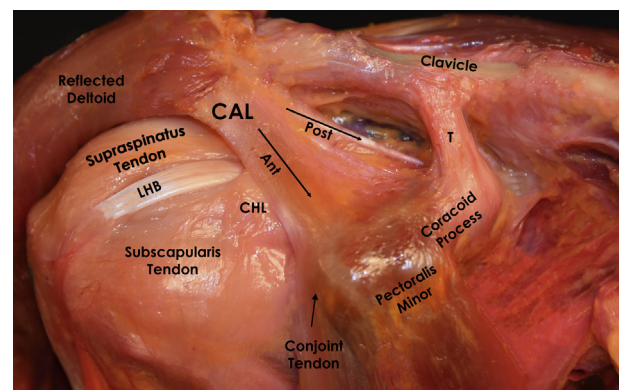
## Results

All results are expressed as means with 95% CIs [lower bound, upper bound]. Distances are reported in millimeters (mm) and areas in  $\text{mm}^2$ .

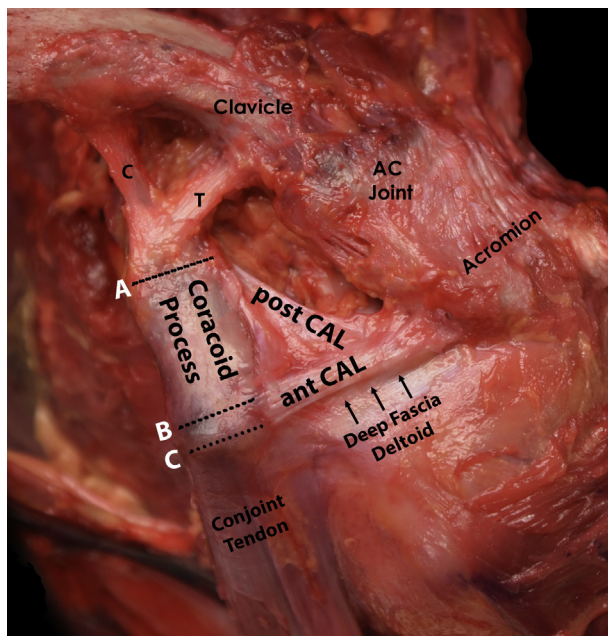
### Qualitative Anatomy

The conjoint tendon, formed by the short head of the biceps tendon and the coracobrachialis tendon, attached near the apex of the coracoid with an elliptical insertion and a larger transverse diameter. In addition, the conjoint tendon partially attached to the most lateral aspect of the anterior CAL bundle. The CAL had a bifurcation that resulted in 2 distinct attachments on the lateral surface of the coracoid. The acromial attachment of the CAL was located on the inferior surface of the anteromedial and anterolateral aspect of the acromion (Fig 2).

The deep fascia of the deltoid attached to the most anterior aspect of the anterior CAL (Fig 3). The coracohumeral ligament attached broadly on the inferior aspect of the coracoid, just inferior to the posterior CAL. The pectoralis minor tendon attached on the



**Fig 2.** Cadaveric image of a right shoulder with the deltoid reflected. The attachment sites of the anterior coracoacromial ligament (CAL) bundle and the posterior CAL bundle, and the coracohumeral ligament (CHL) are found on the lateral aspect of the coracoid process, whereas the attachment site of the pectoralis minor is on the medial aspect of the coracoid. The trapezoid ligament (T) is depicted inserting into the coracoid and the clavicle. The long head of the biceps tendon (LHB) is shown after dissection of the rotator cuff interval.



**Fig 3.** Finely dissected left shoulder displaying the coracoid (C) and trapezoid (T) coracoclavicular ligament and coracoacromial ligament (CAL) bundles. The deep fascia of the deltoid is shown attaching to the anterior CAL bundle. Note that overlap was observed between the conjoint tendon and the anterior CAL bundle. The distances measured from the most distal attachment of the trapezoid (A) to the superior tip of the coracoid process (B) and the tip of the coracoid (C). (AC, acromioclavicular; ant CAL, anterior coracoacromial ligament; post CAL, posterior coracoacromial ligament.)

superomedial side of the coracoid, posterior to the conjoint tendon attachment and anterior to the trapezoid ligament insertion in an oblong elliptical insertion. The trapezoid ligament attached on the superior surface of the coracoid with some fibers extending to the medial surface of the coracoid, posterior to the pectoralis minor insertion and anterior to the conoid

ligament. The conoid ligament attached to the base of the coracoid. The conoid insertion was primarily on the superior part of the coracoid but also extended medially in a C-shaped form. In some specimens, the conoid and trapezoid ligament fibers joined at the base (Fig 3). The conoid and trapezoid ligaments coursed laterally to insert on the inferior surface of the clavicle. The conoid inserted posteriorly on the conoid tubercle in a C-shaped area and the trapezoid ligament on the trapezoid line more anteriorly (elliptical insertion).

### Quantitative Coracoid Anatomy

The footprint attachment areas of the ligaments and tendons of interest are reported in Table 1, and distances between the center points of all ligaments, tendons, and osseous landmarks are reported in Table 2. The average length of the coracoid from the base to the tip was 41.4 mm (95% CI [38.2, 44.5]).

### Surgically Relevant Attachment Areas

**Tendons.** The 2 major tendons attaching to the coracoid process were the conjoint tendon (on the apex) and the pectoralis minor tendon (on the medial side). The area of the conjoint tendon footprint was 48.9 mm<sup>2</sup> [35.6, 62.2]. Of note, the conjoint tendon had a linear insertion on the distal and anterior aspect of the anterior CAL bundle that measured 7.1 mm [5.4, 8.8]. The pectoralis minor footprint was 42 mm<sup>2</sup> [32.2, 50.7].

**Ligaments.** Four ligaments attached to the coracoid process: the CAL (both anterior and posterior CAL bundles), the trapezoid ligament, the conoid ligament, and the coracohumeral ligament. The CAL bifurcated into 2 footprints on the superolateral aspect of the coracoid. The footprint areas were 54.4 mm<sup>2</sup> [31.7, 77.2] and 30.6 mm<sup>2</sup> [23.4, 37.7] for the anterior CAL and posterior CAL bundles, respectively. The coracohumeral ligament inserted just inferior to the posterior CAL at a mean distance of 11.6 mm [7.1, 16.1].

**Table 1.** Attachment Areas for the Ligaments and Tendons Attaching to the Coracoid Process, Acromion, and Clavicle

Structure	Coracoid			Acromion			Clavicle		
	Mean Area	Lower 95% CI	Upper 95% CI	Mean Area	Lower 95% CI	Upper 95% CI	Mean Area	Lower 95% CI	Upper 95% CI
<b>CA ligaments</b>									
Anterior	54.4	31.7	77.2	77	51.9	102.2	N/A	N/A	N/A
Posterior	30.6	23.4	37.7				N/A	N/A	N/A
<b>CC ligaments</b>									
Trapezoid	44.3	32.7	55.9	N/A	N/A	N/A	60.6	43.8	77.5
Conoid	37	31.8	42.2	N/A	N/A	N/A	47.5	37.5	57.5
<b>Tendons</b>									
Pectoralis minor	42	33.2	50.7	N/A	N/A	N/A	N/A	N/A	N/A
Conjoint tendon	48.9	35.6	62.2	N/A	N/A	N/A	N/A	N/A	N/A

CAL, coracoacromial ligaments; CC, coracoclavicular; CI, confidence interval.

**Table 2.** Distances, Reported as Mean With Lower (L) and Upper (U) 95% Confidence Intervals, Between Ligaments, Tendons, and Osseous Landmarks of the Coracoid Process

Distance From	Distance To	Coracoid Base	Conoid Center	Trapezoid Center	Posterior CAL Center	Anterior CAL Center	Pec Minor Center	Conjoint Tendon Center
Coracoid apex	Mean	41.4	33.9	27.0	24.8	10.7	12.1	3.0
	L 95% CI	38.2	30.6	23.7	22.3	8.4	10.7	1.9
	U 95% CI	44.5	37.2	30.3	27.4	12.9	13.5	4.2
Coracoid base	Mean		10.1	17.7	20.5	34.3	33.4	41.6
	L 95% CI		7.9	16.1	17.8	30.8	30.4	38.7
	U 95% CI		12.3	19.4	23.2	37.8	36.4	44.6
Anterior CAL center	Mean	34.3	26.0	19.1	15.6		12.6	11.1
	L 95% CI	30.8	21.8	15.5	13.2		11.3	9.3
	U 95% CI	37.8	30.2	22.8	18.1		13.8	12.8
Posterior CAL center	Mean	20.5	13.5	9.9		15.6	20.3	25.2
	L 95% CI	17.8	10.7	8.3		13.2	17.6	22.5
	U 95% CI	23.2	16.4	11.5		18.1	23.1	27.8
Trapezoid center	Mean	17.7	8.8		9.9	19.1	18.7	27.2
	L 95% CI	16.1	7.4		8.3	15.5	15.5	24.2
	U 95% CI	19.4	10.3		11.5	22.8	21.8	30.2
Conoid center	Mean	10.1		8.8	13.5	26.0	25.5	33.9
	L 95% CI	7.9		7.4	10.7	21.8	22.5	30.8
	U 95% CI	12.3		10.3	16.4	30.2	28.6	37.1
Pec Minor center	Mean	33.4	25.5	18.7	20.3	12.6		11.8
	L 95% CI	30.4	22.5	15.5	17.6	11.3		10.5
	U 95% CI	36.4	28.6	21.8	23.1	13.8		13.0
Conjoint tendon center	Mean	41.6	33.9	27.2	25.2	11.1	11.8	
	L 95% CI	38.7	30.8	24.2	22.5	9.3	10.5	
	U 95% CI	44.6	37.1	30.2	27.8	12.8	13.0	

CAL, coracoacromial ligaments; CI, confidence interval; Pec, pectoralis.

The footprint areas of the anterior CAL and posterior CAL bundles occupied 35.3% [29.2, 41.3] and 23.1% [20.6, 25.6] of the total distance of the lateral coracoid process, respectively (Fig 4).

The coracoid attachment areas for the conoid and trapezoid ligaments were 37 mm<sup>2</sup> [31.8, 42.2] and 44.3 mm<sup>2</sup> [32.7, 55.9], respectively (Table 2).

**Surgically Relevant Distances to Important Landmarks Tendons.** The conjoint tendon of the short head of the biceps and the coracobrachialis attached superolaterally to the apex of the coracoid process at a mean distance of 3 mm [1.9, 4.2], and the pectoralis minor attached 12.1 mm [10.7, 13.5] from the apex of the coracoid. The distance between the centers of the conjoint tendon and the pectoralis minor footprints was 11.8 mm [10.5, 13] (Table 2).

**Ligaments.** The distance between the centers of the anterior and posterior CAL bundle insertions on the coracoid was 15.6 mm [13.2, 18.1]. The anterior and posterior CAL bundles attached 10.6 mm [8.4, 12.9] and 24.8 mm [12.3, 27.4] from the apex of the coracoid process, respectively. The distance from the coracoid apex to the initiation of the anterior and posterior CAL was 4.9 mm [3.0, 6.9] and 20.4 mm [18.4, 22.5], respectively. All other distances are reported and visually shown in Table 2 and Figure 5, respectively.

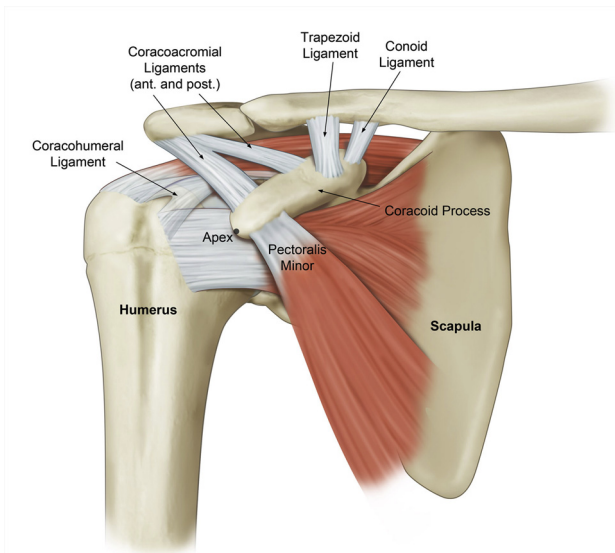
## Quantitative CC Ligaments: Conoid and Trapezoid Ligament Anatomy

### Coracoid Anatomy

The minimum distance between the coracoid apex and the trapezoid ligament was 25.1 mm [22.1, 28.1]. Gender differences were noted, however, such that for male specimens, the mean distance was 28.1 mm [25.1; 31.2] and for female specimens, the mean was 22.0 mm [18.2, 25.9] (Fig 6). The trapezoid ligament and the conoid ligaments were 17.7 mm [16.1, 19.4] and 10.1 mm [7.9, 12.3] from the base of the coracoid, respectively. Furthermore, the trapezoid and conoid ligaments were 18.7 mm [15.5, 21.8] and 25.5 mm [22.1, 28.6] from the center of the pectoralis minor tendon, respectively. The distance between the centers of the footprints of the CC ligaments was 8.8 mm [7.4, 10.3].

### Clavicle Anatomy

The mean distance from the most medial aspect to the most lateral aspect of the clavicle (clavicle length) was 141.3 mm [134.2, 148.4]. The distance between the centers of the trapezoid and conoid ligament attachments was 16.2 mm [14.1, 18.4], and the distance from the most anterior to the most posterior point of the CC ligaments was 19.3 mm [16.1, 22.6]. With regard to medial to lateral extent, the distance between the most medial aspect of the conoid to the most lateral point of the trapezoid was 25.6 mm [22.3, 28.9], which



**Fig 4.** Schematic representation showing the structures attaching to the coracoid on a right shoulder. The anterior coracoacromial ligament bundle (more prominent) and the posterior coracoacromial ligament bundle are shown on the superolateral aspect of the coracoid. The coracohumeral ligament inserts distally close to the posterior coracoacromial ligament. The attachments of the pectoralis minor and the coracoclavicular ligaments are also shown.

accounted for 18.2% [15.8, 20.6] of the total clavicular length. The distance between the point of the most lateral insertion of the CC ligament to the lateral aspect of the clavicle at the AC joint was 15.7 mm [13.1, 18.3] (Fig 7).

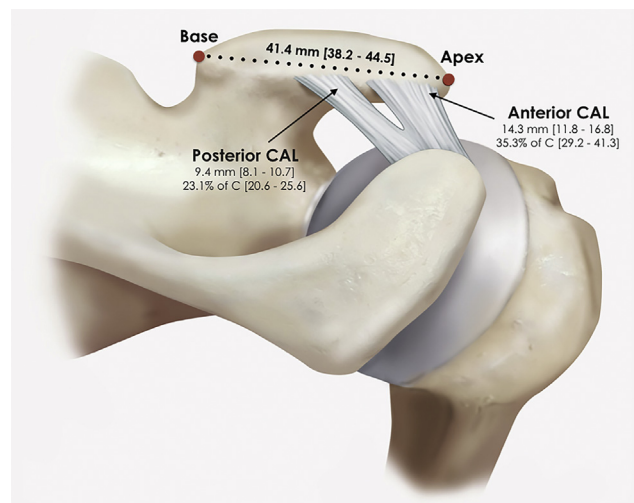
#### CAL Attachment on Acromion

The mean area of the CAL acromial attachment was 77 mm<sup>2</sup> (95% CI [51.9, 102.2]). The acromial attachment of the CAL was 8.9 mm (95% CI [6.4, 11.4]) inferior and lateral to the anterior acromial point and 9.9 mm (95% CI [6.1, 13.7]) inferomedial to the anterolateral acromial point (Fig 8).

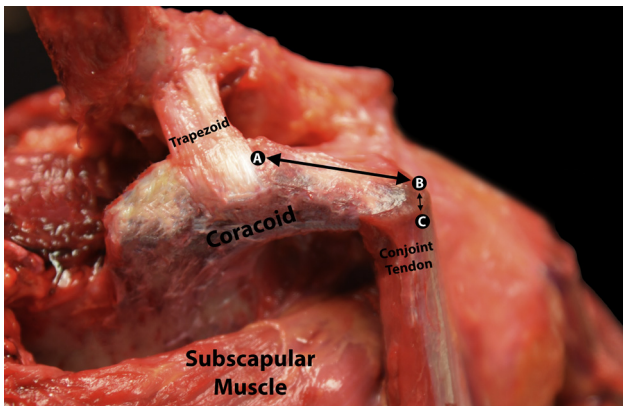
#### Discussion

The main findings of this study were that a consistent 3-dimensional relation of the ligamentous and tendinous structures attaching to the coracoid process was identified, and the precision by which this relation was identified provides a useful framework to guide surgical procedures involving the coracoid process. Importantly, 2 distinct attachments of the CAL, the anterior (more prominent) and posterior bundles, were found consistently on the superolateral aspect of the coracoid process. The CC ligaments, specifically the most distal attachment of the trapezoid ligament, attached at a mean distance of 28.1 mm [25.1, 31.2] and 22.0 mm [18.2, 25.9] from the apex of the coracoid for male and female specimens, respectively.

Contrary to previous studies,<sup>2</sup> our study quantifies the areas of the ligamentous and tendinous attachments and describes their locations with respect to each other and to bony landmarks of the coracoid such as the apex and base of the coracoid process. These findings are surgically relevant in numerous contexts including CC reconstruction, distal clavicle resection, and Latarjet among others. In the current study, the most lateral aspect of the CC ligaments was found to be located at an average of 15.7 mm from the lateral aspect of the clavicle at the AC joint. The CC ligaments were noted to span an average length of 25.6 mm on the clavicle. Based on these findings, surgical reconstruction of the CC ligaments with a single cortical fixation device should use a clavicle tunnel placed midway between the span of the CC ligaments, at a distance of 28.5 mm from the lateral aspect of the clavicle at the AC joint, which is 16.5 mm lateral to what was previously reported.<sup>30</sup> The importance of this distinction is highlighted by a recent study by Eisenstein et al.<sup>31</sup> that reported that medialization of the tunnel resulted in the increased risk of failure. Although the broad attachment of the CC ligaments may not be replicated by using single cortical fixation devices, the risk of clavicle fracture increases with larger or multiple tunnels. In a controlled laboratory study, Rios et al.<sup>4</sup> found similar consistency in the anatomy of the CC ligaments to the results presented here and reported that the constant ratio of the sites of the conoid and trapezoid ligaments with respect to the total length of the clavicle could aid surgeons in placing tunnels for anatomic CC reconstruction intraoperatively.<sup>4</sup> With regard to distal clavicle



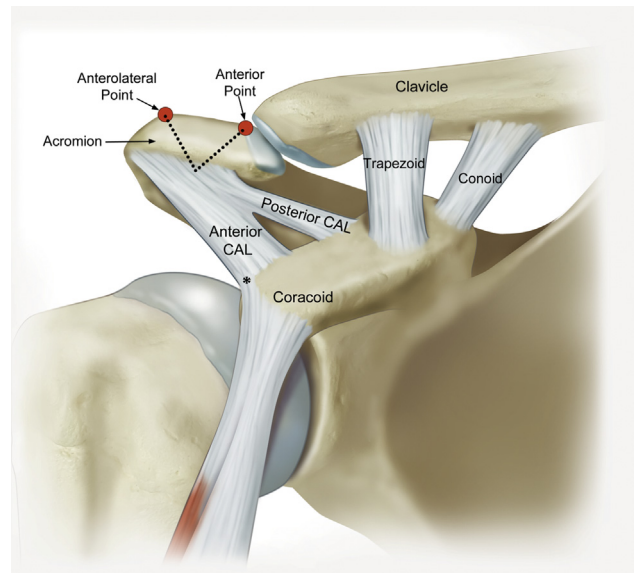
**Fig 5.** Schematic diagram of a right shoulder showing the anterior coracoacromial ligament (CAL) bundle and the posterior coracoacromial ligament bundle with their mean attachment lengths and confidence intervals and the percentage of the lateral coracoid (% of C) that each structure occupies with confidence intervals.



**Fig 6.** Dissected cadaveric right shoulder showing the coracoid (as viewed from medial) and clavicular attachment of the trapezoid (T). The distances measured from the most distal attachment of the trapezoid (A) to the superior tip of the coracoid process (B) and the tip of the coracoid (C).

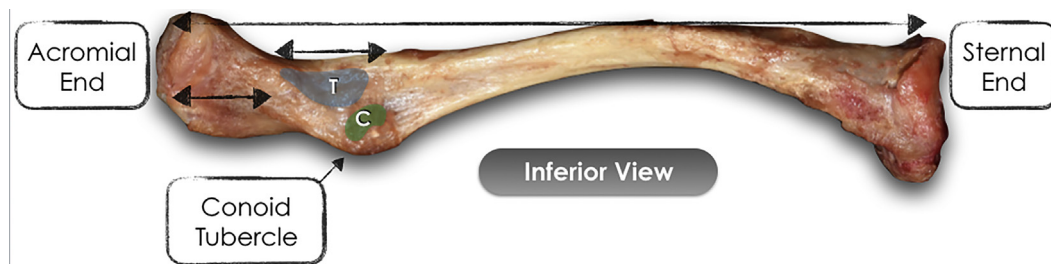resection, the shortest distance from the lateral clavicle to the CC ligaments in this study was 13.1 mm. Therefore, lateral clavicular resection for AC joint pathology or lateral clavicular osteotomy for bone graft harvest should not exceed 13 mm. The AC ligaments that provide horizontal stability may be weakened by wide distal clavicle resections.

The present cadaveric study provides detailed information regarding the coracoid and acromial insertion of the CAL that may be useful to surgeons during both arthroscopic and open shoulder surgery.<sup>1</sup> The distance from the coracoid tip (apex) to the anterior and posterior CAL attachments was found to be 10.7 and 24.8 mm, respectively. Dolan et al.<sup>22</sup> similarly reported that the distance from the coracoid tip to the anterior and posterior CAL attachments was a mean 7.8 and 25.7 mm. These findings are important in the context of the Latarjet procedure as the posterior attachment of the CAL may be spared during harvesting of the coracoid process. Preserving the posterior CAL may help maintain the coracoacromial arch. In addition, our findings regarding differences in gender in the minimum distance between the coracoid apex and the trapezoid ligament are important for planning the



**Fig 8.** Schematic representation of the coracoacromial ligament (CAL) attachment on the inferior surface of the anterior aspect of the acromion of a right shoulder. The most reliable bony landmarks are depicted: the anterior and anterolateral points of the acromion with their respective distances measured to the center of the insertion of the CAL on the acromion, indicated by the dashed lines. \*The conjoint tendon had a linear insertion on the distal and anterior aspect of the anterior CAL bundle that measured 7.1 mm [5.4, 8.8].

coracoid osteotomy. With respect to the acromial attachment of the CAL, few authors have quantitatively evaluated this attachment site. Gallino et al.<sup>5</sup> performed a cadaveric study to characterize the overall shape and character of the CAL. Although they noted that traditionally the ligament was thought to represent a triangular structure from the apex of the acromion to the lateral coracoid, they found a stout, trapezoidal structure with a wide insertion on the inferior aspect of the acromion displaying variable thickness. Because of the stout nature of the CAL, they postulated that it might counteract the surrounding muscle acting on the coracoid process as a “robust suspension.”<sup>5</sup> A similarly broad attachment of the CAL on the acromion was found in this study that suggests that release of the



**Fig 7.** Inferior view of a cadaveric left clavicle showing the attachment shapes of the trapezoid (T) and conoid (C) ligaments. The mean clavicle length was 14.1 cm [13.4, 14.8], and the mean distance between the most lateral insertions of the coracoclavicular ligaments from the lateral aspect of the clavicle at the AC joint was 15.7 mm.

entire CAL from the acromion may not be necessary during an arthroscopic lateral acromioplasty. Lastly, during a Latarjet procedure, the CAL is transected approximately 1 cm from its insertion on the coracoid process, leaving a cuff of soft tissue (CAL) on the coracoid for later incorporation into the capsular repair (which also allows for the preservation the linear insertion of the conjoint tendon on the distal and anterior aspect of the anterior CAL bundle).

### Limitations

The present study has some limitations inherent to a cadaveric study design. Although a detailed dissection was performed to clearly visualize the anatomic attachments and fiber orientations, distances were calculated as absolute 3-dimensional vector norms, which do not provide directional information. In addition, removal of the clavicle during data collection was necessary to obtain accurate measurements of the CC ligament attachments, because the coracoid process impedes the access of the measuring tip with the clavicle in anatomic position. Also, the relatively limited number of specimens may have led to underpowered results for the general population; however, the consistency and low standard deviations in this study strengthen the discovered results in this respect.

### Conclusions

In contrast to previous findings, 2 different coracoid attachments (anterior and posterior bundles) of the CAL were consistently noted in all specimens. Moreover, a coracoid osteotomy for a bone graft for the Latarjet procedure should be performed at less than 28.1/22 mm from the apex of the coracoid in male/female patients, respectively. Lastly, the CC ligaments' attachments on the clavicle accounted for 18.2% of the clavicle length and were located 15.7 mm from the lateral aspect of the AC joint, which should be considered for a single tunnel reconstruction.

### References

- Williams A, Calvert P, Bayley I. The bifurcate coracoacromial ligament: An arthroscopic variant. *Arthroscopy* 1997;13:233-234.
- Salzmann GM, Paul J, Sandmann GH, Imhoff AB, Schottle PB. The coracoid insertion of the coracoclavicular ligaments: An anatomic study. *Am J Sports Med* 2008;36:2392-2397.
- Takase K. The coracoclavicular ligaments: An anatomic study. *Surg Radiol Anat* 2010;32:683-688.
- Rios CG, Arciero RA, Mazzocca AD. Anatomy of the clavicle and coracoid process for reconstruction of the coracoclavicular ligaments. *Am J Sports Med* 2007;35:811-817.
- Gallino M, Battiston B, Annaratone G, Terragnoli F. Coracoacromial ligament: A comparative arthroscopic and anatomic study. *Arthroscopy* 1995;11:564-567.
- Gray H, Standring S, Ellis H, Berkovitz BKB. *Gray's anatomy: The anatomical basis of clinical practice*. Edinburgh and New York: Elsevier Churchill Livingstone, 2005.
- Johnson L. *Arthroscopic surgery: Principles and practice*. St. Louis: Mosby, 1986.
- Edelson JG, Luchs J. Aspects of coracoacromial ligament anatomy of interest to the arthroscopic surgeon. *Arthroscopy* 1995;11:715-719.
- Arrigoni P, Randelli P, Filiputti M, Cabitza P, Vaienti L. The CARE technique: Arthroscopic CoracoAcromial ligament RE-attachment. *Musculoskelet Surg* 2010;94:S65-S69 (suppl 1).
- Hu X, Huang F, Zhong G, Cen S, Xiang Z, Li J. [Biomechanical study on proximally based conjoint tendon transfer for coracoacromial ligament reconstruction as anterosuperior restraint of shoulder]. *Zhongguo Xiu Fu Chong Jian Wai Ke Za Zhi* 2009;23:1469-1473 [in Chinese].
- Gartsman GM, Waggenspack WN Jr, O'Connor DP, Elkousy HA, Edwards TB. Immediate and early complications of the open Latarjet procedure: A retrospective review of a large consecutive case series. *J Shoulder Elbow Surg* 2017;26:68-72.
- LaPrade RF, Hilger B. Coracoclavicular ligament reconstruction using a semitendinosus graft for failed acromioclavicular separation surgery. *Arthroscopy* 2005;21:1277.
- Latarjet M. [Treatment of recurrent dislocation of the shoulder]. *Lyon Chir* 1954;49:994-997.
- Mook WR, Petri M, Greenspoon JA, Horan MP, Dornan GJ, Millett PJ. Clinical and anatomic predictors of outcomes after the Latarjet procedure for the treatment of anterior glenohumeral instability with combined glenoid and humeral bone defects. *Am J Sports Med* 2016;44:1407-1416.
- Zhu NF, Rui BY, Zhang YL, Chen YF. Anatomic study of coracoclavicular ligaments for reconstruction of acromioclavicular joint dislocations. *J Orthop Sci* 2016;21:749-752.
- Salzmann GM, Walz L, Buchmann S, Glabgly P, Venjakob A, Imhoff AB. Arthroscopically assisted 2-bundle anatomical reduction of acute acromioclavicular joint separations. *Am J Sports Med* 2010;38:1179-1187.
- Venjakob AJ, Salzmann GM, Gabel F, et al. Arthroscopically assisted 2-bundle anatomic reduction of acute acromioclavicular joint separations: 58-month findings. *Am J Sports Med* 2013;41:615-621.
- Nourissat G, Neyton L, Metais P, et al. Functional outcomes after open versus arthroscopic Latarjet procedure: A prospective comparative study. *Orthop Traumatol Surg Res* 2016;102:S277-S279.
- Hardy A, Loriaut P, Granger B, et al. Reliability of a CT reconstruction for preoperative surgical planning in the arthroscopic Latarjet procedure. *Knee Surg Sports Traumatol Arthrosc*. October 12, 2016. [Epub ahead of print.]
- Haeni DL, Opsomer G, Sood A, et al. Three-dimensional volume measurement of coracoid graft osteolysis after arthroscopic Latarjet procedure. *J Shoulder Elbow Surg* 2017;26:484-489.
- Marion B, Klouche S, Deranlot J, Bauer T, Nourissat G, Hardy P. A prospective comparative study of arthroscopic versus mini-open Latarjet procedure with a minimum 2-year follow-up. *Arthroscopy* 2017;33:269-277.



22. Dolan CM, Hariri S, Hart ND, McAdams TR. An anatomic study of the coracoid process as it relates to bone transfer procedures. *J Shoulder Elbow Surg* 2011;20:497-501.
23. Terra BB, Ejnisman B, de Figueiredo EA, et al. Anatomic study of the coracoid process: Safety margin and practical implications. *Arthroscopy* 2013;29:25-30.
24. Godin J, Chahla J, Moatshe G, et al. A comprehensive re-analysis of the distal iliotibial band: Quantitative anatomy, radiographic markers, and biomechanical properties. *Am J Sports Med*. [Epub ahead of print.]
25. Kennedy MI, Claes S, Fuso FA, et al. The anterolateral ligament: An anatomic, radiographic, and biomechanical analysis. *Am J Sports Med* 2015;43:1606-1615.
26. LaPrade CM, Ellman MB, Rasmussen MT, et al. Anatomy of the anterior root attachments of the medial and lateral menisci: A quantitative analysis. *Am J Sports Med* 2014;42:2386-2392.
27. Philippon MJ, Michalski MP, Campbell KJ, et al. An anatomical study of the acetabulum with clinical applications to hip arthroscopy. *J Bone Joint Surg Am* 2014;96:1673-1682.
28. LaPrade RF. *Posterolateral knee injuries: Anatomy, evaluation, and treatment*. New York/Stuttgart: Thieme, 2011.
29. LaPrade RF, Engebretsen AH, Ly TV, Johansen S, Wentorf FA, Engebretsen L. The anatomy of the medial part of the knee. *J Bone Joint Surg Am* 2007;89:2000-2010.
30. Carofino BC, Mazzocca AD. The anatomic coracoclavicular ligament reconstruction: Surgical technique and indications. *J Shoulder Elbow Surg* 2010;19:37-46.
31. Eisenstein ED, Lanzi JT, Waterman BR, Bader JM, Pallis MP. Medialized clavicular bone tunnel position predicts failure after anatomic coracoclavicular ligament reconstruction in young, active male patients. *Am J Sports Med* 2016;44:2682-2689.