

# Viability and Tissue Quality of Cartilage Flaps From Patients With Femoroacetabular Hip Impingement

## A Matched-Control Comparison

Francisco Rodriguez-Fontan,\* MD, Karin A. Payne,\* PhD, Jorge Chahla,<sup>†</sup> MD, Omer Mei-Dan,<sup>‡</sup> MD, Abigail Richards,\* Soshi Uchida,<sup>§</sup> MD, PhD, and Cecilia Pascual-Garrido,<sup>||¶</sup> MD

*Investigation performed at the Department of Orthopedics, University of Colorado Anschutz Medical Campus, Aurora, Colorado, USA*

**Background:** Chondrolabral damage is commonly observed in patients with cam-type femoroacetabular impingement (FAI). Chondral flap reattachment has recently been proposed as a possible preservation technique.

**Purpose/Hypothesis:** The purpose of this study was to determine the viability and tissue quality of chondral flaps from patients with FAI at the time of arthroscopy. It was hypothesized that chondral flaps from patients with cam lesions of the hip would exhibit less viability and greater tissue degeneration than would those of a matched control group.

**Study Design:** Cohort study; Level of evidence, 2.

**Methods:** Patients with cam-type FAI who were treated with hip arthroscopy between 2014 and 2016 were asked to participate in this study. The cartilage lesions were localized and classified intraoperatively according to Beck classification. A chondral flap (study group) and a cartilage sample (control group) were obtained from each patient for histologic evaluation. Cellular viability and tissue quality were examined and compared in both groups. Cellular viability was determined with live/dead staining, and tissue quality was evaluated using safranin O/fast green, hematoxylin and eosin (H&E) staining, and immunohistochemistry for collagen II. Osteoarthritis Research Society International (OARSI) grading was used for quality assessment, and Image J software was used to calculate the percentage of tissue viability and Col II stain.

**Results:** A total of 10 male patients with a mean age of 38.4 years (range, 30-55 years) were enrolled. All chondral flaps were classified as Beck grade 4. The mean cellular viability of the chondral flaps was reduced ( $54.6\% \pm 25.6\%$ ), and they were found to be degenerated (OARSI grade,  $4 \pm 1.27$ ). Control samples also had reduced viability ( $38.8\% \pm 30.3\%$ ) and were degenerative (OARSI grade,  $3.5 \pm 1.38$ ). There was no statistically significant intergroup difference for viability ( $P = .203$ ) or OARSI grade ( $P = .645$ ), nor was there an intragroup correlation between viability and OARSI grade ( $P > .05$ ). A significant negative correlation ( $r = -0.9$ ,  $P = .035$ ) was found between OARSI grade and collagen II percentage scale in 5 selected samples.

**Conclusion:** Despite appearing normal macroscopically, the chondral flaps from patients with cam-type FAI displayed loss of viability and tissue degeneration. In addition, control samples obtained away from the injury area also displayed cartilage damage and degeneration. Careful consideration should be taken when attempting to reattach the chondral flap.

**Keywords:** femoroacetabular impingement; flap; viability; degeneration; reattachment

Femoroacetabular impingement (FAI) syndrome is a frequent cause of chondrolabral tears and hip pain.<sup>20,21</sup> Different types of FAI have been described, including cam, pincer, and combined morphology. FAI has been associated with early progression to osteoarthritis (OA) secondary to

the chronic impingement to the articular cartilage.<sup>12</sup> Male patients usually present with larger morphological lesions, known as *pistol grip deformity*.<sup>12,62</sup> In addition, male patients frequently present with advanced cartilage lesions and larger labral tears compared with those of female patients (56% for males and 24% for females).<sup>38</sup>

In a retrospective study including 355 hips undergoing arthroscopic treatment of FAI, Nepple et al<sup>36</sup> reported on findings and predictors of intra-articular hip disease.

The Orthopaedic Journal of Sports Medicine, 5(8), 2325967117723608  
DOI: 10.1177/2325967117723608  
© The Author(s) 2017

This open-access article is published and distributed under the Creative Commons Attribution - NonCommercial - No Derivatives License (<http://creativecommons.org/licenses/by-nc-nd/3.0/>), which permits the noncommercial use, distribution, and reproduction of the article in any medium, provided the original author and source are credited. You may not alter, transform, or build upon this article without the permission of the Author(s). For reprints and permission queries, please visit SAGE's website at <http://www.sagepub.com/journalsPermissions.nav>.

Labral tears and acetabular cartilage lesions were present in 90.1% and 67.3% of the cases, respectively. In addition, male sex, age >30 years, Tönnis OA grade 1 or 2,<sup>56</sup> lateral center-edge angle (LCEA) <20°, and cam FAI (alpha angle >50°)<sup>2,18,40</sup> had a strong correlation with moderate to severe intra-articular disease and larger labral tears.<sup>36</sup> The current standard of care for patients with symptomatic cam-type hip FAI lesion who have failed nonoperative treatment is hip arthroscopy or open surgical dislocation with labrum repair, osteochondroplasty, and removal of chondral flaps (when present), followed by microfracture or microdrilling.<sup>1,14,53</sup> Short-term results seem encouraging with microfracture, but there is uncertainty on how these lesions may alter the natural evolution of joint degeneration and the potential effect on long-term hip preservation.<sup>11,22,26,44</sup> Advanced regenerative therapies have been proposed as an alternative therapy for the treatment of these lesions.<sup>42</sup>

Recently, in an attempt to preserve the chondral flap tissue, different techniques have been described, such as bridging suture repair,<sup>23</sup> direct suture technique,<sup>51</sup> and fibrin adhesive.<sup>52,59</sup> These techniques propose refixing the delamination or chondral flap to its native location. However, cartilage healing depends on multiple variables, including adequate fixation technique, healthy cartilage, and an intrinsic repair capacity. Thus, before attempting any preservation chondral flap technique, it is critical to assess tissue quality and viability.

For the above-mentioned reasons, the purpose of this study was to determine the viability and tissue quality of chondral flaps from patients with FAI at the time of arthroscopy. It was hypothesized that chondral flaps within the hip joint would exhibit less viability and higher tissue degeneration than those from a matched control group.

## METHODS

### Study Design and Population

Between 2014 and 2016, patients undergoing hip arthroscopic treatment for symptomatic cam-type FAI lesions were asked to participate in this study prospectively. All patients gave informed consent, and the study was approved by an institutional review board (protocol No. 13-2128). The inclusion criteria included symptomatic hip patients secondary to cam-type FAI lesions who underwent hip arthroscopy and who presented with a cartilage flap

that was confirmed intraoperatively.<sup>4,37</sup> Exclusion criteria included absence of cartilage damage or chondral flap, revision surgery or pincer morphology, rheumatologic conditions, and advanced, diffuse degenerative changes (joint space <2 mm).

Imaging techniques used were anteroposterior radiographs, Dunn view, false-profile view, and computed tomography scan. Four radiological parameters were recorded for each patient: alpha angle,<sup>40,48</sup> femoral version,<sup>55,57</sup> LCEA,<sup>34</sup> and femoral neck version.<sup>3</sup>

### Macroscopy

**Arthroscopy.** Under arthroscopic view of the hip, lesions for all patients were documented using a clock system with reliable landmarks as follows: 12-o'clock superior (stellate crease) and 3-o'clock anterior at the psoas U (Figure 1).<sup>43</sup> The lesions were classified according to the Beck classification (Table 1).<sup>4</sup>

**Sample Extraction.** During surgery, a biter was used for removal of encountered chondral flaps (study group) and for obtaining a cartilage sample from the perifoveal area (control group), a nonweightbearing area. Therefore, each patient had a matched control (Figures 1 and 2). These were immediately transferred to the laboratory in low-glucose Dulbecco's Modified Eagle Medium containing 1% penicillin-streptomycin for immediate tissue analysis for viability and quality.

## HISTOLOGY

### Viability

**Live/Dead Staining.** Calcein acetoxymethyl and ethidium homodimer-1 were used to assess viability of the samples.<sup>41</sup> The samples were analyzed in a dark room under a Nikon C2 confocal microscope. Images were taken from each sample at 10× magnification and 1024 × 1024 pixels, with the microscope imaging software NIS-Elements AR 4.20.01 (Nikon). Viability percentage of all samples was assessed with Image J software (Developer Wayne Rasband at National Institutes of Health).

### Tissue Quality

**Safranin O/Fast Green and Hematoxylin and Eosin.** All samples were fixed in 10% formalin after live/dead tissue

\*Address correspondence to Cecilia Pascual-Garrido, MD, Adult Reconstruction, Adolescent and Young Adult Hip Service, Washington University Orthopedics, 660 S Euclid, Campus Box 8233, St Louis, MO 63110, USA (email: pascualgarridoc@wudosis.wustl.edu).

†Regenerative Orthopedics Laboratory, Department of Orthopedics, University of Colorado Anschutz Medical Campus, Aurora, Colorado, USA.

‡Steadman Philippon Research Institute, Vail, Colorado, USA.

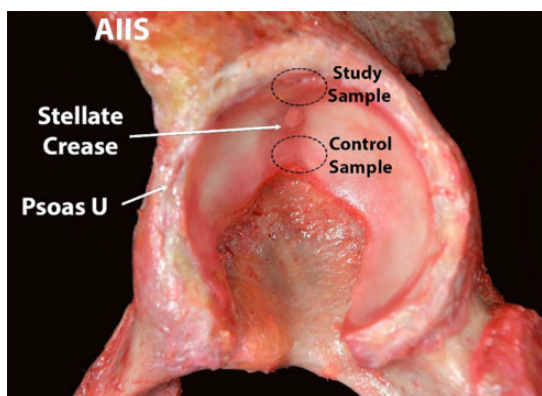
§Sports Medicine, Hip Preservation, Department of Orthopedics, University of Colorado Anschutz Medical Campus, Aurora, Colorado, USA.

¶Department of Orthopaedic Surgery, Wakamatsu Hospital for the University of Occupational and Environmental Health, Kitakyushu, Japan.

||Adult Reconstruction, Adolescent and Young Adult Hip Service, Orthopaedics Department, Washington University, St Louis, Missouri, USA.

One or more of the authors has declared the following potential conflict of interest or source of funding: C.P.-G. receives research support from Biomet-Zimmer and AOSSM-SANOFI. S.U. is a consultant for Smith & Nephew and Zimmer-Biomet and receives research fund from Smith & Nephew and Stryker. The authors acknowledge funding support from the Academic Enrichment Fund of the University of Colorado Anschutz Medical Campus and the Gates Center for Regenerative Medicine. The C1C1 hybridoma developed by Rikard Holmdahl and Kristofer Rubin was obtained from the Developmental Studies Hybridoma Bank, created by NICHD of the NIH and maintained at the University of Iowa, Department of Biology, Iowa City, IA 52242, USA.

Ethical approval for this study was obtained from the University of Colorado Anschutz Medical Campus (protocol No. 13-2128).



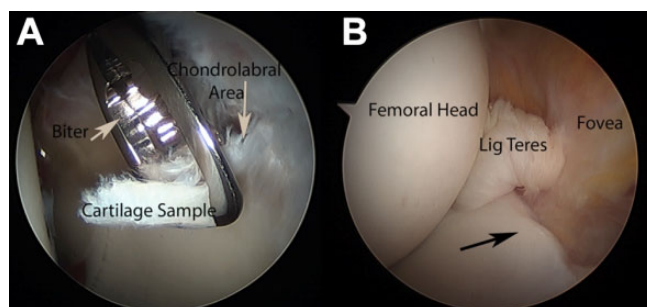
**Figure 1.** Left acetabulum from a cadaver showing locations of study and control samples. AIIS, anterior inferior iliac spine.

**TABLE 1**  
Beck Classification of Cartilage Damage

Stage: Description	Criteria
0: Normal	Macroscopically sound cartilage
1: Malacia	Roughening of surface, fibrillation
2: Pitting	Roughening, partially thinning, and full-thickness defects or deep fissuring to the bone
3: Debonding	Loss of fixation to the subchondral bone; macroscopically sound cartilage; carpet phenomenon
4: Cleavage	Loss of fixation to the subchondral bone; frayed edges; thinning of the cartilage
5: Defect	Full-thickness defect

evaluation. At 24 hours, the samples were dehydrated by a scheduled process of increasing concentrations of ethanol and finally embedded in paraffin blocks. These were sectioned at 5  $\mu$ m and mounted onto slides. Subsequent histological staining was made with safranin O/fast green and hematoxylin and eosin (H&E)<sup>41</sup> for tissue quality analysis. Samples were visualized and images taken at 4 $\times$  and 20 $\times$  magnification under light microscopy with an EVOS *xl* core microscope (AMG). Histological grading was performed using the Osteoarthritis Research Society International (OARSI) grading system. The OARSI assesses depth severity, with grades ranging from 0 (intact cartilage) to 6 (deformation) (Table 2).<sup>47</sup>

**Immunohistochemistry for Collagen II.** For immunohistochemistry, consecutive sections from single samples previously OARSI graded were selected for staining. These were deparaffinized and incubated with primary anti-Collagen II (Col II) antibody 1:100 (Iowa hybridoma bank; catalog No. CIIC1) in 10% goat serum in triphosphate buffer saline overnight at 4°C. Negative controls were prepared by omitting the primary antibody.<sup>33</sup> Immunopositive sections were visualized and images taken at 4 $\times$  and 20 $\times$  magnification using the EVOS *xl* core light microscope.



**Figure 2.** Left hip arthroscopic view from the anterolateral portal. (A) Chondral flap removal with a biter. (B) Control sampling site (arrow) at the perifoveal area.

Percentage of Col II stain was estimated with Image J and graded 0 to 4 depending on the obtained percentage (0 = not stained; 1 = <25%; 2 = 25%-50%; 3 = 50%-75%; 4 = >75%).<sup>27</sup> A comparison of images at 20 $\times$  magnification was done using sections graded from 1 through 5 using the OARSI scale.

### Statistical Analysis

Statistical analysis was performed using Sigma Plot 11.0 (Systat Software Inc). Comparisons between the study and control groups for cellular viability and OARSI grading were done using a paired *t* test. In addition, a Pearson correlation coefficient (*R*) was computed between viability with OARSI grading and OARSI-graded sections 1 through 5 with Col II. Data are reported as mean  $\pm$  SD, and *P* < .05 was considered significant.

### RESULTS

A total of 10 male patients with cam-type FAI lesions and an average age of 38.4 years (range, 30-55 years) were included in this study. All patients underwent labrum repair arthroscopically, chondral flap removal, microdrilling, osteochondroplasty, and capsular repair. One patient had a previous periacetabular osteotomy. Another patient had concomitant hip borderline dysplasia (Table 3).

All chondral flaps appeared macroscopically normal and were classified as grade 4 of the Beck classification (loss of fixation to the subchondral bone, frayed edges, thinning of the cartilage). Most cartilage lesions were localized at the 12- to 2-o'clock area (Table 3). Both study and control samples weighed between 100 and 500 mg. No complications were encountered during surgery or during tissue extraction.

The study group displayed some level of cellular viability, with a mean value of 54.6%  $\pm$  25.6% (range, 3.8%-85.1%). In terms of architecture and tissue quality, the chondral flaps showed evidence of microscopic signs of degeneration, with an OARSI grading of 4  $\pm$  1.27. The control group also had reduced viability, with a mean value of 38.8%  $\pm$  30.3% (range, 0%-94%) and displayed signs of degeneration, with an OARSI grading of 3.5  $\pm$  1.38 (Table 4, Figures 3 and 4).<sup>31,49</sup>

TABLE 2  
OARSI Grading System

Grade	Subgrade (Optional)	Associated Criteria (Tissue Reaction)
0: Surface intact, cartilage intact	None	Intact, uninvolved cartilage
1: Surface intact	1.0 Cells intact 1.5 Cell death	Matrix: superficial zone intact, edema and/or fibrillation Cells: Proliferation (clusters), hypertrophy Reaction must be more than fibrillation only
2: Surface discontinuity	2.0 Fibrillation through superficial zone 2.5 Surface abrasion with matrix loss within superficial zone	Features for grade 1: +discontinuity at superficial zone, ± safranin O or toluidine blue depletion on upper one-third of cartilage (midzone), ± chondron columns disorientation
3: Vertical fissures	3.0 Simple fissures 3.5 Branched/complex fissures	Features for grade 2: ± safranin O or toluidine blue depletion on upper two-thirds of cartilage (deep zone), ± neocartilage formation (polarized light microscopy, picrosirius red stain)
4: Erosion	4.0 Superficial zone delamination 4.5 Midzone excavation	Cartilage matrix loss, cyst formation within matrix
5: Denudation	5.0 Bone surface intact 5.5 Reparative tissue surface present	Surface is sclerotic bone or reparative tissue including fibrocartilage
6: Deformation	6.0 Joint margin osteophytes 6.5 Joint margin and central osteophytes	Bone remodeling; deformation of articular surface contour (more than osteophyte formation only); includes microfracture and repair

TABLE 3  
Characteristics of Patients Enrolled<sup>a</sup>

Patient No.	Sex	Age, y	Hip	Diagnosis	LCEA, deg	Alpha angle, deg	Beck Classification	Cartilage Lesion Location	Femoral Version	Femoral Neck Version
1	M	38	L	FAI-cam	44	68	4	12-2 o' clock	1	10
2	M	30	L	FAI-cam	28	69	4	12-2 o' clock	18	24
3	M	33	L	FAI-cam	35	78	4	12-3 o' clock	4	10
4	M	39	R	FAI-cam	29	63	4	12-3 o' clock	4	10
5	M	39	L	FAI-cam	28	56	4	12-2 o' clock	10	11
6	M	55	L	FAI-cam	30	49	4	12-1 o' clock	-3	-1
7	M	32	R	FAI-cam/previous PAO	20	53	4	12-2 o' clock	23	17
8	M	31	L	FAI-cam/borderline dysplasia	15	53	4	1-2 o' clock	21	17
9	M	43	R	FAI-cam	32	54	4	12-2 o' clock	21	4
10	M	44	R	FAI-cam	33	60	4	12-2 o' clock	20	7

<sup>a</sup>FAI, femoroacetabular impingement; L, left; LCEA, lateral center-edge angle; M, male; PAO, periacetabular osteotomy; R, right.

Randomly selected single consecutive sections from 5 patients, previously OARSI graded 1 to 5 (to represent each grade), showed loss of Col II staining as OARSI grades increased. The percentage of Col II expression in these 5 patients resulted in score 4 (82%) for patient 1 (control group), OARSI grade 1; score 4 (76%) for patient 3 (study group), OARSI grade 2; score 3 (66%) for patient 7 (study group), OARSI grade 3; score 3 (59%) for patient 8 (control group), OARSI grade 4; and score 1 (21%) for patient 10 (study group), OARSI grade 5 (Figure 5).<sup>27</sup>

The overall main histological findings for both groups were a reduction in the percentage viability and a loss of healthy cartilage architecture. Most had loss of chondrocyte columnar orientation, loss of surface integrity, cluster and cyst formation, loss of extracellular matrix (ECM),

cellular hypertrophy, loss of Col II in high OARSI grades, and fibrocartilage (Figures 4, 5, and 6).

### Statistical Analysis

No intergroup statistical difference was evident for cellular viability ( $n = 10$ ,  $P = .203$ ) or OARSI grading ( $n = 9$ ,  $P = .645$ ). In addition, no statistically significant correlation was found between cellular viability and OARSI grading for the study and control group ( $r = 0.056$ ,  $n = 10$ ,  $P = .877$  and  $r = -0.513$ ,  $n = 9$ ,  $P = .157$ , respectively) (Figure 7). Regarding Col II content, a significant negative correlation was found between OARSI grading and Col II content in the 5 selected sections ( $r = -0.9$ ,  $n = 5$ ,  $P = .035$ ) (Figure 8).

TABLE 4  
Cellular Viability Percentage and  
OARSI Grading for Both Groups<sup>a</sup>

Patient	Viability		OARSI Grading	
	Study Group	Control Group	Study Group	Control Group
1	48.6 <sup>b</sup>	94	5	1
2	50.5	32 <sup>c</sup>	3.5	5
3	62.7	64.6	2	4.5
4	20.8 <sup>b</sup>	0 <sup>c</sup>	5	5
5	69.6	55	4.5	2.5
6	74.6	14.1 <sup>c</sup>	2	2.5
7	3.8 <sup>b</sup>	30 <sup>c</sup>	3	4.5
8	53.6	23.2 <sup>c</sup>	5	4
9	85.1	7.7 <sup>c</sup>	5	3
10	77.3	68.1	5	Not performed
Mean	54.6	38.8	4	3.5
SD	25.6	30.3	1.27	1.38

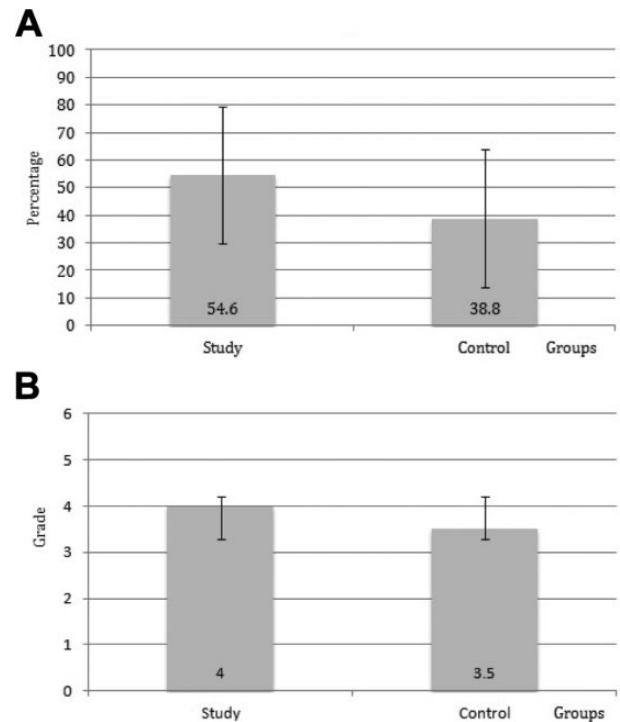
<sup>a</sup>The control sample from patient 10 was not studied for OARSI grading. OARSI, Osteoarthritis Research Society International.

<sup>b</sup>Flaps with viability below 50%.

<sup>c</sup>Controls with viability below 50%.

## DISCUSSION

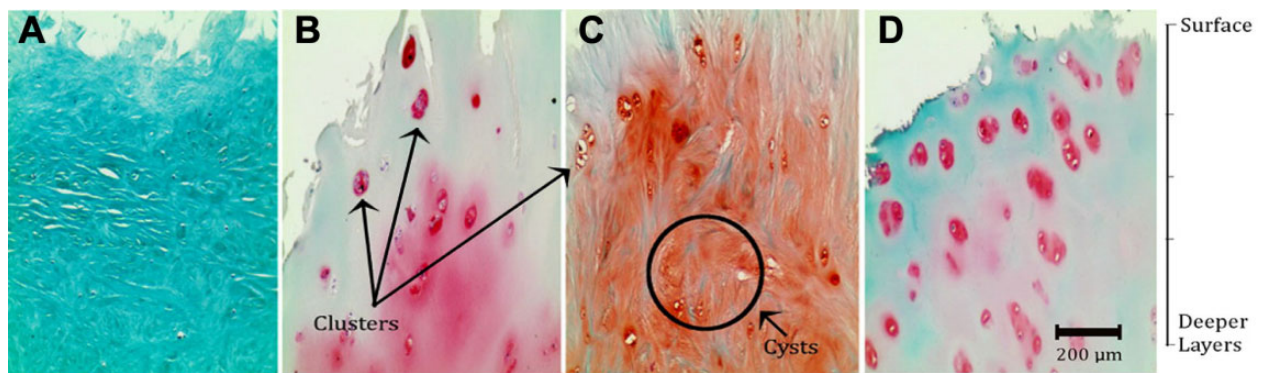
The most important finding from this study was that chondral flaps from patients with cam-type hip FAI had reduced cellular viability and degenerative changes. All chondral flap samples showed degeneration, including fibrosis, cyst formation, clusters, cell death, hypertrophy, loss of Col II, loss of architecture, and loss of surface integrity. Interestingly, matched control samples also had poor cellular viability and, in most cases, presented similar degenerating features—resulting in no histological difference between groups. Arthroscopically, the acetabular cartilage surface may appear normal or healthy, but histologically, it proves that the articular cartilage is under degeneration. This suggests that patients with cam-type FAI lesions may potentially suffer from a chronic joint degeneration-inflammation process, where both the chondral flap and surrounding tissues are affected, strengthening the concept of FAI as a pre-osteoarthritic joint disease.<sup>49</sup> However, there might be different anatomic areas of stress intensity within the acetabulum that probably lead to different patterns of articular cartilage wear and inflammation within the joint.<sup>24</sup> Since the perifovea area is normally affected in most FAI hips with some inflammation and chondromalacia, we believe that if the control samples would have been taken from altered locations, findings may have been different. Chondral flaps were observed to be in a degenerative state, suggesting that their refixation as a cartilage restoration technique should be carefully considered or perhaps should not be attempted. Refixation provides a native scaffold for cartilage healing, whereas excision and microfracture provide a clot formation hosting stem cells and growth factors for new cartilage formation.<sup>29</sup> Both treatment options provide pain relief and function recovery.<sup>11,26,29,52,59</sup> Although post-refixation tissue quality has



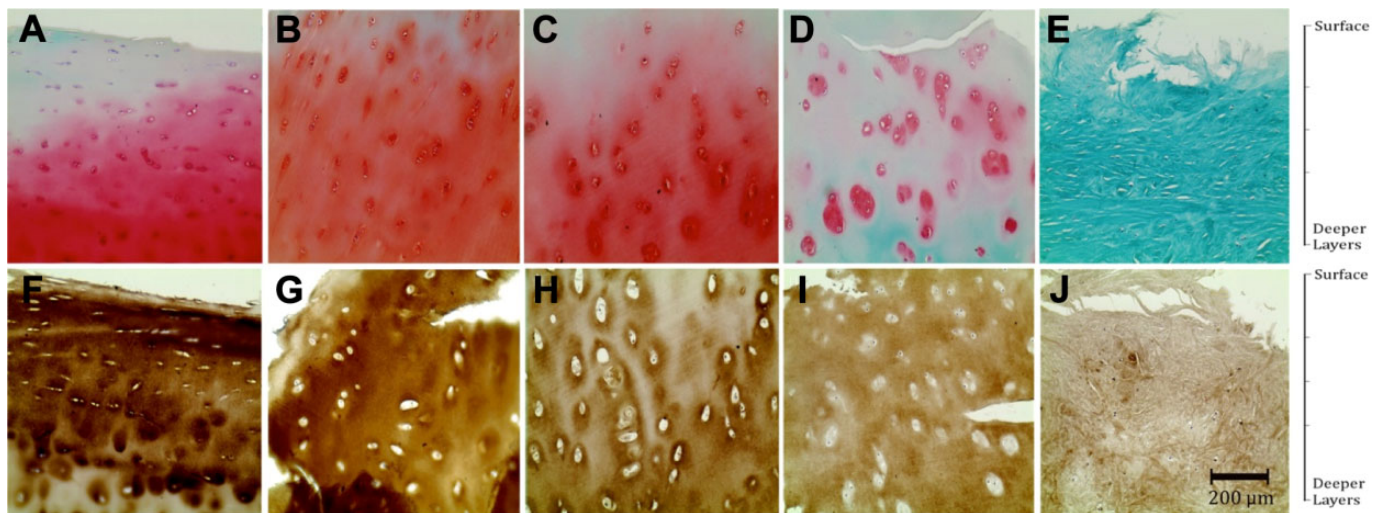
**Figure 3.** Bar graphs showing mean  $\pm$  SD for (A) viability percentage and (B) OARSI (Osteoarthritis Research Society International) grade in the study and control groups.

not been histologically evaluated, one may predict that fibrocartilage formation will prevail in the healing process, similar to the microfracture technique itself. Thus, a poor-quality cartilage will eventually fail and lead toward OA.<sup>29</sup> To our knowledge, this is the first study that compares viability and tissue quality of chondral flap to a matched control sample in a cohort of patients. The tissue quality, viability, and molecular expression of chondral flaps and surrounding tissues still remain to be extensively studied, although it is of interest to many researchers and clinicians working in the cartilage restoration field.

Various investigators have focused on estimating the cellular viability of chondral flaps. In a study by Hariri et al,<sup>16</sup> 21 chondral flaps were retrieved from patients with FAI. Similar to our results, cellular viability was reduced. Moreover, this study reported that DNA and glycosaminoglycan content was below that found in normal cartilage, while surrounding cartilage had higher hydroxyproline concentration, which correlates with higher collagen formation and degeneration.<sup>16,60</sup> Unlike our study, the control samples used were animal articular cartilage and human knee cartilage, and no direct comparison of tissue viability and quality was made with the human acetabular articular cartilage surface.<sup>16</sup> In another study by Meulenkamp et al,<sup>32</sup> the reported cellular viability of 12 chondral flaps was higher, with an overall viability of 90%. This was measured from H&E-stained sections, which can overestimate viability, as suggested by the authors. In addition, histological chondral flap analysis showed that half of the patients



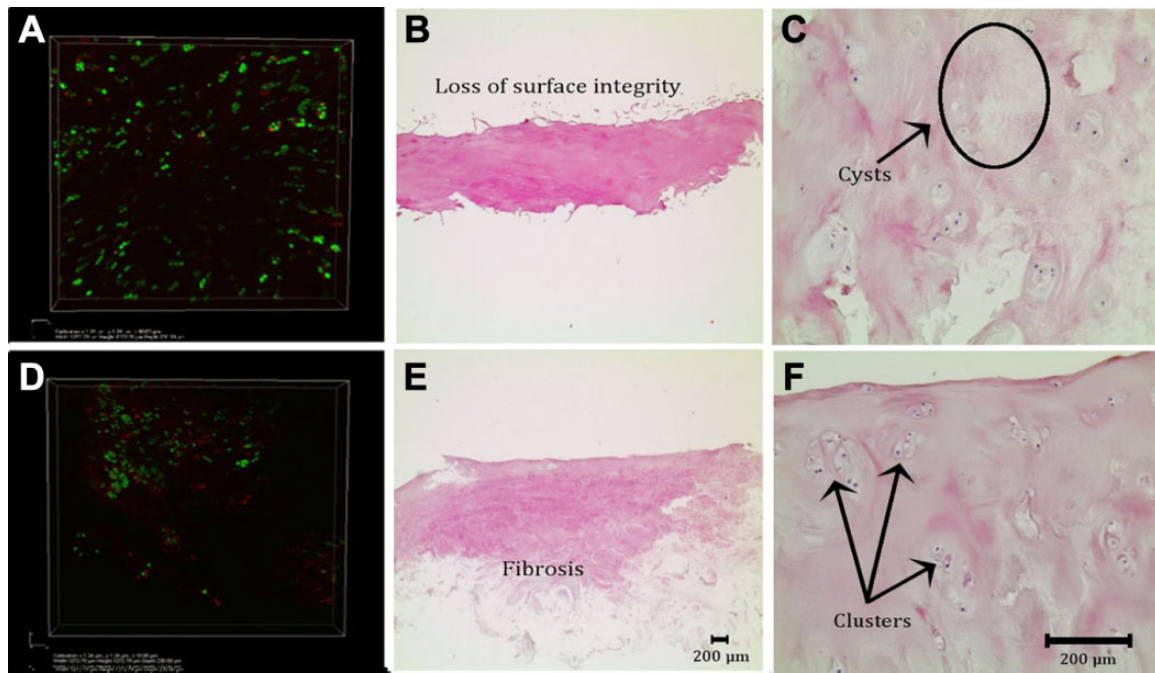
**Figure 4.** Safranin O/fast green stain from different samples at 20 $\times$  and corresponding OARSI grade. (A) Patient 10 (study group), grade 5, showing fibrous tissue, lack of cells, and absence of healthy ECM. (B) Patient 5 (study group), grade 4.5, showing hypocellularity, cellular hypertrophy, clusters, no columnar orientation, and loss of surface integrity. (C) Patient 2 (control group), grade 5, with clusters, cysts, fibrillation, and no columnar orientation. (D) Patient 8 (control group), grade 4, with clusters and poor ECM staining. ECM, extracellular matrix; OARSI, Osteoarthritis Research Society International.



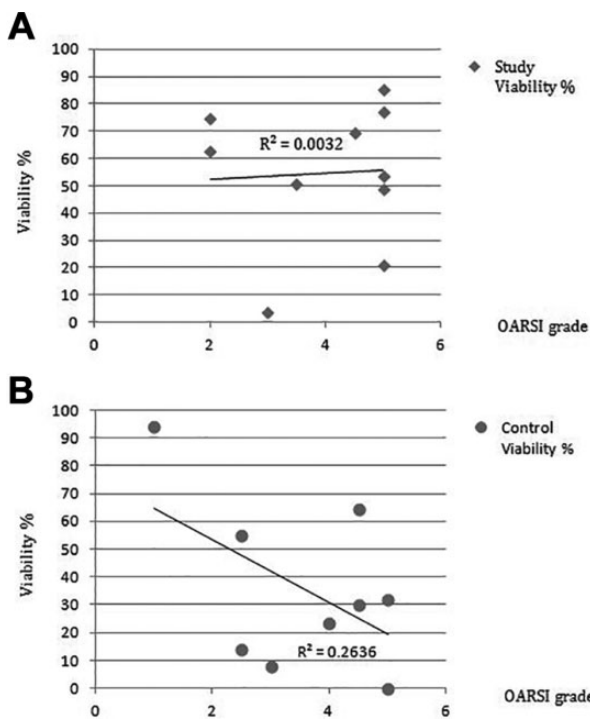
**Figure 5.** Sections at 20 $\times$ . (A-E) Sections stained with safranin O/fast green, going from 1 (A) to 5 (E) in the OARSI grading scale. (F-J) immunohistochemistry for Col II in consecutive sections. (A/F) Patient 1 (control group). (B/G) Patient 3 (study group). (C/H) Patient 7 (study group). (D/I) Patient 8 (control group). (E/J) Patient 10 (study group). Note the progressive cellular hypertrophy, increasing pericellular matrix (PCM) staining, and decreasing staining in ECM from (B) to (D). Section (E) shows fibrosis. Col II, collagen II; ECM, extracellular matrix; OARSI, Osteoarthritis Research Society International.

contained predominantly hyaline cartilage, while the other half had signs of fibrillation; this demonstrates that even with 90% cellular viability, the tissue may have a high index of fibrosis, further supporting our findings. The authors suggested that the varying amounts of fibrocartilage represented anabolic repairing attempts of a metabolically active tissue due to inflammation.<sup>32</sup> Interestingly, a study by Bretschneider et al,<sup>6</sup> which included 6 patients with cam-type FAI, tested the proliferation and differentiation potential of chondrocytes found in samples retrieved from the anterosuperior acetabulum and the anterolateral head-neck region. The chondrocytes were found to be viable in monolayer expansion after 19 days, reaching viability above 90%. However, they were predisposed to dedifferentiation

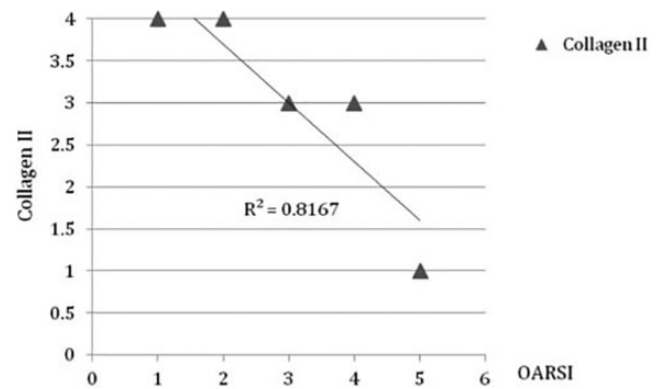
and produced high levels of interleukin 1 beta (IL-1 $\beta$ ).<sup>5,39</sup> But, encouragingly, the chondrocytes were able to be redifferentiated and maintained differentiation when seeded in tri-dimensional hyaluronan-based hydrogel cultivation, showing high expression levels of Col II and aggrecan, as well as decreased production of IL-1 $\beta$ .<sup>6</sup> Clearly, as shown by these studies and ours, there are varying results for percentage viability in chondral flaps and surrounding tissue. However, the data suggest that these chondrocytes may not be suitable for efficient cartilage regeneration given the tissue quality and microenvironment where they are found. This warrants a better understanding of articular cartilage tissue and the molecular background directing chondrocytes when there is joint inflammation.



**Figure 6.** Live/dead and H&E staining for study (A-C) and control (D-F) samples. (A) 10× live/dead stain. (B) 4× H&E stain. (C) 20× H&E stain. (D) 10× live/dead stain. (E) 4× H&E stain. (F) 20× H&E stain. Note in this case the higher viability in the chondral flap sample compared to the control sample. H&E, hematoxylin and eosin.



**Figure 7.** Correlation between cellular viability percentage and OARSI grading for (A) study and (B) control groups. OARSI, Osteoarthritis Research Society International.



**Figure 8.** Correlation between Col II and OARSI in 5 sections: OARSI graded 1 through 5. Note the inverse relation between scales. Col II, collagen II; OARSI, Osteoarthritis Research Society International.

In terms of tissue quality and molecular activity, there are many evaluating tools that can be used and can aid in explaining any degeneration that is observed. In the present study, safranin O and immunohistochemistry for Col II showed that there was a declining amount of ECM (ie, aggrecan and Col II) as the tissue degenerates. There seems to be an increase in cellular metabolic activity, as reflected by the hypertrophy of chondrocytes and the intensity of pericellular matrix (PCM) staining.<sup>13,15,28</sup> Cartilage tissue

exposed to mechanical stress and/or aging changes the PCM microenvironment properties through inflammatory cytokines, affecting the chondrocyte metabolism and, therefore, the cell-matrix normal homeostasis.<sup>13,15,35,64</sup> This leads to cell-mediated remodeling processes such as degrading proteoglycans and Col II<sup>28,58,61</sup> by matrix metalloproteinases (MMP) and increasing synthesis of collagen I, III, and X.<sup>19,28,46</sup> This generates cartilage fibrillation with reduced compressive modulus and mechanical fault.<sup>10,28,46</sup> In the present study, the cam-type FAI patients were continuously subject to mechanical stress, which could lead to cartilage degeneration prior to macroscopical changes. Arthroscopic osteoplasty is an important component of cam-type FAI treatment, allowing amendment of alignment and technical cessation of mechanical stress, with restoration of physiological-like mechanical load.<sup>8</sup> Thus, extreme importance should be focused toward addressing patients needing early treatment, prior to the onset of a pro-inflammatory microenvironment. This may avoid anomalous remodeling of ECM by restitution of appropriate mechanical load. However, once remodeling of the articular cartilage takes place, there remains uncertainty whether restoration of the alignment and mechanical load will halt or revert the degeneration. This certainly raises the need for early diagnosis and prognosis in this population. Moreover, Hashimoto et al<sup>17</sup> analyzed gene expression of inflammatory cytokines (ie, IL-8), enzymes (ie, MMP), and structural matrix (ie, Col II) of FAI cartilage samples from the anterolateral femoral head-neck junction and compared it to end-stage OA cartilage. They found that FAI hips contain cartilage with a heightened metabolic state. They proposed that these results could possibly link the pathologic mechanical environment and the metabolic alterations of hip articular cartilage in patients with FAI.<sup>17,45</sup> Similarly, Chinzei et al<sup>7</sup> compared 30 hips with FAI to 30 hips with OA undergoing surgery, and they measured gene expression of inflammatory cytokines and anabolic and catabolic genes from synovium, labrum, and cartilage. The authors reported elevation of metabolism and inflammatory cytokines not only on the FAI cartilage but also on the labrum and adjacent synovial tissue.<sup>7</sup> These findings suggest an inflammatory microenvironment (ie, high IL-1 $\beta$  levels, IL-8) that may prevent optimal cartilage regeneration from the most viable chondrocytes.<sup>28,46,50,54</sup> In the present study, for example, patient 3 had a control viability of 64.6% but an OARSI grading of 4.5, suggesting that the cartilage morphology and its compressive modulus are compromised despite having some viability. In the future, tissue quality and inflammatory markers may become the diagnostic tools of intra-articular cartilage degeneration.

In our study, control samples showed cartilage degeneration and loss of viability. This may prove the concept of a “pre-osteoarthritic” joint disease in this population, as proposed previously.<sup>7,17,49</sup> Recently, Ryd et al<sup>49</sup> proposed the term *pre-osteoarthritis* to define the preclinical phase of ongoing catabolic changes at the molecular and cellular level in the articular joint, preceding OA macroscopic changes and/or symptoms. Regardless of the pathological drive leading to the loss of anatomic integrity, the mechanotransduction signal received in chondrocytes leads toward

cartilage remodeling, inflammation, and degeneration.<sup>25</sup> Further studies establishing expression of inflammatory cytokines or breakdown products of cartilage may help advance our understanding of the FAI syndrome physiopathology and may harness new diagnostic tools.

With regard to treatment options for chondral flaps in FAI, some authors have suggested suturing and adhesive techniques to preserve the chondral flap.<sup>23,51,52,59,63</sup> According to short-term clinical results, patients experience pain relief and improved function<sup>9,30</sup>; however, it seems dubious to assume that reattaching a degenerative and unviable chondral flap can induce cartilage healing.

There were some limitations in the present study. The sample size was small, and inclusion of only male patients may be insufficient. Unfortunately, it did not allow for identification of subgroups and risk factors in the detrimental cartilage quality. In addition, tissue viability might have been negatively influenced in both groups by the harvesting technique and preservation, affecting viability percentage results. Yet tissue quality clearly showed degeneration, and this was not subject to such events. Moreover, control samples were taken from a nonweightbearing area, prioritizing the patient’s care without losing the objective of the study.

Although patients undergoing reattachment experience pain relief and function recovery, our results suggest that the degenerative findings seen in cartilage flaps in cam-type FAI may not heal or may function poorly, which will eventually lead to OA. However, to have a better understanding of the chondral flap, case-control studies comparing reattachment with excision and microfracture, with additional postoperative second-look arthroscopy and biopsy, should be performed. Future studies with larger cohorts of patients addressing both sexes and a wide age range, studies with inclusion of a separate matched set of joints and sampling from other normal-appearing areas or weightbearing areas, and perifoveal sampling with histological evaluation from patients undergoing hip arthroscopy procedure for noncartilaginous pathologies will aid in ratifying the findings of the present study. This is a pilot study that needs further research, and it sheds light into FAI physiopathology and questions the utility of the chondral flap reattachment technique for joint preservation.

## CONCLUSION

Despite appearing macroscopically normal, the chondral flaps from patients with cam-type FAI lesion had loss of viability and tissue degeneration. In addition, control samples obtained away from the injury area also displayed cartilage damage and degeneration. Consideration of these degenerative findings should be taken into account when attempting a reattachment of the chondral flap.

## REFERENCES

1. Banerjee P, McLean CR. Femoroacetabular impingement: a review of diagnosis and management. *Curr Rev Musculoskelet Med.* 2011;4(1): 23-32.



2. Barrientos C, Barahona M, Diaz J, Branes J, Chaparro F, Hinzpeter J. Is there a pathological alpha angle for hip impingement? A diagnostic test study. *J Hip Preserv Surg*. 2016;3(3):223-228.
3. Beall DP, Sweet CF, Martin HD, et al. Imaging findings of femoroacetabular impingement syndrome. *Skeletal Radiol*. 2005;34(11):691-701.
4. Beck M, Kalhor M, Leunig M, Ganz R. Hip morphology influences the pattern of damage to the acetabular cartilage: femoroacetabular impingement as a cause of early osteoarthritis of the hip. *J Bone Joint Surg Br*. 2005;87(7):1012-1018.
5. Berenbaum F. Osteoarthritis as an inflammatory disease (osteoarthritis is not osteoarthrosis!). *Osteoarthritis Cartilage*. 2013;21(1):16-21.
6. Bretschneider H, Stiehler M, Hartmann A, et al. Characterization of primary chondrocytes harvested from hips with femoroacetabular impingement. *Osteoarthritis Cartilage*. 2016;24(9):1622-1628.
7. Chinzei N, Hashimoto S, Fujishiro T, et al. Inflammation and degeneration in cartilage samples from patients with femoroacetabular impingement. *J Bone Joint Surg Am*. 2016;98(2):135-141.
8. Chow R, Kuzma S, Krych A, Levy B. Arthroscopic femoral neck osteoplasty in the treatment of femoroacetabular impingement. *Arthrosc Tech*. 2014;3(1):e21-e25.
9. Clohisy JC, St John LC, Schutz AL. Surgical treatment of femoroacetabular impingement: a systematic review of the literature. *Clin Orthop Relat Res*. 2010;468(2):555-564.
10. Cucchiari M, de Girolamo L, Filardo G, et al. Basic science of osteoarthritis. *J Exp Orthop*. 2016;3(1):22.
11. Domb BG, El Bitar YF, Lindner D, Jackson TJ, Stake CE. Arthroscopic hip surgery with a microfracture procedure of the hip: clinical outcomes with two-year follow-up. *Hip Int*. 2014;24(5):448-456.
12. Ganz R, Leunig M, Leunig-Ganz K, Harris WH. The etiology of osteoarthritis of the hip: an integrated mechanical concept. *Clin Orthop Relat Res*. 2008;466(2):264-272.
13. Goldring MB, Goldring SR. Osteoarthritis. *J Cell Physiol*. 2007;213(3):626-634.
14. Griffin DR, Dickenson EJ, O'Donnell J, et al. The Warwick Agreement on femoroacetabular impingement syndrome (FAI syndrome): an international consensus statement. *Br J Sports Med*. 2016;50(19):1169-1176.
15. Guilak F, Alexopoulos LG, Upton ML, et al. The pericellular matrix as a transducer of biomechanical and biochemical signals in articular cartilage. *Ann N Y Acad Sci*. 2006;1068:498-512.
16. Hariri S, Truntzer J, Smith RL, Safran MR. Biochemical and cellular assessment of acetabular chondral flaps identified during hip arthroscopy. *Arthroscopy*. 2015;31(6):1077-1083.
17. Hashimoto S, Rai MF, Gill CS, Zhang Z, Sandell LJ, Clohisy JC. Molecular characterization of articular cartilage from young adults with femoroacetabular impingement. *J Bone Joint Surg Am*. 2013;95(16):1457-1464.
18. Hetsroni I, Dela Torre K, Duke G, Lyman S, Kelly BT. Sex differences of hip morphology in young adults with hip pain and labral tears. *Arthroscopy*. 2013;29(1):54-63.
19. Hosseininia S, Weis MA, Rai J, et al. Evidence for enhanced collagen type III deposition focally in the territorial matrix of osteoarthritic hip articular cartilage. *Osteoarthritis Cartilage*. 2016;24(6):1029-1035.
20. Ito K, Leunig M, Ganz R. Histopathologic features of the acetabular labrum in femoroacetabular impingement. *Clin Orthop Relat Res*. 2004;429:262-271.
21. Ito K, Minka MA II, Leunig M, Werlen S, Ganz R. Femoroacetabular impingement and the cam-effect. A MRI-based quantitative anatomical study of the femoral head-neck offset. *J Bone Joint Surg Br*. 2001;83(2):171-176.
22. Karthikeyan S, Roberts S, Griffin D. Microfracture for acetabular chondral defects in patients with femoroacetabular impingement: results at second-look arthroscopic surgery. *Am J Sports Med*. 2012;40(12):2725-2730.
23. Kaya M, Hirose T, Yamashita T. Bridging suture repair for acetabular chondral carpet delamination. *Arthrosc Tech*. 2015;4(4):e345-e348.
24. Kaya M, Suzuki T, Emori M, Yamashita T. Hip morphology influences the pattern of articular cartilage damage. *Knee Surg Sports Traumatol Arthrosc*. 2016;24(6):2016-2023.
25. Leong DJ, Hardin JA, Cobelli NJ, Sun H. Mechanotransduction and cartilage integrity. *Ann N Y Acad Sci*. 2011;1240:32-37.
26. Lodhia P, Gui C, Chandrasekaran S, Suarez-Ahedo C, Vemula SP, Domb BG. Microfracture in the hip: a matched-control study with average 3-year follow-up. *J Hip Preserv Surg*. 2015;2(4):417-427.
27. Lorenz J, Seebach E, Hackmayer G, et al. Melanocortin 1 receptor-signaling deficiency results in an articular cartilage phenotype and accelerates pathogenesis of surgically induced murine osteoarthritis. *PLoS One*. 2014;9(9):e105858.
28. Maldonado M, Nam J. The role of changes in extracellular matrix of cartilage in the presence of inflammation on the pathology of osteoarthritis. *Biomed Res Int*. 2013;2013:284873.
29. Mardones R, Larrain C. Cartilage restoration technique of the hip. *J Hip Preserv Surg*. 2015;3(1):30-36.
30. Matsuda DK, Carlisle JC, Arthurs SC, Wierks CH, Philippon MJ. Comparative systematic review of the open dislocation, mini-open, and arthroscopic surgeries for femoroacetabular impingement. *Arthroscopy*. 2011;27(2):252-269.
31. McCarthy JC, Noble PC, Schuck MR, Wright J, Lee J. The Otto E. Aufranc Award: the role of labral lesions to development of early degenerative hip disease. *Clin Orthop Relat Res*. 2001;393:25-37.
32. Meulenkamp B, Gravel D, Beaulé PE. Viability assessment of the chondral flap in patients with cam-type femoroacetabular impingement: a preliminary report. *Can J Surg*. 2014;57(1):44-48.
33. Milz S, Valassis G, Buttner A, et al. Fibrocartilage in the transverse ligament of the human acetabulum. *J Anat*. 2001;198(pt 2):223-228.
34. Monazzam S, Bomar JD, Cidambi K, Kruk P, Hosalkar H. Lateral center-edge angle on conventional radiography and computed tomography. *Clin Orthop Relat Res*. 2013;471(7):2233-2237.
35. Nam J, Perera P, Liu J, et al. Sequential alterations in catabolic and anabolic gene expression parallel pathological changes during progression of monoiodoacetate-induced arthritis. *PLoS One*. 2011;6(9):e24320.
36. Nepple JJ, Carlisle JC, Nunley RM, Clohisy JC. Clinical and radiographic predictors of intra-articular hip disease in arthroscopy. *Am J Sports Med*. 2011;39(2):296-303.
37. Nepple JJ, Larson CM, Smith MV, et al. The reliability of arthroscopic classification of acetabular rim labrochondral disease. *Am J Sports Med*. 2012;40(10):2224-2229.
38. Nepple JJ, Riggs CN, Ross JR, Clohisy JC. Clinical presentation and disease characteristics of femoroacetabular impingement are sex-dependent. *J Bone Joint Surg Am*. 2014;96(20):1683-1689.
39. Niethard M, Schneider U, Wallich R. Differential behaviour of human adult arthrotic chondrocytes under 2D- and 3D-cultivation set-ups in a collagen I gel [in German]. *Z Orthop Ihre Grenzgeb*. 2007;145(1):102-107.
40. Notzli HP, Wyss TF, Stoecklin CH, Schmid MR, Treiber K, Hodler J. The contour of the femoral head-neck junction as a predictor for the risk of anterior impingement. *J Bone Joint Surg Br*. 2002;84(4):556-560.
41. Pascual Garrido C, Hakimiyan AA, Rappoport L, Oegema TR, Wimmer MA, Chubinskaya S. Anti-apoptotic treatments prevent cartilage degradation after acute trauma to human ankle cartilage. *Osteoarthritis Cartilage*. 2009;17(9):1244-1251.
42. Pascual-Garrido C, Hao J, Schrock J, Mei-Dan O, Chahla J. Arthroscopic juvenile allograft cartilage implantation for cartilage lesions of the hip. *Arthrosc Tech*. 2016;5(4):e929-e933.
43. Philippon MJ, Michalski MP, Campbell KJ, et al. An anatomical study of the acetabulum with clinical applications to hip arthroscopy. *J Bone Joint Surg Am*. 2014;96(20):1673-1682.
44. Philippon MJ, Schenker ML, Briggs KK, Maxwell RB. Can microfracture produce repair tissue in acetabular chondral defects? *Arthroscopy*. 2008;24(1):46-50.
45. Pollard TC, Gwilym SE, Carr AJ. The assessment of early osteoarthritis. *J Bone Joint Surg Br*. 2008;90(4):411-421.

46. Poole AR, Kobayashi M, Yasuda T, et al. Type II collagen degradation and its regulation in articular cartilage in osteoarthritis. *Ann Rheum Dis*. 2002;61(suppl 2):ii78-81.
47. Pritzker KP, Gay S, Jimenez SA, et al. Osteoarthritis cartilage histopathology: grading and staging. *Osteoarthritis Cartilage*. 2006;14(1):13-29.
48. Rakhra KS, Sheikh AM, Allen D, Beaulé PE. Comparison of MRI alpha angle measurement planes in femoroacetabular impingement. *Clin Orthop Relat Res*. 2009;467(3):660-665.
49. Ryd L, Brittberg M, Eriksson K, et al. Pre-osteoarthritis: Definition and diagnosis of an elusive clinical entity. *Cartilage*. 2015;6(3):156-165.
50. Sandell LJ. Modern molecular analysis of a traditional disease: progression in osteoarthritis. *Arthritis Rheum*. 2007;56(8):2474-2477.
51. Sekiya JK, Martin RL, Lesniak BP. Arthroscopic repair of delaminated acetabular articular cartilage in femoroacetabular impingement. *Orthopedics*. 2009;32(9).
52. Stafford GH, Bunn JR, Villar RN. Arthroscopic repair of delaminated acetabular articular cartilage using fibrin adhesive. Results at one to three years. *Hip Int*. 2011;21(6):744-750.
53. Steadman JR, Rodkey WG, Briggs KK. Microfracture: its history and experience of the developing surgeon. *Cartilage*. 2010;1(2):78-86.
54. Stoop R, Albrecht D, Gaissmaier C, et al. Comparison of marker gene expression in chondrocytes from patients receiving autologous chondrocyte transplantation versus osteoarthritis patients. *Arthritis Res Ther*. 2007;9(3):R60.
55. Tomczak RJ, Guenther KP, Rieber A, Mergo P, Ros PR, Brambs HJ. MR imaging measurement of the femoral antetorsional angle as a new technique: comparison with CT in children and adults. *AJR Am J Roentgenol*. 1997;168(3):791-794.
56. Tönnes D. *Congenital Dysplasia and Dislocation of the Hip in Children and Adults*. Berlin: Springer; 1987.
57. Tönnes D, Heinecke A. Diminished femoral antetorsion syndrome: a cause of pain and osteoarthritis. *J Pediatr Orthop*. 1991;11(4):419-431.
58. Troeberg L, Nagase H. Proteases involved in cartilage matrix degradation in osteoarthritis. *Biochim Biophys Acta*. 2012;1824(1):133-145.
59. Tzaveas A, Villar R. Arthroscopic repair of acetabular chondral delamination with fibrin adhesive. *Hip Int*. 2010;20(1):115-119.
60. van den Boom R, Brama PA, Kiers GH, de Groot J, van Weeren PR. Assessment of the effects of age and joint disease on hydroxyproline and glycosaminoglycan concentrations in synovial fluid from the metacarpophalangeal joint of horses. *Am J Vet Res*. 2004;65(3):296-302.
61. Wu W, Billingham RC, Pidoux I, et al. Sites of collagenase cleavage and denaturation of type II collagen in aging and osteoarthritic articular cartilage and their relationship to the distribution of matrix metalloproteinase 1 and matrix metalloproteinase 13. *Arthritis Rheum*. 2002;46(8):2087-2094.
62. Yanke AB, Khair MM, Stanley R, et al. Sex differences in patients with cam deformities with femoroacetabular impingement: 3-dimensional computed tomographic quantification. *Arthroscopy*. 2015;31(12):2301-2306.
63. Yen YM, Kocher MS. Chondral lesions of the hip: microfracture and chondroplasty. *Sports Med Arthrosc*. 2010;18(2):83-89.
64. Zelenski NA, Leddy HA, Sanchez-Adams J, et al. Type VI collagen regulates pericellular matrix properties, chondrocyte swelling, and mechanotransduction in mouse articular cartilage. *Arthritis Rheumatol*. 2015;67(5):1286-1294.