



Arthroscopic Focal Subspinal Decompression and Management of Pincer-Type Femoroacetabular Impingement

Renato Locks, M.D., Hajime Utsunomiya, M.D., Ph.D., Ioanna Bolia, M.D., M.Sc., Sandeep Mannava, M.D., Ph.D., Jorge Chahla, M.D., and Marc J. Philippon, M.D.

Abstract: Femoroacetabular impingement syndrome is a common hip pathology significantly affecting not only the intra- and extra-articular structures but also the biomechanical function of the joint. Cam and pincer bony lesions have been extensively studied. However, during recent years, other types of extra-articular impingement between the pelvic and femoral bone have been investigated. When a prominent or morphologically abnormal anterior-inferior iliac spine (AIIS) impinges repetitively on the femoral side during motion, the subspinal acetabular region becomes prominent and extends toward the intra-articular part of the joint. This results in restriction of the range of motion of the hip and pain, especially with flexion. Therefore, during hip arthroscopy, it is necessary to evaluate the subspinal region (triangular area located at 1:30 to 2:30 o'clock using the acetabular clock face system). For the correction of the acetabular bone pathology to be complete, the surgeon should focus both on the pincer and subspinal impingement lesions. This article describes our preferred technique to successfully address subspinal and pincer acetabular impingement during hip arthroscopy. The pearls and pitfalls of this technique are discussed.

Pincer-type femoroacetabular impingement (FAI) is a source of significant hip pain in up to 8% of the general population.^{1,2} Pincer lesions can have numerous etiologies, including localized anterolateral overcoverage, anterior overcoverage from true

retroversion of the acetabulum, or global overcoverage (present with coxa profunda and acetabular protrusio). Recently, anterior-inferior iliac spine (AIIS) subspinal FAI impingement has also been recognized as a cause of pincer-sided lesions.³

Additionally, the AIIS is an extracapsular bony prominence found superior to the anterolateral acetabular rim. It is composed of 2 facets (superior and inferior) separated by a ridge. Morphologic changes in this region were described by Hestroni et al.⁴ using computed tomography. Type I is represented by a smooth ilium wall between the AIIS and the acetabular rim, type II is when the AIIS extends to the level of the rim, and type III when the AIIS extends distally to the acetabular rim.

The subspinal region is essentially intra-articular, and morphological changes in this region may develop from excessive and recurrent tension of the iliofemoral ligament and the anterior hip capsule during repetitive forces in extension and external rotation of the hip—commonly observed in running and fields sports.^{5,6} A bony prominence on the subspinal region is an important component of the intra-articular hip impingement and can be considered a different pathologic entity from extra-articular AIIS abnormalities.

Studies have shown the clinical benefit of arthroscopic and open AIIS resection.^{4,7} Subspinal

From the Steadman Philippon Research Institute, Vail, Colorado, U.S.A.

The authors report the following potential conflicts of interest or sources of funding: S.M. receives institutional grants from the American Board of Medical Specialties—American Board of Orthopaedic Surgeons, Visiting Scholars Grant; and has a patent issued for Wake Forest University Health Sciences (patent no. 08926626, utility patent awarded January 6, 2015). M.J.P. receives consulting/royalty payments directly related to products discussed from Smith & Nephew; consulting/royalty payments for other products from Smith & Nephew, ArthroSurface, MJP Innovations, Micro-Imaging Solutions, Bledsoe, DonJoy, ConMed Linvatec, Slack, Elsevier, and the Vail Valley Medical Center; research or other financial support from the same company as the products discussed from Smith & Nephew, Ossur, Arthrex, and Siemens; has a patent issued for Smith & Nephew; has stock/stock options in ArthroSurface, HIPCO, Micro-Imaging Solutions; and is a board member in Steadman Philippon Research Institute, Asian American Institute for Research and Education (ASIAM), Vail Health Services, and the International Society for Hip Arthroscopy.

Received January 26, 2017; accepted March 9, 2017.

Address correspondence to Marc J. Philippon, M.D., Steadman Philippon Research Institute, 181 West Meadow Drive, Suite 400, Vail, CO 81657, U.S.A. E-mail: karen.briggs@sprivail.org

*© 2017 by the Arthroscopy Association of North America
2212-6287/17116/\$36.00*

<http://dx.doi.org/10.1016/j.eats.2017.03.016>

Table 1. Pearls and Pitfalls

Pearls	Pitfalls
Position patient with 15° of internal rotation, 10° of lateral tilt, 10° of flexion, and neutral abduction while in traction.	Over-resection of the proximal capsule (impedes subsequent capsular closure)
The camera is positioned in the midanterior portal while a shaver is placed in the anterolateral portal to allow for adequate exposure of the supra-acetabular and subspinal capsulolabral space.	It is important to avoid excessive proximal bone resection to preserve the direct head of the rectus and the superior capsular insertion.
Use of a 4.5-mm round burr, attempting to shape the subspinal space as a flat surface	Change portals to assess the whole surface from different angles.
Repair the labrum after the subspinal decompression and rim trimming.	

impingement constitutes an underaddressed pathology, because nonresected impinging AIIS has been reported in up to 46% of revision hip arthroscopy cases.⁸ Surgical management of FAI aims to address the soft-tissue and bony abnormalities that result in abnormal impingement during hip range of motion. Therefore, recontouring the subspinal region is critical for an adequate treatment. This article describes our preferred technique for focal subspinal decompression and rim trimming in the setting of arthroscopic treatment of femoroacetabular impingement.

Surgical Technique

Our preferred surgical technique for focal AIIS subspinal decompression and pincer rim trimming can be seen in detail in [Video 1](#). Based on previous studies showing the relationship between nontreated AIIS deformities and revision hip arthroscopy, a focal subspinal decompression is performed during the rim acetabular trimming in all patients. Pearls and pitfalls of the procedure are noted in [Table 1](#) and the advantages and disadvantages associated with it in [Table 2](#).

Patient Positioning

The patient is placed in a modified supine position on a traction-operating table (Steris/Amsco, Mentor, OH). A combined epidural with a lumbar plexus sciatic regional block is our preferred anesthetic modality. A bilateral lower extremity examination is performed to assess for hip range of motion. Traction is gently applied to the leg with 15° of internal rotation, 10° of lateral tilt, 10° of flexion, and neutral abduction. To prevent neurologic complications, an extrawide perineal post is used and lateralized toward the ipsilateral side in the perineal space to minimize pressure on the pudendal nerve and to force the femoral head laterally, shifting the vector of forces. Adequate traction is verified with

the fluoroscope (confirmed with a “vacuum sign” and 1 cm of joint distraction).

Arthroscopic Technique

After routine preparation and draping of the affected hip, the arthroscopic procedure is performed with the patient in the supine position. Standard anterolateral and midanterior portals are established to allow access to the central compartment ([Figs 1 and 2](#)). A diagnostic arthroscopy is performed using a 70° arthroscope (Smith & Nephew, Andover, MA) to evaluate for intra-articular pathology. An interportal capsulotomy is performed with a beaver blade (BVI, Waltham, MA) approximately 10 to 15 mm distal to the labrum to improve both visualization and intervention within the hip joint. Also, to allow proper capsular closure at the end of the procedure, the capsule is incised parallel to the acetabular rim from the 12- to 3-o’clock position, connecting the midanterior and anterolateral portals. The camera is placed in the midanterior portal and an arthroscopic shaver (Smith & Nephew) in the anterolateral portal to open the supra-acetabular and AIIS subspinal capsulolabral space in the anterior-superior portion of the acetabulum ([Fig 3](#)). Considering 3’o clock as the psoas “U,” the subspinal space has a triangular shape and is located from the 1:30 to 2:30 position on the acetabular clock face.⁹ It is critical to avoid over-resection of the proximal capsule to allow capsular closure at the end of the procedure. Next, the interval between the proximal capsule and labrum is developed using a series of mechanical shavers and a radiofrequency probe ([Fig 4](#)).

After cleaning the capsulolabral space, rim trimming and focal subspine decompression are performed with a 4.5-mm round prebent polishing bur (Linvatec, Largo, FL), positioned in the anterolateral portal ([Fig 5](#)) and the camera in the midanterior portal without labral detachment. Based on the false profile view radiograph,

Table 2. Advantages and Limitations

Advantages	Limitations
Technically simple	Limited outcome data
Addressed the subspinal and pincer-type impingement	Over-resection can lead to rectus femoris avulsion (direct head)
The resection amount can be estimated using the false profile radiographs	
Intraoperative dynamic examination to assess impingement	
Improves the bone surface and angles for anchor placement during the labral repair	
Fluoroscopy is not necessary during the course of the technique	

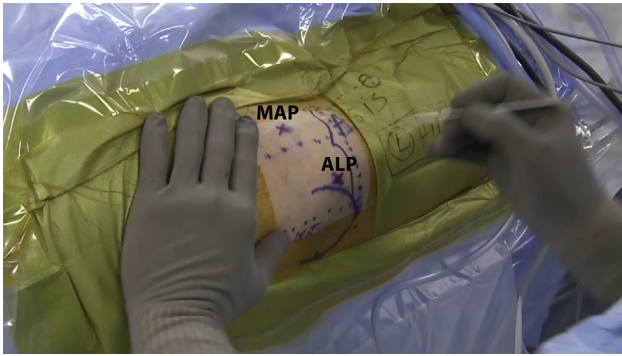


Fig 1. Intraoperative picture of a left hip, illustrating the 2 standard portals used for this procedure. In this image, the head of the patient is on the right and the foot on the left. (ALP, anterolateral portal; ASIS, anterosuperior iliac spine; MAP, midanterior portal.)

the focal subspinal decompression is performed intending to make the subspinal area a flat surface without bony prominences (Fig 6). It is important to avoid excessive proximal bone resection to preserve the direct head of the rectus femoris and the superior capsular insertion. (A possible way to prevent this is to avoid going proximally more than 2 diameters of the Burr, or a distance no more than 9-10 mm.)

Typically, the pincer resection is performed up to the end of rim chondrosis (3-5 mm). The preoperative center-edge angle should be considered at this stage to avoid over-resection. The estimated relationship is defined as follows: change in center-edge angle = $1.8 + (0.64 \times \text{rim reduction [in millimeters]})$.¹⁰ If the pincer lesion extends near the rectus indirect head, the excess bone should be removed with an osteotome (Smith & Nephew) to avoid tendon injury (Fig 7). Unstable acetabular rim fragments should also be removed.

After completing the focal subspinal decompression and rim trimming, labral repair is achieved with sutures

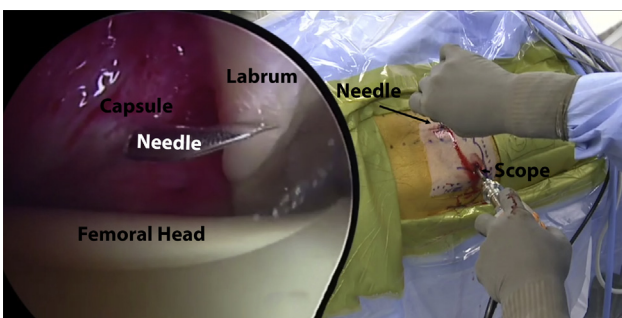


Fig 2. This picture illustrates the establishment of the mid-anterior portal under arthroscopic visualization in a left hip. In the image on the left, an arthroscopic view (as viewed from the midanterior portal) shows the safe joint entrance zone composed by the labrum (on top) and the femoral head (below). In this image, a needle is being inserted through the capsule.

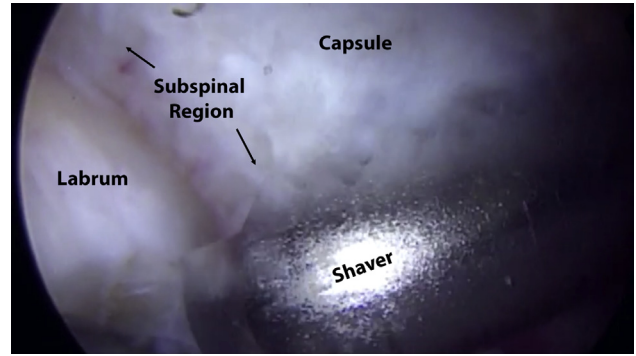


Fig 3. Arthroscopic view of a left hip with the camera on the midanterior portal and the shaver on the anterolateral portal. The shaver is used to identify the subspinal region prior to bone trimming. Determining the space between the labrum and the capsule might be challenging; therefore, careful identification should be performed before starting to shave the structures.

looped around the torn segments or placed through the torn labrum.¹¹ Suture anchors are used to reattach the labrum; the type of anchor used varies around the acetabular clock face based on the anatomy. Because of reduced bone thickness and to avoid postoperative psoas irritation, a 1.5-mm Jugger-Knot anchor (Biomet, Warsaw, IN) is preferred from the 2 to 4 o'clock position. From the 9 to 1 o'clock position, a 2.3-mm Osteoraptor suture anchor (Smith & Nephew) with blue suture is indicated.

When the labral repair is completed, the traction is released, the hip is flexed 45°, and the impingement area is identified. Correction of cam lesion is challenging, and the amount of bone that should be resected is a point of disagreement. The goal is to achieve a smooth head-neck offset that prevents elevation of the labrum during flexion and achieves a perfect

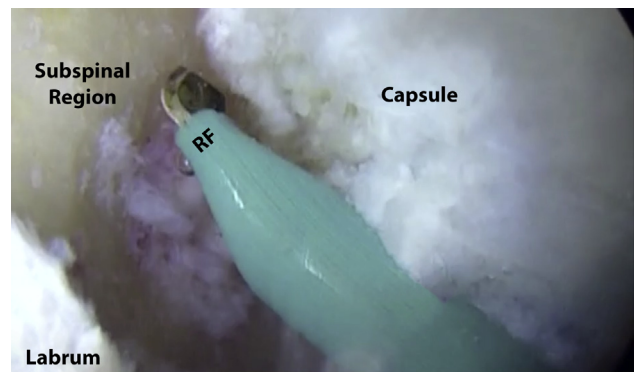


Fig 4. This arthroscopic picture illustrates the use of a radiofrequency probe (RF) for hemostasis and soft tissue debridement after the subspinal decompression and rim trimming in a left hip. The midanterior portal is the viewing portal and the radiofrequency was introduced through the anterolateral portal.

anatomic relationship between the femoral head and acetabular labrum restoring the hip joint seal. The dynamic intraoperative hip examination is the most important tool in determining if adequate resection on the femoral head-neck junction, acetabulum, and subspinal area have been completed.¹²

Capsular Closure

Once the desired intra-articular result has been achieved, the hip is brought into flexion and the foot in internal rotation to relax the anterior capsule and facilitate the closure. An intra-articular cannula (Arthrex) is inserted through the anterolateral portal. A suture-shuttling device (SutureLasso; Arthrex) is used to approximate the proximal leaf of the capsule to the distal leaf passing a no. 2 Vicryl in a suture relay technique. The Arthro-Pierce (Smith & Nephew) is then used to retrieve the lasso through the capsule on the distal side of the capsulotomy. The lasso is used to pass a permanent suture, achieving a side-to-side anastomosis. This is tied arthroscopically with the Quebec City Slider knot followed by racking half-hitch knots outside of the capsule. A total of 2 to 3 side-to-side sutures are placed to complete the capsular closure.¹³

Rehabilitation

Immediately after surgery, a postoperative hip brace (Bledsoe Post-Op Hip Brace) and antirotational boots are applied to protect the operative site and reduce pain. Crutches are used for 4 to 8 weeks depending on each patient's specific needs and the procedures performed. For example, when performing microfracture, the patient is kept with 20 lb of weight bearing for at least 7 weeks. We protect the capsular sutures, by limiting abduction to 0° to 45° and hip flexion 0° to 90°, while external rotation and extension is totally prohibited for the first 3 weeks. This is achieved using the brace.

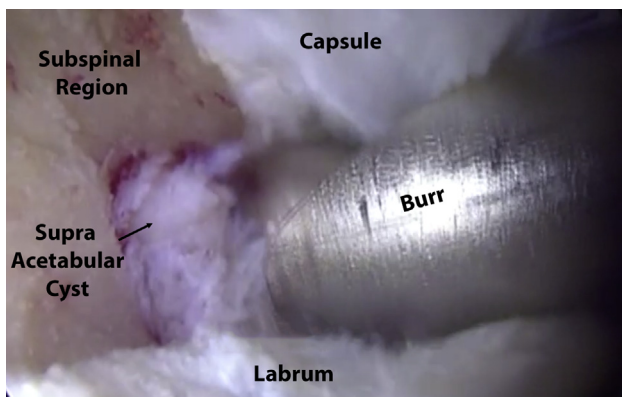


Fig 5. Arthroscopic view in a left hip (as viewed from the anterolateral portal) during the subspinal decompression with a burr (introduced via the anterolateral portal), rim trimming and supra-acetabular cyst removal. Setting the burr in reverse can facilitate progressive removal of the bone.

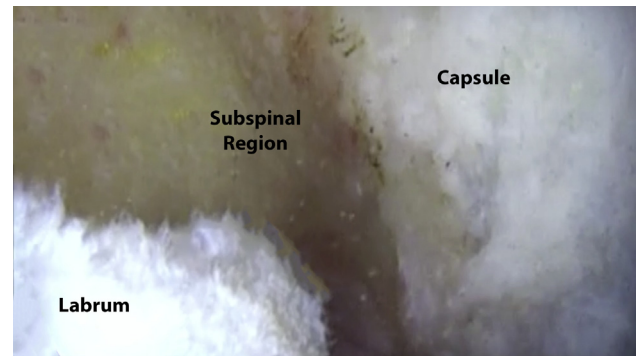


Fig 6. Arthroscopic view from the midanterior portal showing the final aspect after the subspinal decompression and rim trimming in a left hip, prior to a labral repair procedure. This view can be obtained from a midanterior portal and a probe can be introduced to palpate the structures and improve visualization in some cases.

The rehabilitation period consists of 3 phases that should be adjusted appropriately per each patient's needs. The first phase lasts 4 to 6 weeks, where mainly passive exercises are performed. Passive rotational movement is initiated immediately after surgery to prevent adhesion formation. Stationary bike exercise and continuous passive motion machine are useful for that purpose. The "strengthening phase" follows during the next 6 to 12 weeks until we finally proceed to the final phase where sport-specific exercises are emphasized. These 3 phases usually overlap and vary in duration because of the patient-specific approach. Pain management and patient's compliance are important factors to consider before proceeding to the next phase.

Progressive functional and sport-specific rehabilitation help the patient return faster to daily and exercise routine. However, the final "return to sport" decision is

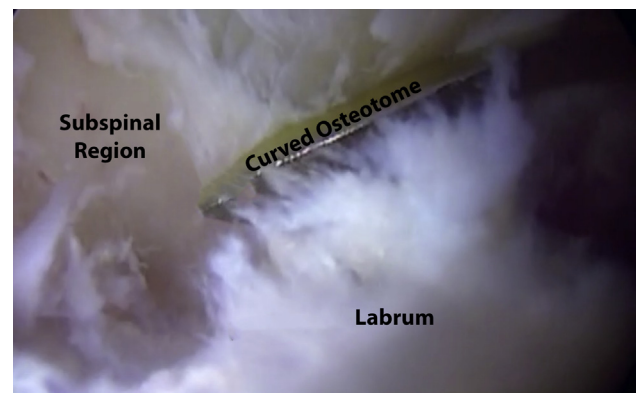


Fig 7. Arthroscopic view of a left hip showing the use of a curved osteotome introduced through the anterolateral portal to remove bony prominences on the superolateral region of the acetabulum intending to protect the indirect head of the rectus femoris. Viewed from the midanterior portal.

based on objective (functional tests) and subjective (physician and patient codecision) factors.

Discussion

This study describes our preferred technique of focal arthroscopic subspinal decompression during rim trimming of the pincer impingement, which provides appropriate protection of the hip capsule, and is followed by capsular closure. Two arthroscopic techniques have been previously described for the treatment of type 3 AIIS.¹⁴ Although they were successful at decompressing the subspinal region, no capsular closure was performed in addition to this. Sharfman et al.¹⁵ described a technique for AIIS decompression. In their technique, a capsular stripping of the anterior acetabular rim was essential for AIIS exposure, and they pointed out wide capsulotomy as one of the pitfalls.

The aims of surgical treatment of pincer-type FAI are 2-fold: to eliminate the cause of the contact and to repair the joint damage it has caused. Surgical treatment of pincer lesions by preservation of the chondrolabral junction and acetabular rim resection is an integral part of the surgical treatment of FAI. Meanwhile, AIIS is a relatively common form of extra-articular FAI. An understanding of the variable morphology and anatomy of AIIS is critical when performing arthroscopic focal subspinal decompression. Computed tomographic studies in asymptomatic patients have shown that mean distances from the AIIS to the acetabular rim are 13.5 mm in male and 11.4 mm in female patients.¹⁶ Typically, each morphologic variant of AIIS correlates with a specific range of motion of the hip joint.¹⁷ We often observe the labral bruising or acetabular cartilage wave sign facing the caudally prominent AIIS in the typical cases of subspinal impingement.

The amount of subspinal decompression is still controversial. It is well described in a previous article that the direct head of rectus femoris originates from its surface area.¹⁸ During the focal subspinal decompression, however, over-resection of the subspinal area should be avoided, because the rectus femoris could be detached from its origin, leading to a potential hip flexion deficit.¹⁹ To minimize this risk, we carefully conduct a dynamic impingement test during hip arthroscopy.

Protecting the soft tissue, especially anterior capsule, is also important in this surgery. Cadaver studies showed a distance of 19.2 mm between the rectus femoris footprint and the acetabular rim and 12.5 mm between the iliocapsularis and the rim.⁹ The hip capsule originated at a mean of 5.1 mm proximal and medial to the bony rim of the acetabulum, creating a small intracapsular recess. This recess was smallest anterosuperiorly and largest posteriorly.²⁰ We believe that it

is very important to avoid the complete capsular detachment and to minimize the capsulotomy size during subspinal decompression, to maintain the native biomechanics of the capsule. As a result, the mid-anterior portal presents as the ideal viewing portal given its ability to provide adequate visualization of the subspinal area whereas the anterolateral portal is useful as the working portal.

In this Technical Note, we describe a focal subspinal decompression that is performed as part of the pincer rim trimming, thus eliminating both the AIIS and the pincer impingement concomitantly. The amount of subspinal bony resection is determined using the false profile radiograph and the dynamic examination. The focal rim resection can be accomplished either with or without labral detachment, followed by either labral refixation, augmentation, or reconstruction. However, biomechanical and subjective and objective patient outcome studies are needed to validate the efficacy of this technique.

References

1. Perreira AC, Hunter JC, Laird T, Jamali AA. Multilevel measurement of acetabular version using 3-D CT-generated models: Implications for hip preservation surgery. *Clin Orthop Relat Res* 2011;469:552-561.
2. Ezoë M, Naito M, Inoue T. The prevalence of acetabular retroversion among various disorders of the hip. *J Bone Joint Surg Am* 2006;88:372-379.
3. Larson CM, Kelly BT, Stone RM. Making a case for anterior inferior iliac spine/subspine hip impingement: Three representative case reports and proposed concept. *Arthroscopy* 2011;27:1732-1737.
4. Hetsroni I, Bedi A, Poultsides L, et al. Anterior inferior iliac spine morphology correlates with hip range of motion: A CT-based classification system and dynamic hip model. *Arthroscopy* 2013;29:e159.
5. Myers CA, Register BC, Lertwanich P, et al. Role of the acetabular labrum and the iliofemoral ligament in hip stability: An in vitro biplane fluoroscopy study. *Am J Sports Med* 2011;39:85S-91S (suppl).
6. Martin HD, Savage A, Braly BA, Palmer IJ, Beall DP, Kelly B. The function of the hip capsular ligaments: A quantitative report. *Arthroscopy* 2008;24:188-195.
7. Larson C, Hapa O, Bedi A. Anatomic footprint of the direct head of the rectus femoris origin: Cadaveric study and clinical series of hips after arthroscopic AIIS/subspine decompression. *Arthroscopy* 2013;12:e215-e216.
8. Larson CM, Giveans MR, Samuelson KM, Stone RM, Bedi A. Arthroscopic hip revision surgery for residual femoroacetabular impingement (FAI) surgical outcomes compared with a matched cohort after primary arthroscopic FAI correction. *Am J Sports Med* 2014;42:1785-1790.
9. Philippon MJ, Michalski MP, Campbell KJ, et al. An anatomical study of the acetabulum with clinical applications to hip arthroscopy. *J Bone Joint Surg Am* 2014;96:1673-1682.

10. Philippon MJ, Wolff AB, Briggs KK, Zehms CT, Koppersmith DA. Acetabular rim reduction for the treatment of femoroacetabular impingement correlates with preoperative and postoperative center-edge angle. *Arthroscopy* 2010;26:757-761.
11. Philippon MJ, Faucet SC, Briggs KK. Arthroscopic hip labral repair. *Arthrosc Tech* 2013;2:e73-e76.
12. Locks R, Chahla J, Mitchell JJ, Soares E, Philippon MJ. Dynamic hip examination for assessment of impingement during hip arthroscopy. *Arthrosc Tech* 2016;5:e1367-e1372.
13. Menge TJ, Chahla J, Soares E, Mitchell JJ, Philippon MJ. The Quebec City Slider: A technique for capsular closure and plication in hip arthroscopy. *Arthrosc Tech* 2016;5:e971-e974.
14. Ilizaliturri VM, Sánchez RA, Suarez-Ahedo C. Arthroscopic decompression of a type III subspine impingement. *Arthrosc Tech* 2016;5:e1425-e1431.
15. Sharfman ZT, Grundshtein A, Paret M, Amit L, Amar E, Rath E. Surgical technique: Arthroscopic osteoplasty of anterior inferior iliac spine for femoroacetabular impingement. *Arthrosc Tech* 2016;5:e601-e606.
16. Amar E, Druckmann I, Flusser G, Safran MR, Salai M, Rath E. The anterior inferior iliac spine: Size, position, and location. An anthropometric and sex survey. *Arthroscopy* 2013;29:874-881.
17. Hetsroni I, Poultides L, Bedi A, Larson CM, Kelly BT. Anterior inferior iliac spine morphology correlates with hip range of motion: A classification system and dynamic model. *Clin Orthop Relat Res* 2013;471:2497-2503.
18. Ryan JM, Harris JD, Graham WC, Virk SS, Ellis TJ. Origin of the direct and reflected head of the rectus femoris: An anatomic study. *Arthroscopy* 2014;30:796-802.
19. Devitt BM, Smith B, Stapf R, O'Donnell JM. Avulsion of the direct head of rectus femoris following arthroscopic subspine impingement resection: A case report. *J Hip Preserv Surg* 2015;3:56-60.
20. Walters BL, Cooper JH, Rodriguez JA. New findings in hip capsular anatomy: Dimensions of capsular thickness and pericapsular contributions. *Arthroscopy* 2014;30:1235-1245.