

Biological Therapies for Cartilage Lesions in the Hip: A New Horizon

JORGE CHAHLA, MD; ROBERT F. LAPRADE, MD, PHD; RODRIGO MARDONES, MD; JOHNNY HUARD, PHD; MARC J. PHILIPPON, MD; SHANE NHO, MD; OMER MEI-DAN, MD; CECILIA PASCUAL-GARRIDO, MD

abstract

Treatment of hip cartilage disease is challenging, and there is no clear algorithm to address this entity. Biomarkers are arising as promising diagnostic tools because they could play a role in the early assessment of the prearthritic joint and as a prognostic factor before and after treatment. The potential effect of biomarkers may be used to categorize individuals at risk of evolving to severe osteoarthritis, to develop new measures for clinical progression of the disease, and to develop new treatment options for the prevention of osteoarthritis progression. A trend toward a less invasive biological treatment will usher in a new treatment era. With the growth of surgical skills in hip arthroscopy, cartilage restoration techniques are evolving in a fast and exponential manner. Biological and surgical treatments have been proposed to treat these pathologies. Biological treatments include platelet-rich plasma, stem cells or bone marrow aspirate concentration, hyaluronic acid, losartan, and fish oil. Surgical treatments include microfracture alone or augmented, direct repair, autologous chondrocyte implantation, matrix-induced chondrocyte implantation, autologous matrix-induced chondrogenesis, mosaicplasty, osteochondral allograft transplantation, and stem cells implanted in matrix (stem cells in membranes/expanded stem cells). This article reviews new evidence available on treatment options for chondral lesions and early osteoarthritis of the hip. [*Orthopedics*. 20xx; xx(x):xxxx-xxxx.]

knee cartilage imaging and surgical procedures are being extrapolated to the hip joint; however, this cannot be assumed because cartilage and biomechanics are disparate among joints.^{4,6}

The authors are from the Steadman Philippon Research Institute (JC, RFL, JH, MJP), The Steadman Clinic, Vail, Colorado; the Clinica Las Condes (RM), Centro Terapia Regenerativa Celular, Las Condes, Región Metropolitana, Chile; the Department of Orthopedic Surgery (SN), Rush University Medical Center, Chicago, Illinois; and the Hip Preservation Center (OM-D, CP-G), Department of Orthopedics, University of Colorado, Denver, Colorado.

Drs Chahla, Huard, Mei-Dan, and Pascual-Garrido have no relevant financial relationships to disclose. Dr LaPrade is a paid consultant for and receives royalties from Arthrex, Ossur, and Smith & Nephew. Dr Mardones is a paid consultant for Smith & Nephew and holds stock in Bioscell and Bioteccell. Dr Philippon is a paid consultant for Smith & Nephew and MIS; receives grants from Smith & Nephew, Ossur, and Siemmens; and receives royalties from ArthroSurface and DonJoy. Dr Nho is a paid consultant for Ossur and Stryker and receives research support from Allosource, Arthrex, Athletico, DJ Orthopaedics, Linvatec, Miomed, Smith & Nephew, and Stryker.

Correspondence should be addressed to: Cecilia Pascual-Garrido, MD, Hip Preservation Center, Department of Orthopedics, University of Colorado, 2000 S Colorado Blvd, Colorado Center Tower One, 4500, Denver, CO 80222 (cecilia.pascual-garrido@ucdenver.edu).

Received: November 6, 2015; Accepted: February 1, 2016.

doi: 10.3928/01477447-20160623-01

Hip-preserving techniques have experienced an exponential growth over the past few decades. Improved imaging quality and evolving arthroscopic techniques have led to a better understanding of the pathology and increase in the number of patients diagnosed

with chondral lesions and early osteoarthritis (OA).^{1,2}

Treatment of hip chondral lesions and early OA remains a challenge. This entity has no well-known optimal solution and, if left untreated, can have important deleterious effects on the joint.³ Many of the

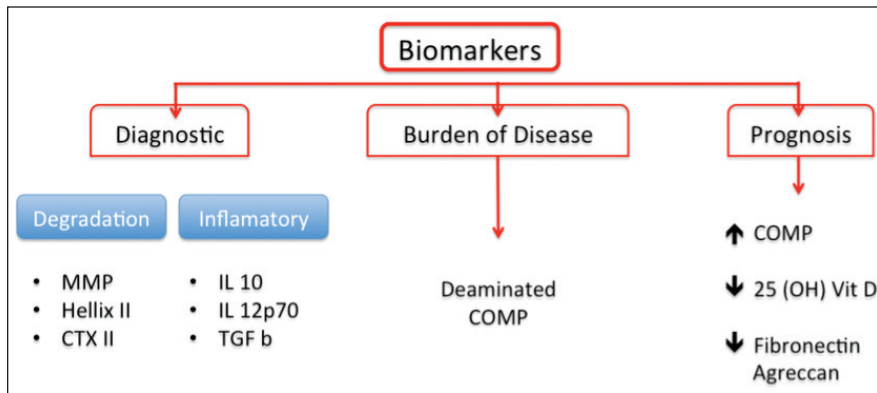


Figure 1: Categories in which biomarkers can be applied to clinical practice. Abbreviations: COMP, cartilage oligomeric matrix protein; CTX II, type II collagen telopeptide; IL, interleukin; MMP, matrix metalloproteinase; TGF, transforming growth factor.

Imaging modalities continue to evolve in parallel, improving early diagnosis and evaluation of cartilage repair. Standard magnetic resonance imaging (MRI) and advanced cartilage MRI sequences such as dGEMRIC, T2 mapping, and T1rho are the most popular imaging modalities for the assessment of chondral lesions, chondropenia, and cartilage repair and regeneration.⁷ However, there is still a need to improve specificity and sensibility between images and intraoperative hip cartilage lesions.⁸

Recently, an era of the prearthritic joint has been projected with the use of biomarkers. Performing a diagnosis of a prearthritic joint disease will allow orthopedic surgeons to prophylactically treat joints before irreversible cartilage damage occurs. Treatment of the preosteoarthritic joint disease is a new concept emphasizing the need for preventive strategies that will modify the course of a disease. The current approach to the clinical treatment of OA is the palliation of symptoms arising from late-stage disease. Early-stage disease or preosteoarthritic disease is clinically silent because structural changes typically precede the clinical signs and symptoms of pain, deformity, functional limitations, and disability. Metabolic changes in articular cartilage, synovium, and subchondral bone may represent the earliest measurable changes in preosteoarthritic conditions. As such, identification and validation of biomarkers

for preosteoarthritic states and at-risk joints may have wide application in clinical trials of new intervention strategies, in routine screening, and in activity-modification programs and return-to-play evaluations. The ability to observe early and reversible cartilage damage supports the development of disease-modifying therapies.

The management of an established chondral lesion and early hip OA is complex and demanding. When treating these patients, not only must the cartilage be assessed, but numerous concomitant pathologies, such as femoroacetabular impingement (FAI), hip dysplasia, and instability, must be taken into account.

Biological and surgical treatments have been proposed to treat these pathologies. Biological treatments include platelet-rich plasma (PRP), stem cells or bone marrow aspirate concentration (BMAC), hyaluronic acid (HA), losartan, and fish oil. Surgical treatments include microfracture alone or augmented,⁹⁻¹³ direct repair,^{14,15} autologous chondrocyte implantation (ACI),^{16,17} matrix-induced chondrocyte implantation,¹⁸ autologous matrix-induced chondrogenesis (AMIC),¹⁸ mosaicplasty,¹⁹⁻²¹ osteochondral allograft transplantation,^{22,23} and stem cells implanted in matrix²⁴ (stem cells in membranes/expanded stem cells). This article reviews new evidence available on treatment options for chondral lesions and early OA of the hip.

THE PREARTHITIC JOINT

Molecular biologic markers (biomarkers), as objectively measurable indicators of the pathophysiology of hip OA, have the potential to improve the diagnosis and estimate the prognosis of hip OA. Molecular biomarkers of OA as intrinsic “indicators of pathologic processes” have shown a good correlation as a link between clinical status and disease pathology, yet no single OA biomarker has been shown to possess adequate sensitivity and specificity to allow for clinical use.^{25,26} Recent data suggest that patients with hip FAI have already elevated biomarkers of cartilage degeneration and inflammation (Figure 1).²⁷

In a systematic review performed by Nepple et al,²⁷ they concluded that although there are more than 70 biomarkers investigated in hip OA, none have been validated for clinical use. The current literature on biomarkers in the pathophysiology of hip OA is expansive and spans several specialties, making it difficult for the clinician to fully understand this topic. The potential effect of biomarkers may be used to categorize individuals at risk of developing severe OA, develop new measures for clinical progression of the disease, and develop new treatment options for the prevention of OA progression.²⁸

CURRENT BIOLOGICAL TREATMENTS FOR EARLY OSTEOARTHRITIS

Autologous Platelet-Rich Plasma

Platelet-rich plasma has been used for more than 50 years in dermatologic and maxillofacial conditions. However, the study and application of this treatment in orthopedics has grown only recently.²⁹ Platelet-rich plasma has been classically defined as “a volume of plasma that has a platelet count above baseline.”³⁰ Platelet-rich plasma is the product of peripheral blood centrifugation that leads to a highly concentrated sample of platelets. The platelets will later undergo degranulation after endogenous (eg, calcium chloride, chitosan) or exogenous activation to re-

lease different growth factors and other active molecules (eg, chemokines, extracellular matrix, proteins, nucleotides), assisting the healing process and improving inflammation.²⁹ Animal OA-induced models treated with PRP embedded in gelatin hydrogel suggest reduction of OA progression.³¹⁻³³ Clinically, limited evidence exists about the effects of PRP in the hip joint to treat early OA. Sanchez et al³⁴ evaluated the effect of hip intra-articular injection of PRP in 40 patients with severe OA and reported a clinically significant reduction in pain and improved function in a mid-term follow-up study.

The real problem when trying to analyze PRP data is the great variability that exists among different products and the different responders to these treatments.³⁵ Low-leukocyte PRP is reported to induce greater cell growth by stimulating chondrocyte anabolism, whereas leukocyte-rich PRP promotes catabolic pathways involving various cytokines³⁶ and can produce more side effects.³⁷ Studies suggest that PRP is capable of reducing pain and improving functional status, especially in patients affected by early to moderate OA.³⁸ In advanced stages, no difference was found between the use of PRP vs HA.³⁸ Other questions that still need to be resolved include when we should use this therapy, how many times it should be used, and whether it can be used as an augmentation of a surgical technique.³⁹

Fish Oil

Eicosapentaenoic acid (EPA) and docosahexaenoic acid (DHA) are omega-3 fatty acids found in fish oil supplements. These fatty acids partly inhibit a number of aspects of inflammation, including leukocyte chemotaxis, adhesion molecule expression and leukocyte-endothelial adhesive interactions, production of inflammatory cytokines, and T-helper 1 lymphocyte reactivity.⁴⁰ Madden et al⁴¹ suggested that it may also alter monocyte CD-44 expression, which is an inflammatory receptor in several lines. This would also modify the

course of HA treatment because its action mechanism depends on this receptor. New evidence⁴² supports that dietary supplementation of omega-3 polyunsaturated fatty acids has a beneficial effect of slowing and reducing inflammation in the pathogenesis of degenerative joint diseases.

Losartan

The renin-angiotensin-aldosterone system (RAS) is a key regulator of the fluid and electrolyte balance and a common target of many pressure regulators. Two angiotensin II (AT II) receptors are commonly recognized: AT1 receptor (AT1R) and AT2 receptor (AT2R). AT1 receptor is responsible for the main functions of AT II, whereas AT2R acts as a counter-regulatory receptor.

Kawakami et al⁴³ reported that articular chondrocytes express AT1R. They suggested that the RAS might be implicated in the expression of matrix metalloproteinases (MMPs) and tissue remodeling in cartilage matrix. Specifically, AT II is reported to be a profibrotic factor that regulates the expression of type I collagen and MMPs such as MMP-2. Moreover, they observed that when stimulated with interleukin-1 (IL-1), the chondrocytes upregulated the expression of angiotensin receptor. Therefore, blocking the mechanism of action of the RAS in the articular joint could lead to enhanced cartilage health, especially in inflammatory circumstances such as that after hip arthroscopy.

Hyaluronic Acid

Numerous studies of knee OA suggest that the intra-articular use of HA products may be a good option in the management of patients with this condition.⁴⁴ Hyaluronic acid can bind to specific receptors: cluster determinant 44 (CD44), intracellular adhesion molecule-1 (ICAM-1) and the receptor for hyaluronate-mediated motility (RHAMM).⁴⁵ Eventually, this triggers various intracellular signal events, such as cytokine release and stimulation of cell cycle proteins. Studies on the effects

of HAs of different molecular weights on specific receptors have reported that the results can vary depending on the size of the HA molecules used. For hip joint treatment, it has been postulated that high-molecular-weight HA (1500-2000 kDa) has better outcomes than low-molecular-weight HA.⁴⁶⁻⁴⁸

Migliore et al⁴⁸ evaluated 120 patients and reported a significant reduction in Lequesne algofunctional index scores and self-reported pain scores via visual analog scale (VAS) at 3 months after high-molecular-weight HA injection, whereas at 12 months, 80% of patients achieved a decrease in symptoms of at least 30%. These results were maintained over time through cyclical repetition of ultrasound-guided injections (at least 1 injection every 6 months). A recent randomized clinical trial⁴⁹ suggested that PRP injection was more efficacious than HA injection in reducing symptoms and improving quality of life in patients with knee OA.

Stem Cells and Bone Marrow Aspiration Concentrate

It is important to understand the differences between BMAC and stem cells. Bone marrow aspiration concentrate is a source of mesenchymal stem cells. Studies suggest that only 0.001% to 0.01% of BMAC are stem cells.⁵⁰ However, BMAC also offers a rich source of growth factors, which may synergistically contribute to chondrogenesis and its anabolic and anti-inflammatory effect.⁵¹

Stem cell treatment requires bone marrow aspiration, isolation of stem cells, and additional seeding and expansion of the cells in the lab for 4 to 6 weeks. With this additional step, there is a possibility of obtaining 80 million cells per milliliter (up to 200 million). Recent studies suggest that a higher concentration of stem cells results in improved clinical outcomes.⁵² However, the optimal dose, frequency, timing, and number of injections remains unclear.⁵³

Different sources of stem cells are available and can be of adult (ASCs) or

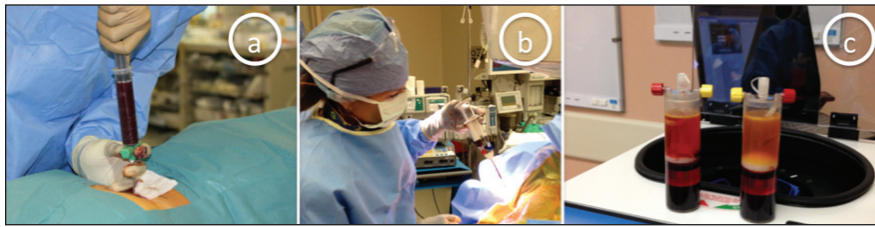

Figure 2: Bone marrow extraction procedure (A). Inoculation of the stem cells (B). Result after centrifugation of bone marrow aspirate (C).

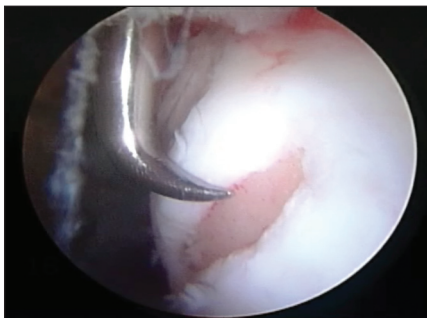


Figure 3: Arthroscopic image of the right hip showing microfracture over a cartilage defect.

embryonic (ESCs) origin.⁵⁴ Recently, induction of pluripotent stem cells (iPSCs)⁵⁵ has been suggested as another potential future source of stem cells. This comprises obtaining adult fibroblasts from the skin and genetically modifying them to become embryonic stem cells. Adult stem cells can be obtained from bone marrow, adipose tissue, and umbilical cord tissue. In contrast to ESCs, their use is not restricted by ethical concerns.⁵⁴ Cell sources for cartilage repair may vary in their effects and drawbacks. Adipose stem cells are autologous and have a minimally invasive harvesting, yet their chondrogenic capacity is reduced when compared with bone marrow-derived mesenchymal stem cells (BM-MSCs).⁵⁶ Although there is tremendous potential for stem cells, there are still many questions that need to be answered, such as the best cell type, best cell source, autologous vs allogeneic, and how to optimally stimulate the implanted cells.

The role of stem cells in cartilage regeneration has been suggested to be similar to the director of an orchestra. It is believed that stem cells will provide mes-

engers to the rest of the tissues, which will respond anabolically, increasing production. Recent studies have established that stem cells have the ability to localize and participate in the repair of damaged joint structures.⁵⁷

Currently, BM-MSCs are the preferred cell source because of their chondrogenic capacity and anti-inflammatory⁵⁸ and immunosuppressive properties.⁵⁹ They have been reported to be superior to other sources of stem cells.^{60,61} However, US Food and Drug Administration guidelines⁶² require that cells should be minimally manipulated and used within a short period of time. This explains the necessity of injecting BMAC as an optional stem cell treatment for patients with early OA in the United States.

The authors' institution is currently performing the injection of BMAC for the treatment of hip early OA with good clinical results (**Figure 2**). Patients normally respond rapidly during the first 2 weeks after injection. The authors believe this is part of the anti-inflammatory effect of BMAC. Patients then report improvement 1 month post-inoculation (unpublished data). No adverse effects have been reported. However, it has been suggested that a synovitis may occur, which would normally be observed as tenderness and pain of the hip joint for 48 to 72 hours. The authors advocate 1 injection, but a sequence of 2 to 3 injections is used in other institutions.

Davatchi et al⁶³ reported improved parameters after mesenchymal stem cell injection in walking time, stair climbing, patella crepitus, flexion contracture, and

VAS pain scores for the first 6 months; these parameters gradually began to deteriorate, but at 5 years they were still better than at baseline.

SURGICAL TECHNIQUES FOR FOCAL CHONDRAL LESIONS

Marrow Stimulation and Augmentation

Microfracture. The microfracture technique has been well described. Existing outcomes data in hip pathology are equivocal.⁴ Patient selection is the key factor to achieve good results. Indication parameters have been extrapolated from knee procedures: patients younger than 40 years, body mass index less than 30 kg/m², minimal OA or Tönnis score 0-1, and focal contained lesion size measuring less than 4 cm².⁶⁴ It is also important to understand that associated hip pathology, such as FAI, instability, or dysplasia, should be treated concomitantly to prevent future degeneration of the cartilage repair.

The goal of this procedure is to bring bone marrow cells and growth factors into the cartilage defect.⁴ Recent data suggest that microdrilling may be a better technique because it avoids damage to the subchondral plate (**Figure 3**).⁶⁵

Philippon et al⁹ reported a series of 9 revision hip arthroscopies after prior acetabular microfracture. Average time from index procedure to revision was 20 months. Overall percent fill of the defects was 91%. Byrd and Jones⁶⁶ performed 58 microfractures in grade IV chondral defects with healthy surrounding cartilage. Average improvement in modified Harris Hip Score was 20 points at a mean follow-up of 16 months. Domb et al⁶⁷ recently reported statistically significant clinical improvement in patient-reported outcome scores in 30 patients at a minimum of 2 years after receiving microfracture during arthroscopic hip surgery.

Microfracture and Augmentation.

The fibrocartilage fill that the microfracture produces has limited long-term benefit due to its inferior quality.⁶⁸ Therefore, biological augmentation implies that new

technology may achieve better outcomes. Recent studies suggest that augmentation with stem cells or BMAC at 6 weeks post-microfracture could improve cartilage regeneration.⁶⁹ In an equine study that evaluated microfracture alone vs microfracture augmented with 20×10^6 MSCs, it was suggested that the stem cell augmentation enhanced cartilage repair quality with increased aggrecan content and tissue firmness.⁷⁰

Autologous Matrix-Induced Chondrogenesis. Autologous matrix-induced chondrogenesis is a new approach in which microfracture is enhanced with the use of a type I/III collagen matrix (Chondro-Gide; Geistlich Pharma AG, Wolhusen, Switzerland).⁷¹ The advantages of this method are that it is a single-stage procedure that does not require harvesting, culture, and reimplanting of autologous cells and it can be performed arthroscopically.¹⁸ Scant evidence exists with other procedures validated for knee cartilage defects, such as BST-CarGel (Bio-Orthopaedics Division, Piramal Life Sciences, Laval, Quebec, Canada), which is an aqueous form of chitosan (glucosamine polysaccharide) mixed with fresh whole autologous blood, or BioCartilage (Arthrex, Naples, Florida), which consists of hypothermic dehydrated allograft cartilage micronized to particles of 100 to 300 μm mixed with whole blood and a fibrin glue allowing a stable blood clot.⁷²

Matrix-Induced Autologous Chondrocyte Implantation. Recently described for the hip, the matrix-induced autologous chondrocyte implantation (MACI) technique can be fully performed arthroscopically. The principle is to culture autologous cells onto a 3-dimensional biocompatible scaffold, which is then implanted into the defect.^{73,74} Basad et al⁷⁵ compared the MACI procedure with marrow-stimulation techniques at short-term follow-up (1 to 2 years) and found superior results with the MACI technique in the knee. Mancini and Fontana⁷⁶ compared clinical outcomes of MACI (n=26) and AMIC (n=31) for the

treatment of acetabular chondral defects (2 and 4 cm^2). They suggested that both procedures yielded comparable results. However, they concluded that due to its high sustainability and minimal invasiveness, the single-stage AMIC procedure can reduce total treatment time and minimize morbidity while providing the same beneficial effects as the 2-stage MACI intervention.

Matrix-Associated Stem Cell Transplantation. Similar to MACI, the matrix-associated stem cell transplantation (MAST) technique proposes culturing stem cells in a monolayer for 28 days. After 28 days of culture, the cells are transferred to the matrix (Chondro-Gide, Geistlich, Wolhusen, Switzerland) for 1 week with a non-differentiated medium, followed by a chondrogenic medium for 21 more days. The matrix can then be implanted arthroscopically in the area of the defect. An author (R.M.) reported his results in 15 patients treated with this technique. All patients had improved Harris Hip Scores at 2-year follow-up. No complications were reported. d-GEMRIC was performed in 4 of these patients with complete defect filling and integration with native cartilage (unpublished data) (**Figure 4**).

Fresh Osteochondral Allografts. Fresh osteochondral allografts are suitable for patients younger than 50 years with large cartilage defects (>2.5 cm).⁴ A benefit of this therapy is the possibility to treat large defects with a single-stage procedure. Moreover, the use of allograft provides the patient with hyaline cartilage as opposed to fibrocartilage.⁷⁷ Limitations include an open procedure (controlled hip dislocation) and nonweight bearing for up to 12 weeks postoperatively.⁷⁷

A prospective study⁷⁷ reported outcomes of 17 patients treated with fresh osteochondral allograft with a mean follow-up of 41.6 months. Mean Harris Hip Score was significantly better postoperatively, and 13 patients had fair to good outcomes. One patient required a repeat allograft, and 3 patients underwent hip replacement.⁷⁷ The authors concluded that fresh osteochondral

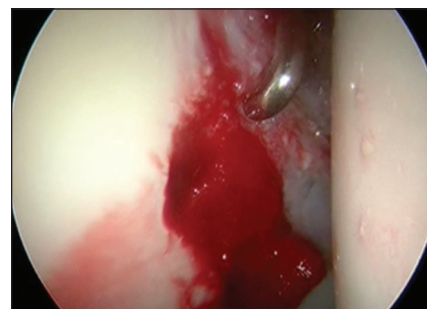


Figure 4: Arthroscopic image of the hip showing the stem cells seeded in a membrane in an acetabular chondral lesion.

allograft is a reasonable treatment option for hip cartilage defects in young patients.

Published Randomized Trials Comparing Treatments

A literature review was performed using the electronic databases PubMed and EMBASE from the inception of the databases until June 27, 2015. The search methodology (Boolean operators) used was the following: (“hip”[MeSH Terms] OR “hip”[All Fields]) AND (“cartilage”[MeSH Terms] OR “cartilage”[All Fields]) AND “randomized controlled trial”[Publication Type]. Two reviewers (J.C., C.P.-G.) independently reviewed the titles and abstracts to select relevant articles on hip cartilage treatments (**Table**).

Comparative outcomes between hip cartilage repair techniques are difficult to interpret because of heterogeneity between study groups. There are also concerns relating to potential conflicts of interest or bias in the literature. Of note, no surgical procedure study was a randomized, controlled trial. Clinically relevant Level I evidence studies are presented in the **Table**. Pavelka et al⁷⁸ reported no structure-modifying effect of glycosaminoglycans in OA of the hip in a 60-month follow-up study. Similarly, Rozendaal et al⁷⁹ reported that glycosaminoglycans was not significantly better than placebo in reducing symptoms and progression of hip OA. Qvistgaard et al⁸⁰ reported that corticosteroid seems to have a definite, albeit short-lived, effect in hip OA. How-

Table

Randomized, Controlled Trials of Hip Cartilage Treatments

Study	Treatment	Outcome Measurement Tool	Outcome	Follow-up, mo
Pavelka et al ⁷⁸	Glycosaminoglycan polysulphuric acid complex	JSW, LAI, pain on passive motion, and consumption of NSAIDs	No structure-modifying effect of glycosaminoglycan in OA of the hip. Radiographic progression of OA in hip OA lower than expected.	60
Makarowski et al ⁸¹	Valdecoxib vs naproxen vs placebo	WOMAC	Valdecoxib 5 and 10 mg doses were similar to naproxen and superior to placebo	3
Qvistgaard et al ⁸⁰	HA vs corticosteroid vs isotonic saline	Pain on walking, VAS	Patients treated with corticosteroids experienced significant improvement, with an effect size indicating a moderate clinical effect. Although a similar significant result following treatment with HA could not be shown, the effect size indicated a small clinical improvement.	1.5
Puopolo et al ⁸²	Etoricoxib vs ibuprofen	WOMAC + Pain Subscale + Physical Function Subscale and PGADS	Etoricoxib provides superior efficacy vs placebo and comparable clinical efficacy vs ibuprofen	3
Rozendaal et al ⁷⁹	Glucosamine sulfate vs placebo	Kellgren & Lawrence score, JSW, WOMAC	Glucosamine sulfate was not significantly better than placebo in reducing symptoms and progression of hip OA	24
Fernandes et al ⁸³	Supervised exercise (SE) + patient education (PE) vs PE alone	WOMAC	No significant difference in pain reduction over time between PE + SE vs PE alone	16
Conaghan et al ⁸⁴	Transdermal buprenorphine + oral paracetamol vs an oral codeine-paracetamol combination	Box scale-11 pain scale	Buprenorphine patches + oral paracetamol were noninferior to co-codamol tablets with respect to analgesic efficacy	3
Abbott et al ⁸⁵	Manual therapy, exercise therapy, or both	WOMAC, physical performance tests	Manual physiotherapy provided benefits over usual care. Exercise physiotherapy also provided physical performance benefits over usual care. There was no added benefit from a combination of the 2 therapies.	12

Abbreviations: HA, hyaluronic acid; JSW, baseline joint space width; LAI, Lequesne algofunctional index; NSAIDs, nonsteroidal anti-inflammatory drugs; OA, osteoarthritis; PGADS, patient global assessment of disease status; VAS, visual analog scale; WOMAC, Western Ontario and McMaster Universities Osteoarthritis Index.

ever, this study could not demonstrate a 3-month effect on hip OA using HA.

Other randomized, controlled trial data are shown in the **Table**. Studies of this nature, but with longer follow-up data, will hopefully guide future care in the field.

CONCLUSION

Treatment of hip cartilage disease is challenging, and there is no clear algorithm to address this entity. Biomarkers are arising as promising diagnostic tools because they could play a role in the early assess-

ment of the prearthritic joint and as a prognostic factor before and after treatment. A trend toward a less invasive biological treatment is appearing in the literature. With the growth of surgical skills in hip arthroscopy, cartilage restoration techniques are evolving in a fast and exponential manner. Mid- and long-term clinical results of these new techniques in the hip are still unknown.

REFERENCES

1. Bedi A, Kelly BT, Khanduja V. Arthroscopic hip preservation surgery: current concepts

and perspective. *Bone Joint J.* 2013; 95:10-19.

2. Claßen T1, Körsmeier K, Kamminga M, et al. Is early treatment of cam-type femoroacetabular impingement the key to avoiding associated full thickness isolated chondral defects? *Knee Surg Sports Traumatol Arthrosc.* doi: 10.1007/s00167-014-3332-7.
3. Karthikeyan S, Roberts S, Griffin D. Microfracture for acetabular chondral defects in patients with femoroacetabular impingement: results at second-look arthroscopic surgery. *Am J Sports Med.* 2012; 40(12):2725-2730.
4. El Bitar YF, Lindner D, Jackson TJ, Domb BG. Joint-preserving surgical options for management of chondral injuries of the hip. *J Am Acad Orthop Surg.* 2014; 22(1):46-56.

5. Bedi A, Kelly BT. Femoroacetabular impingement. *J Bone Joint Surg Am.* 2013; 95(1):82-92.
6. Novakofski KD, Berg LC, Bronzini I, et al. Joint-dependent response to impact and implications for post-traumatic osteoarthritis. *Osteoarthritis Cartilage.* 2015; 23(7):1130-1137.
7. Sutter R, Zanetti M, Pfirrmann CW. New developments in hip imaging. *Radiology.* 2012; 264(3):651-667.
8. Aprato A, Massè A, Faletti C, et al. Magnetic resonance arthrography for femoroacetabular impingement surgery: is it reliable? *J Orthop Traumatol.* 2013; 14(3):201-206.
9. Philippon MJ, Schenker ML, Briggs KK, Maxwell RB. Can microfracture produce repair tissue in acetabular chondral defects? *Arthroscopy.* 2008; 24(1):46-50.
10. Haviv B, Singh PJ, Takla A, O'Donnell J. Arthroscopic femoral osteochondroplasty for cam lesions with isolated acetabular chondral damage. *J Bone Joint Surg Br.* 2010; 92(5):629-633.
11. Byrd JWT, Jones KS. Osteoarthritis caused by an inverted acetabular labrum: radiographic diagnosis and arthroscopic treatment. *Arthroscopy.* 2002; 18(7):741-747.
12. Karthikeyan S, Roberts S, Griffin D. Microfracture for acetabular chondral defects in patients with femoroacetabular impingement: results at second-look arthroscopic surgery. *Am J Sports Med.* 2012; 40(12):2725-2730.
13. Byrd JWT, Jones KS. Arthroscopic femoro-plasty in the management of cam-type femoroacetabular impingement. *Clin Orthop Relat Res.* 2009; 467(3):739-746.
14. Stafford GH, Bunn JR, Villar RN. Arthroscopic repair of delaminated acetabular articular cartilage using fibrin adhesive: results at one to three years. *Hip Int.* 2011; 21(6):744-750.
15. Tzaveas AP, Villar RN. Arthroscopic repair of acetabular chondral delamination with fibrin adhesive. *Hip Int.* 2010; 20(1):115-119.
16. Akimau P, Bhosale A, Harrison PE, et al. Autologous chondrocyte implantation with bone grafting for osteochondral defect due to posttraumatic osteonecrosis of the hip: a case report. *Acta Orthop.* 2006; 77(2):333-336.
17. Fontana A, Bistolfi A, Crova M, Rosso F, Massazza G. Arthroscopic treatment of hip chondral defects: autologous chondrocyte transplantation versus simple debridement. A pilot study. *Arthroscopy.* 2012; 28(3):322-329.
18. Fontana A. A novel technique for treating cartilage defects in the hip: a fully arthroscopic approach to using autologous matrix-induced chondrogenesis. *Arthrosc Tech.* 2012; 1(1):E63-E68.
19. Sotereanos NG, DeMeo PJ, Hughes TB, Bargiotas K, Wohlrab D. Autogenous osteochondral transfer in the femoral head after osteonecrosis. *Orthopedics.* 2008; 31(2):177.
20. Girard J, Roumazielle T, Sakr M, Migaud H. Osteochondral mosaicplasty of the femoral head. *Hip Int.* 2011; 21(5):542-548.
21. Hart R, Janecek M, Visna P, Bucek P, Kocis J. Mosaicplasty for the treatment of femoral head defect after incorrect resorbable screw insertion. *Arthroscopy.* 2003; 19(10):E1-E5.
22. Evans KN, Providence BC. Case report: fresh-stored osteochondral allograft for treatment of osteochondritis dissecans the femoral head. *Clin Orthop Relat Res.* 2010; 468(2):613-618.
23. Krych AJ, Lorch DG, Kelly BT. Treatment of focal osteochondral defects of the acetabulum with osteochondral allograft transplantation. *Orthopedics.* 2011; 34(7):307-311.
24. Co C, Vickaryous MK, Koch TG. Membrane culture and reduced oxygen tension enhances cartilage matrix formation from equine cord blood mesenchymal stromal cells in vitro. *Osteoarthritis Cartilage.* 2014; 22(3):472-480.
25. Bedi A, Lynch EB, Sibilsy Enselman ER, et al. Elevation in circulating biomarkers of cartilage damage and inflammation in athletes with femoroacetabular impingement. *Am J Sports Med.* 2013; 41(11):2585-2590.
26. Clohisy JC, Dobson MA, Robison JF, et al. Radiographic structural abnormalities associated with premature, natural hip-joint failure. *J Bone Joint Surg Am.* 2011; 93(suppl 2):S3-S9.
27. Nepple JJ, Thomason KM, An TW, Harris-Hayes M, Clohisy JC. What is the utility of biomarkers for assessing the pathophysiology of hip osteoarthritis? A systematic review. *Clin Orthop Relat Res.* 2015; 473(5):1683-1701.
28. Rodda JW. Biomarkers consortium: osteoarthritis project. <http://www.fnih.org/what-we-do/current-research-programs/biomarkers-consortium-0a>. Accessed June 20, 2016.
29. Hsu WK, Mishra A, Rodeo SR, et al. Platelet-rich plasma in orthopaedic applications: evidence-based recommendations for treatment. *J Am Acad Orthop Surg.* 2013; 21(12):739-748.
30. Zhu Y, Yuan M, Meng HY, et al. Basic science and clinical application of platelet-rich plasma for cartilage defects and osteoarthritis: a review. *Osteoarthritis Cartilage.* 2013; 21(11):1627-1637.
31. Mifune Y, Matsumoto T, Takayama K, et al. The effect of platelet-rich plasma on the regenerative therapy of muscle derived stem cells for articular cartilage repair. *Osteoarthritis Cartilage.* 2013; 21(1):175-185.
32. Saito M, Takahashi KA, Arai Y, et al. Intra-articular administration of platelet-rich plasma with biodegradable gelatin hydrogel microspheres prevents osteoarthritis progression in the rabbit knee. *Clin Exp Rheumatol.* 2009; 27(2):201-207.
33. Abrams GD, Frank RM, Fortier LA, Cole BJ. Platelet-rich plasma for articular cartilage repair. *Sports Med Arthrosc.* 2013; 21(4):213-219.
34. Sanchez M, Guadilla J, Fiz N, Andia I. Ultrasound-guided platelet-rich plasma injections for the treatment of osteoarthritis of the hip. *Rheumatology (Oxford).* 2012; 51(1):144-150.
35. Rai MF, Sandell LJ. Regeneration of articular cartilage in healer and non-healer mice. *Matrix Biol.* 2014; 39:50-55.
36. Cavallo C, Filardo G, Mariani E, et al. Comparison of platelet-rich plasma formulations for cartilage healing: an in vitro study. *J Bone Joint Surg Am.* 2014; 96(5):423-429.
37. Filardo G, Kon E, Pereira Ruiz MT, et al. Platelet-rich plasma intra-articular injections for cartilage degeneration and osteoarthritis: single- versus double-spinning approach. *Knee Surg Sports Traumatol Arthrosc.* 2012; 20(10):2082-2091.
38. Kon E, Mandelbaum B, Buda R, et al. Platelet-rich plasma intra-articular injection versus hyaluronic acid viscosupplementation as treatments for cartilage pathology: from early degeneration to osteoarthritis. *Arthroscopy.* 2011; 27(11):1490-1501.
39. Campbell KA, Saltzman BM, Mascarenhas R, et al. Does intra-articular platelet-rich plasma injection provide clinically superior outcomes compared with other therapies in the treatment of knee osteoarthritis? A systematic review of overlapping meta-analyses. *Arthroscopy.* 2015; 31(11):2213-2221.
40. Calder PC. Marine omega-3 fatty acids and inflammatory processes: effects, mechanisms and clinical relevance. *Biochim Biophys Acta.* 2015; 1851(4):469-484.
41. Madden J, Shearman CP, Dunn RL, et al. Altered monocyte CD44 expression in peripheral arterial disease is corrected by fish oil supplementation. *Nutr Metab Cardiovasc Dis.* 2009; 19(4):247-252.
42. Curtis CL, Rees SG, Cramp J, et al. Effects of n-3 fatty acids on cartilage metabolism. *Proc Nutr Soc.* 2006; 65(4):434.
43. Kawakami Y, Matsuo K, Murata M, et al. Expression of angiotensin II receptor-1 in human articular chondrocytes. *Arthritis.* 2012; 2012:648537.
44. Lo GH, LaValley M, McAlindon T, Felson DT. Intra-articular hyaluronic acid in treatment of knee osteoarthritis: a meta-analysis. *JAMA.* 2003; 290(23):3115-3121.
45. Siegelman MH, DeGrendele HC, Estess P. Activation and interaction of CD44 and hyaluronan in immunological systems. *J Leukoc Biol.* 1999; 66(2):315-321.
46. Migliore A, Bizzi E, Herrero-Beaumont J, Petrella RJ, Raman R, Chevalier X. The discrepancy between recommendations and

- clinical practice for viscosupplementation in osteoarthritis: mind the gap! *Eur Rev Med Pharmacol Sci.* 2015; 19(7):1124-1129.
47. Migliore A, Granata M, Tormenta S, et al. Hip viscosupplementation under ultra-sound guidance reduces NSAID consumption in symptomatic hip osteoarthritis patients in a long follow-up: data from Italian registry. *Eur Rev Med Pharmacol Sci.* 2011; 15(1):25-34.
 48. Migliore A, Massafra U, Bizzi E, et al. Intra-articular injection of hyaluronic acid (MW 1,500-2,000 kDa; HyalOne) in symptomatic osteoarthritis of the hip: a prospective cohort study. *Arch Orthop Trauma Surg.* 2011; 131(12):1677-1685.
 49. Raeissadat SA, Rayegani SM, Hassanabadi H, et al. Knee osteoarthritis injection choices: platelet-rich plasma (PRP) versus hyaluronic acid. A one-year randomized clinical trial. *Clin Med Insights Arthritis Musculoskelet Disord.* 2015; 8:1-8.
 50. Martín DR, Cox NR, Hathcock TL, Niemeyer GP, Baker HJ. Isolation and characterization of multipotential mesenchymal stem cells from feline bone marrow. *Exp Hematol.* 2002; 30(8):879-886.
 51. Indrawattana N, Chen G, Tadokoro M, et al. Growth factor combination for chondrogenic induction from human mesenchymal stem cell. *Biochem Biophys Res Commun.* 2004; 320(3):914-919.
 52. Jo CH, Lee YG, Shin WH, et al. Intra-articular injection of mesenchymal stem cells for the treatment of osteoarthritis of the knee: a proof-of-concept clinical trial. *Stem Cells.* 2014; 32(5):1254-1266.
 53. Wolfstadt JJ, Cole BJ, Ogilvie-Harris DJ, Viswanathan S, Chahal J. Current concepts the role of mesenchymal stem cells in the management of knee osteoarthritis. *Sports Health.* 2015; 7(1):38-44.
 54. Cuervo B, Rubio M, Sopena J, et al. Hip osteoarthritis in dogs: a randomized study using mesenchymal stem cells from adipose tissue and plasma rich in growth factors. *Int J Mol Sci.* 2014; 15(8):13437-13460.
 55. Takahashi K, Yamanaka S. Induction of pluripotent stem cells from mouse embryonic and adult fibroblast cultures by defined factors. *Cell.* 2006; 126(4):663-676.
 56. Yanke AB, Chubinskaya S. The state of cartilage regeneration: current and future technologies. *Curr Rev Musculoskelet Med.* 2015; 8(1):1-8.
 57. Agung M, Ochi M, Yanada S, et al. Mobilization of bone marrow-derived mesenchymal stem cells into the injured tissues after intra-articular injection and their contribution to tissue regeneration. *Knee Surg Sports Traumatol Arthrosc.* 2006; 14(12):1307-1314.
 58. Lozito TP, Tuan RS. Mesenchymal stem cells inhibit both endogenous and exogenous MMPs via secreted TIMPs. *J Cell Physiol.* 2011; 226(2):385-396.
 59. Doorn J, Moll G, Le Blanc K, van Blitterswijk C, de Boer J. Therapeutic applications of mesenchymal stromal cells: paracrine effects and potential improvements. *Tissue Eng Part B Rev.* 2012; 18(2):101-115.
 60. Chen FH, Tuan RS. Mesenchymal stem cells in arthritic diseases. *Arthritis Res Ther.* 2008; 10(5):223.
 61. Somoza RA, Welter JF, Correa D, Caplan AI. Chondrogenic differentiation of mesenchymal stem cells: challenges and unfulfilled expectations. *Tissue Eng Part B Rev.* 2014; 20(6):596-608.
 62. Halme DG, Kessler DA. FDA regulation of stem-cell-based therapies. *N Engl J Med.* 2006; 355(16):1730-1735.
 63. Davatchi F, Sadeghi Abdollahi B, Mohyeddin M, Nikbin B. Mesenchymal stem cell therapy for knee osteoarthritis: 5 years follow-up of three patients. *Int J of Rheum Dis.* 2016; 19(3):219-225.
 64. Mithoefer K, McAdams T, Williams RJ, Kreuz PC, Mandelbaum BR. Clinical efficacy of the microfracture technique for articular cartilage repair in the knee: an evidence-based systematic analysis. *Am J Sports Med.* 2009; 37(10):2053-2063.
 65. Chen H, Sun J, Hoemann CD, et al. Drilling and microfracture lead to different bone structure and necrosis during bone-marrow stimulation for cartilage repair. *J Orthop Res.* 2009; 27(11):1432-1438.
 66. Byrd JW, Jones KS. Arthroscopic femoroplasty in the management of cam-type femoroacetabular impingement. *Clin Orthop Relat Res.* 2009; 467(3):739-746.
 67. Domb BG, El Bitar YF, Lindner D, Jackson TJ, Stake CE. Arthroscopic hip surgery with a microfracture procedure of the hip: clinical outcomes with two-year follow-up. *Hip Int.* 2014; 24(5):448-456.
 68. Goyal D, Keyhani S, Lee EH, Hui JH. Evidence-based status of microfracture technique: a systematic review of level I and II studies. *Arthroscopy.* 2013; 29(9):1579-1588.
 69. Strauss EJ, Barker JU, Kercher JS, Cole BJ, Mithoefer K. Augmentation strategies following the microfracture technique for repair of focal chondral defects. *Cartilage.* 2010; 1(2):145-152.
 70. McIlwraith CW, Frisbie DD, Rodkey WG, et al. Evaluation of intra-articular mesenchymal stem cells to augment healing of microfractured chondral defects. *Arthroscopy.* 2011; 27(11):1552-1561.
 71. Benthien JP, Behrens P. Autologous matrix-induced chondrogenesis (AMIC): a one-step procedure for retropatellar articular resurfacing. *Acta Orthop Belg.* 2010; 76(2):260-263.
 72. Tey M, Mas J, Pelfort X, Monllau JC. Arthroscopic treatment of hip chondral defects with bone marrow stimulation and BST-CarGel. *Arthrosc Tech.* 2015; 4(1):E29-E33.
 73. Basad E, Wissing FR, Fehrenbach P, Rickert M, Steinmeyer J, Ishaque B. Matrix-induced autologous chondrocyte implantation (MACI) in the knee: clinical outcomes and challenges. *Knee Surg Sports Traumatol Arthrosc.* 2015; 23(12):3729-3735.
 74. Fontana A. A novel technique for treating cartilage defects in the hip: a fully arthroscopic approach to using autologous matrix-induced chondrogenesis. *Arthrosc Tech.* 2012; 1(1):E63-E68.
 75. Basad E, Ishaque B, Bachmann G, Sturz H, Steinmeyer J. Matrix-induced autologous chondrocyte implantation versus microfracture in the treatment of cartilage defects of the knee: a 2-year randomised study. *Knee Surg Sports Traumatol Arthrosc.* 2010; 18(4):519-527.
 76. Mancini D, Fontana A. Five-year results of arthroscopic techniques for the treatment of acetabular chondral lesions in femoroacetabular impingement. *Int Orthop.* 2014; 38(10):2057-2064.
 77. Khanna V, Tushinski DM, Drexler M, et al. Cartilage restoration of the hip using fresh osteochondral allograft: resurfacing the potholes. *Bone Joint J.* 2014; 96(11)(suppl A):S11-S16.
 78. Pavelka K, Gatterova J, Gollerova V, Urbanova Z, Sedlackova M, Altman RD. A 5-year randomized controlled, double-blind study of glycosaminoglycan polysulphuric acid complex (Rumalon) as a structure modifying therapy in osteoarthritis of the hip and knee. *Osteoarthritis Cartilage.* 2000; 8(5):335-342.
 79. Rozendaal RM, Uitterlinden EJ, van Osch GJ, et al. Effect of glucosamine sulphate on joint space narrowing, pain and function in patients with hip osteoarthritis; subgroup analyses of a randomized controlled trial. *Osteoarthritis Cartilage.* 2009; 17(4):427-432.
 80. Qvistgaard E, Christensen R, Torp-Pedersen S, Bliddal H. Intra-articular treatment of hip osteoarthritis: a randomized trial of hyaluronic acid, corticosteroid, and isotonic saline. *Osteoarthritis Cartilage.* 2006; 14(2):163-170.
 81. Makarowski W, Zhao WW, Bevirt T, Recker DP. Efficacy and safety of the COX-2 specific inhibitor valdecoxib in the management of osteoarthritis of the hip: a randomized, double-blind, placebo-controlled comparison with naproxen. *Osteoarthritis Cartilage.* 2002; 10:290-296.
 82. Puopolo A, Boice JA, Fidelholtz JL, et al. A randomized placebo-controlled trial comparing the efficacy of etoricoxib 30 mg and ibuprofen 2400 mg for the treatment of patients with osteoarthritis. *Osteoarthritis Cartilage.* 2007; 15:1348-1356.
 83. Fernandes L, Storheim K, Sandvik L, Nor-

- dsletten L, Risberg MA. Efficacy of patient education and supervised exercise vs patient education alone in patients with hip osteoarthritis: a single blind randomized clinical trial. *Osteoarthritis Cartilage*. 2010; 18:1237-1243.
84. Conaghan PG, O'Brien CM, Wilson M, Schofield JP. Transdermal buprenorphine plus oral paracetamol vs an oral codeine-paracetamol combination for osteoarthritis of hip and/or knee: a randomised trial. *Osteoarthritis Cartilage*. 2011; 19:930-938.
85. Abbott JH, Robertson MC, Chapple C, et al. Manual therapy, exercise therapy, or both, in addition to usual care, for osteoarthritis of the hip or knee: a randomized controlled trial. 1. Clinical effectiveness. *Osteoarthritis Cartilage*. 2013; 21:525-534.