



Osteochondral Allograft Transplants for Large Trochlear Defects

Mark E. Cinque, B.S., M.S., Nicholas I. Kennedy, M.D., Gilbert Moatshe, M.D., Gustavo Vinagre, M.D., Jorge Chahla, M.D., Ph.D., Zaamin B. Hussain, B.A., and Robert F. LaPrade, M.D., Ph.D.

Abstract: Focal articular cartilage injuries in the knee are common and can cause severe morbidity and reduced function. The articular cartilage is avascular and has limited ability to heal, and hence, patients with cartilage injuries have increased risk of progressing to osteoarthritis. Most of the cartilage injuries are located on the femoral condyles. Engaging focal cartilage injuries involving the trochlea are challenging because of the morbidity caused by these injuries and the limited treatment options. Osteochondral allograft transplantation is emerging as a promising treatment for full-thickness articular cartilage defects. Recent studies have reported high success rates with the use of osteochondral allografts. This article reports our technique of osteochondral allograft transplantation for the treatment of a focal full-thickness defect of the trochlea.

Symptomatic localized articular chondral lesions of the knee are a common and disabling problem, particularly in young, high-demand patients.¹ Large studies looking at consecutive knees that underwent arthroscopy have found chondral lesions to be present 60% to 63% of the time,²⁻⁴ regardless of the surgical indications. Chondral lesions of the patellofemoral joint were found to be particularly common. Lesions located on the patella specifically have been noted in 11% to 37.5% of cases of chondral lesions^{2,4}; however, those involving the trochlea specifically are relatively rare, accounting for only 6% to 8%. Chondral lesions of the patellofemoral joint can arise

because of an acute trauma or because of abnormal biomechanics and joint contact forces.

Articular cartilage lesions have limited ability for self-healing because of their avascular nature.^{5,6} This makes treatment of these lesions particularly challenging, especially those localized to the patellofemoral joint, which undergoes constant exposure to contact forces from biomechanical requirements such as involvement in the extensor mechanism. There are a few different options for medium-sized chondral lesions (1-4 cm²), including microfracture, autologous chondrocyte implantation, particulated juvenile cartilage allograft, and osteochondral autograft transfer. These treatment options have shown promising results in medium-sized lesions measuring 1 to 4 cm².⁷⁻⁹

Larger lesions measuring greater than 4 cm² have relatively few options because regenerative techniques have been shown to have mixed results. Although chondrocyte transfer has been reported to be effective in treating some larger lesions, it generally involves a much longer recovery period when compared with fresh osteochondral allograft. The main treatment for lesions of this size would be either an osteochondral allograft or patellofemoral arthroplasty. Arthroplasty, however, is not the best option because many of these patients are younger and active and preservation of the native cartilage and bone is preferred. Although there is not a wealth of literature on long-term outcomes after the use of osteochondral allografts for large trochlear lesions, recent studies have reported promising

From the Steadman Philippon Research Institute (M.E.C., N.I.K., G.M., G.V., J.C., Z.B.H.); The Steadman Clinic (R.F.L.), Vail, Colorado, U.S.A.; and Oslo University Hospital (G.M.), Oslo, Norway.

The authors report the following potential conflict of interest or source of funding: R.F.L. receives support from the following: Institution provided support by Arthrex, Ossur, Siemens, and Smith & Nephew. Arthrex; Smith & Nephew; Ossur; Health East, Norway; NIH R-13 grant for biologics. Full ICMJE author disclosure forms are available for this article online, as supplementary material.

Received March 9, 2017; accepted June 22, 2017.

Address correspondence to Robert F. LaPrade, M.D., Ph.D., Steadman Philippon Research Institute, The Steadman Clinic, 181 W Meadow Dr, Ste 400, Vail, CO 81657, U.S.A. E-mail: drlaprade@sprivail.org

© 2017 by the Arthroscopy Association of North America. Published by Elsevier. This is an open access article under the CC BY-NC-ND license (<http://creativecommons.org/licenses/by-nc-nd/4.0/>).

2212-6287/17316

<http://dx.doi.org/10.1016/j.eats.2017.06.027>

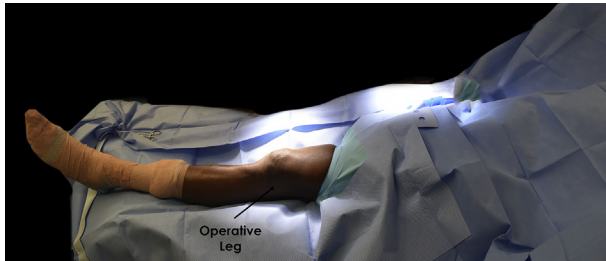


Fig 1. Patient positioning. The operative (left) leg is prepared and draped in sterile fashion. Coban (3M Company) is wrapped around the calf and extended distally around the patient's left foot. The surgeon should ensure that sufficient work space is exposed around the patient's knee.

results.^{10,11} Advantages compared with other techniques include the following: It is a 1-stage procedure, there is no donor-site comorbidity, the graft is designed according to the shape of the defect with a similar load area between the donor and the host, and the procedure can be combined with additional procedures. The main disadvantages are the risk of immunologic reactions and disease transmission. The purpose of this Technical Note is to describe a reproducible surgical technique for addressing large chondral defects of the trochlea that allows for preservation of most of the patient's native cartilage and bone and allows for a quicker recovery than some regeneration techniques.

Surgical Technique

Patient Positioning and Anesthesia

The patient is placed in the supine position on the operating table, and general anesthesia is used for induction (Fig 1). A well-padded high-thigh tourniquet is subsequently placed on the operative leg, and a bump is placed under the knee so that it rests at approximately 30° of flexion. The contralateral leg is secured to the table in full extension with a pneumatic compression device to help prevent deep vein thrombosis.

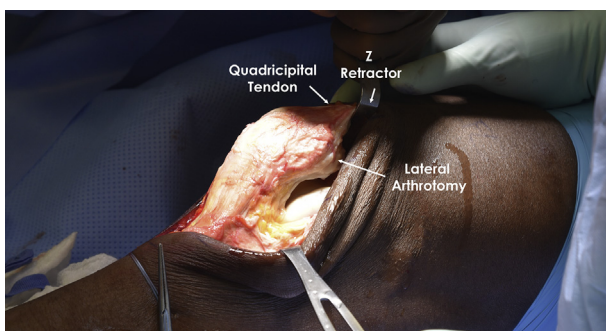


Fig 2. An approach through a lateral parapatellar arthrotomy is used in this case. Retractors are used on both the medial and lateral sides of the wound in the left knee to enable better access to the lateral-sided trochlear defect.

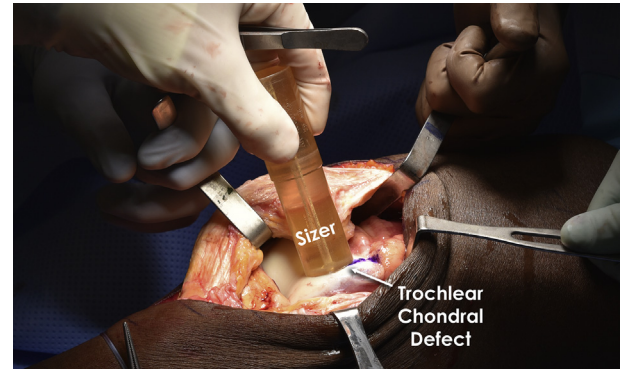


Fig 3. Once the defect has been properly exposed, identified, and marked with a surgical pen in the left knee, a cannulated sizer is used to ensure proper sizing of the osteochondral allograft.

Osteochondral Allograft Transplantation

A medial or lateral parapatellar arthrotomy (Fig 2) is performed (Video 1), depending on the location of the defect. The defect should be identified and undergo template creation with a sizer (Fig 3). Next, the defect is demarcated with a surgical pen. A guide pin is placed in the center of the defect, and the cannulated sizer is introduced again to ensure that all the defect will be covered by the graft. A circumferential mark around the cylinder is created, and the sizer is removed. A reference mark is placed at the superior 12-o'clock position. At this point, the sizer is used to measure the harvest area on the fresh (15-28 days after harvesting) osteochondral allograft (JRF Ortho, Centennial, CO) (Fig 4). This is performed before any further steps at the trochlear defect site to ensure the donor graft is large enough to completely cover the defect.

The edges of the defect are scored with the recipient harvester. The defect is then reamed until bleeding healthy bone is encountered (Fig 5), with care taken not to exceed a maximum of 7 to 8 mm of overall depth. This can be achieved by frequently checking the calibrated coring reamer (Arthrex, Naples, FL), along

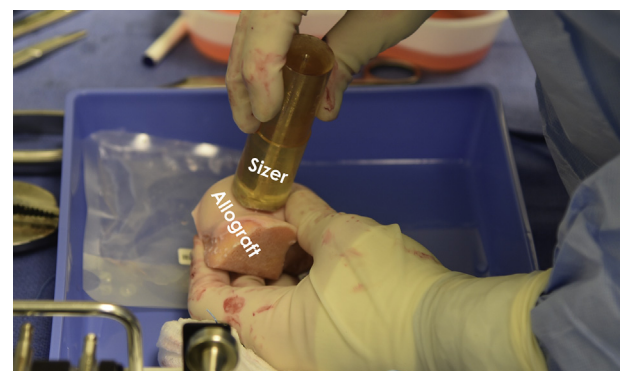


Fig 4. The same sizer that was used to measure the size of the trochlear defect is used on the allograft to ensure the graft is large enough.

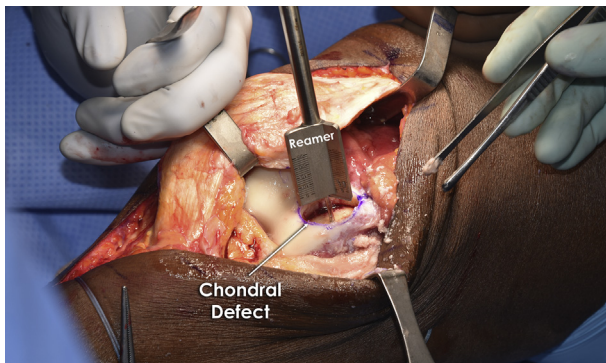


Fig 5. A guide pin is placed in the left knee through the center of the sizer, and the sizer is removed and replaced by a reamer. The chondral defect is reamed to the depth at which bleeding healthy subchondral bone is encountered. During reaming, the area should be copiously irrigated to ensure overheating does not occur.

with a final measurement. During reaming, a copious amount of irrigation fluid at room temperature is used to avoid heat necrosis of the surrounding articular cartilage and subchondral bone. The recipient site is then dilated with a smooth cylinder (Arthrex) (Fig 6) several times to ensure the donor plug can be inserted without the need to apply too much pressure. To accomplish a perfect fit between the donor graft and the host socket, a compass reference is created on the prepared defect and measures are taken from each main coordinate (north, south, east, and west). These measurements will be used later, at the time of graft trimming.

Next, the corresponding area on the allograft is outlined, by use of the sizer that had previously been used to measure the trochlear defect, with methylene blue to match the dimensions of the patient's knee defect. Of note, the area to be replaced should match the area of the donor site. The donor condyle is then secured within an allograft workstation (Arthrex) to ensure precision during harvest. The osteochondral donor plug

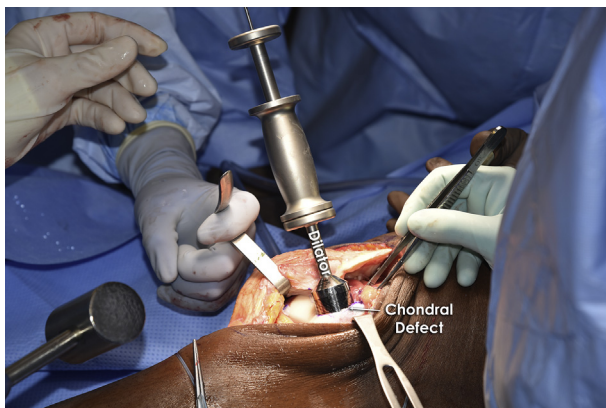


Fig 6. A dilator is used on the trochlear defect in the left knee repeatedly to facilitate implantation of the donor osteochondral allograft.

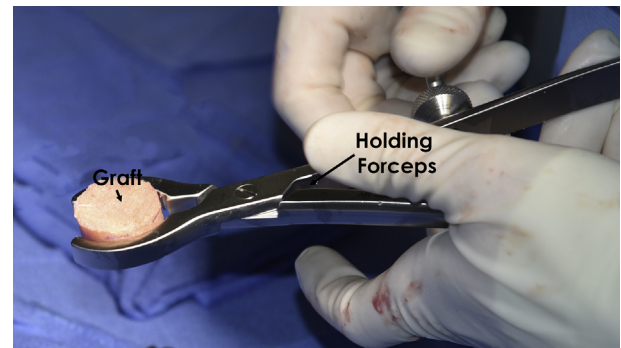


Fig 7. Holding forceps are used to grasp the graft while the graft is trimmed to fit the exact depth dimensions of the patient's now-reamed chondral defect. Care should be taken to ensure the measurements are correct before this step.

is harvested from the allograft with a coring reamer while a copious amount of irrigation is used to prevent heat necrosis. The subchondral bone of the donor plug is then trimmed according to previous measurements to match the corresponding depths of the host location with the use of holding forceps, and the surfaces are smoothed with a rasp (Fig 7). The depth of the recipient site and donor plug is measured several times to make sure there are no areas that will be too prominent.

Before implantation of the donor bone plug, the subchondral bone is subjected to pulse lavage (Arthrex) with triple antibiotic solution to eradicate any remaining bone marrow elements to minimize the chance of immune reaction. The bone plug is then gently press fitted into the socket to match the exact height of the surrounding articular cartilage (Fig 8). Pearls and pitfalls of our technique are displayed in Table 1, and advantages and disadvantages of this procedure are listed in Table 2.

Postoperative Rehabilitation

The patient should remain non-weight bearing for the first 8 weeks. A supervised rehabilitation program

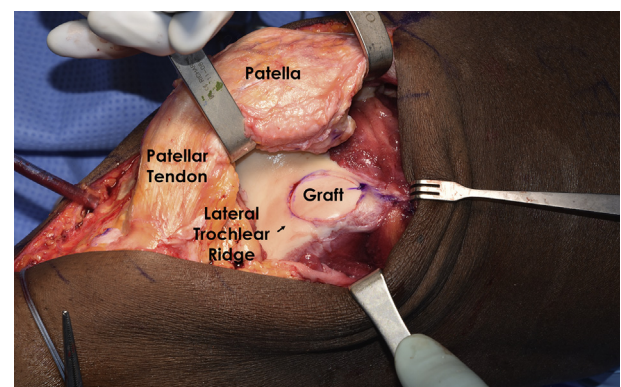


Fig 8. The graft is gently press fitted into the patient's trochlear defect in the left knee. The graft should fit the defect without any edges being significantly depressed or proud.

Table 1. Pearls and Pitfalls of Trochlear Osteochondral Allograft Transfer Procedure

Pearls	
Use a sizer to measure the harvest area on the fresh osteochondral allograft to ensure the donor graft is large enough to completely cover the defect.	
The osteochondral donor plug is harvested from the allograft with the use of a coring reamer while a copious amount of irrigation is used to prevent heat necrosis.	
A guide pin or other device may be used to microfracture the recipient site to create a bleeding surface and maximize healing potential.	
Pitfalls	
Using an osteochondral allograft >28 d from harvest	
Failing to hand ream the recipient site to make minor depth adjustments	
Failing to irrigate the graft to remove antigenic material	

should start immediately postoperatively. Quadriceps exercises and straight-leg raises with the patient wearing a knee immobilizer should be performed 4 times daily. For the first 8 weeks, the patient should use a continuous passive motion machine at a minimum time interval of 2 hours for a minimum of 10 hours per day. Low-impact activities are recommended for the first 12 months to allow complete healing and incorporation of the graft. All patients are advised to perform low-impact activities and avoid high-impact activities as much as possible after this period.

Discussion

A stepwise technique for the application of an osteochondral allograft (OCA) for a trochlear chondral defect has been described in this Technical Note. Several recent studies have reported on the indications and techniques for using OCAs for chondral defects throughout the knee. The advantages of using the described OCA technique is that it allows chondral defects to be immediately filled with mature articular cartilage.^{12,13} Allograft tissue use also avoids the donor-site morbidity associated with

Table 2. Advantages and Disadvantages of Trochlear Osteochondral Allograft Transfer Procedure

Advantages	
No donor-site morbidity	
Use of mature hyaline cartilage	
Ability to treat large chondral defects	
Single-stage procedure	
Harvesting from matching donor and matching trochlear site to create smooth contour of recipient site	
Disadvantages	
Technically demanding on trochlea	
Expensive	
Lack of availability	
Must use fresh allograft (15-28 d) for maximum chondrocyte viability	
Not meant for partial-thickness lesions	

autograft harvest. Furthermore, because allografts are acellular, they are immunologically inert and thereby unlikely to be rejected by the host tissue.¹⁴ In this regard, histologic analysis of OCA has shown high survivorship of the transplanted hyaline cartilage.¹² More extended survivorship analysis of these grafts has shown graft survivorship rates to be 95% at 5 years, 85% at 10 years, and 74% at 15 years.¹⁵ Moreover, Levy et al.¹⁶ evaluated the durability of OCA to the femoral condyles at 15 years' follow-up and reported a survivorship rate of 82%.

These encouraging molecular and graft survivorship findings of OCA procedures have also been shown to yield clinically significant results. In this regard, OCA procedures have been reported to produce a subjective improvement in pain in 74% to 85% of patients at midterm follow-up.^{15,16} Furthermore, LaPrade et al.¹ followed up 23 patients for 3 years and showed improvements in Cincinnati Knee Scores and International Knee Documentation Committee scores from 52 to 68 ($P < .03$) after transplantation. In addition, they reported graft incorporation in 22 of 23 patients (96%). McCulloch et al.¹⁷ also reported significant improvements in all subjective outcome scores in 88% of patients (22 of 25 patients) at 35 months' follow-up (range, 24-67 months).

Given that OCA is indicated for younger patients with large chondral defects and that these patients often desire to return to sport (RTS), the RTS level is an important consideration. Krych et al.¹⁸ reported on 43 competitive athletes with a mean 7.25-cm² defect size. They reported that 79% of athletes could return to their preinjury level of sport whereas 88% of patients achieved a limited RTS rate. An important finding was that factors that were negatively correlated with RTS were symptoms for greater than 12 months and patients older than 25 years.

Although the body of literature supporting the use of OCA for chondral defects has grown with continued promising results, further clinical studies are needed. We recommend our described transplant technique using an osteochondral allograft for the treatment of osteochondral defects of the trochlea. We encourage further studies to assess outcomes and return to activity after our surgical technique.

References

1. LaPrade RF, Botker J, Herzog M, Agel J. Refrigerated osteoarticular allografts to treat articular cartilage defects of the femoral condyles. A prospective outcomes study. *J Bone Joint Surg Am* 2009;91:805-811.
2. Curl WW, Krome J, Gordon ES, Rushing J, Smith BP, Poehling GG. Cartilage injuries: A review of 31,516 knee arthroscopies. *Arthroscopy* 1997;13:456-460.
3. Hjelle K, Solheim E, Strand T, Muri R, Brittberg M. Articular cartilage defects in 1,000 knee arthroscopies. *Arthroscopy* 2002;18:730-734.

4. Widuchowski W, Widuchowski J, Trzaska T. Articular cartilage defects: Study of 25,124 knee arthroscopies. *Knee* 2007;14:177-182.
5. Felson DT, Zhang Y, Hannan MT, et al. The incidence and natural history of knee osteoarthritis in the elderly. The Framingham Osteoarthritis Study. *Arthritis Rheum* 1995;38:1500-1505.
6. Mankin HJ. The response of articular cartilage to mechanical injury. *J Bone Joint Surg Am* 1982;64:460-466.
7. Alparslan B, Ozkan I, Acar U, Cullu E, Savk SO. The microfracture technique in the treatment of full-thickness chondral lesions of the knee. *Acta Orthop Traumatol Turc* 2007;41:62-69 (suppl 2) [in Turkish].
8. Filardo G, Kon E, Perdisa F, Balboni F, Marcacci M. Autologous osteochondral transplantation for the treatment of knee lesions: Results and limitations at two years' follow-up. *Int Orthop* 2014;38:1905-1912.
9. Mandelbaum B, Browne JE, Fu F, et al. Treatment outcomes of autologous chondrocyte implantation for full-thickness articular cartilage defects of the trochlea. *Am J Sports Med* 2007;35:915-921.
10. Jamali AA, Emmerson BC, Chung C, Convery FR, Bugbee WD. Fresh osteochondral allografts: Results in the patellofemoral joint. *Clin Orthop Relat Res* 2005;(437):176-185.
11. Cameron JI, Pulido PA, McCauley JC, Bugbee WD. Osteochondral allograft transplantation of the femoral trochlea. *Am J Sports Med* 2016;44:633-638.
12. Hangody L, Kish G, Karpati Z, Szerb I, Udvarhelyi I. Arthroscopic autogenous osteochondral mosaicplasty for the treatment of femoral condylar articular defects. A preliminary report. *Knee Surg Sports Traumatol Arthrosc* 1997;5:262-267.
13. Matsusue Y, Yamamuro T, Hama H. Arthroscopic multiple osteochondral transplantation to the chondral defect in the knee associated with anterior cruciate ligament disruption. *Arthroscopy* 1993;9:318-321.
14. Arnoczky SP. The biology of allograft incorporation. *J Knee Surg* 2006;19:207-214.
15. Gross AE, Kim W, Las Heras F, Backstein D, Safir O, Pritzker KPH. Fresh osteochondral allografts for post-traumatic knee defects: Long-term followup. *Clin Orthop Relat Res* 2008;466:1863-1870.
16. Levy YD, Görtz S, Pulido PA, McCauley JC, Bugbee WD. Do fresh osteochondral allografts successfully treat femoral condyle lesions? *Clin Orthop Relat Res* 2013;471:231-237.
17. McCulloch PC, Kang RW, Sobhy MH, Hayden JK, Cole BJ. Prospective evaluation of prolonged fresh osteochondral allograft transplantation of the femoral condyle: Minimum 2-year follow-up. *Am J Sports Med* 2007;35:411-420.
18. Krych AJ, Pareek A, King AH, Johnson NR, Stuart MJ, Williams RJ III. Return to sport after the surgical management of articular cartilage lesions in the knee: A meta-analysis. *Knee Surg Sports Traumatol Arthrosc*. August 18, 2016 [Epub ahead of print.]