

# Comparable Outcomes After Bucket-Handle Meniscal Repair and Vertical Meniscal Repair Can Be Achieved at a Minimum 2 Years' Follow-up

Gilbert Moatshe,<sup>\*†‡</sup> MD, Mark E. Cinque,<sup>\*</sup> MS, BS, Jonathan A. Godin,<sup>\*</sup> MD, MBA, Alexander R. Vap,<sup>§</sup> MD, Jorge Chahla,<sup>\*</sup> MD, PhD, and Robert F. LaPrade,<sup>\*||¶</sup> MD, PhD  
*Investigation performed at the Steadman Philippon Research Institute, Vail, Colorado, USA*

---

**Background:** Meniscal tears can lead to significant pain and disability, necessitating surgical treatment. Nondisplaced vertical tears are usually smaller in size and can be repaired in most cases; however, bucket-handle tears are usually larger and displaced, and the repair of these tears can be challenging.

**Purpose/Hypothesis:** The purpose was to report the outcomes after inside-out vertical mattress suture meniscal repair of bucket-handle tears and to compare these outcomes with those of patients who underwent repair of nondisplaced vertical meniscal tears with a minimum of 2 years' follow-up. The hypothesis was that the outcomes of bucket-handle tear repair would be comparable with those of nondisplaced vertical meniscal tear repair.

**Study Design:** Cohort study; Level of evidence, 3.

**Methods:** Patients who underwent inside-out repair of a bucket-handle meniscal tear or a nondisplaced vertical meniscal tear with a minimum 2 years' follow-up were included in this study. Patients were excluded if they had a diagnosis of a meniscal root tear, underwent a concomitant procedure for a chondral injury, or underwent previous surgical treatment of the same meniscus. Subjective questionnaires were administered preoperatively and postoperatively, including the Lysholm score, the Western Ontario and McMaster Universities Osteoarthritis Index (WOMAC), the Short Form-12 (SF-12) physical component summary (PCS) and mental component summary (MCS), the Tegner activity scale, and patient satisfaction.

**Results:** Thirty-two patients underwent repair for vertical meniscal tears (mean, 7 sutures), while 38 patients underwent repair for bucket-handle meniscal tears (mean, 11 sutures), with a mean follow-up of 3.1 years (range, 2-6 years). There were no significant differences in the preoperative outcome scores between the 2 groups. Significant improvements in patient-reported outcome scores from preoperatively to postoperatively were found in both groups. A direct comparison of the bucket-handle tear group to the vertical tear group did not exhibit significantly different SF-12 PCS scores (54.0 vs 51.6, respectively;  $P = .244$ ), SF-12 MCS scores (55.3 vs 52.5, respectively;  $P = .165$ ), WOMAC scores (8.1 vs 9.0, respectively;  $P = .729$ ), Lysholm scores (84.6 vs 80.8, respectively;  $P = .276$ ), Tegner scores (5.5 vs 5.5, respectively;  $P = .970$ ), and patient satisfaction scores (7.4 vs 7.7, respectively;  $P = .570$ ). Additionally, a comparison of acute and chronic bucket-handle tears demonstrated no significant difference in outcome scores.

**Conclusion:** The repair of bucket-handle meniscal tears with multiple vertical mattress sutures using an inside-out technique yielded improved results and low failure rates, comparable with outcomes after repair of nondisplaced vertical meniscal tears. The findings of this study support repairing bucket-handle meniscal tears with multiple vertical mattress sutures when possible.

**Keywords:** meniscal repair; bucket-handle meniscal tear; clinical outcomes; vertical meniscal tear

---

A meniscal tear is the most common injury seen in patients undergoing knee arthroscopic surgery in the United States.<sup>11</sup> Bucket-handle meniscal tears are reported to account for up to 10% of all meniscal tears.<sup>18</sup> These tears constitute a special subset of meniscal tears that present a unique challenge to surgeons because of their complexity,

specifically the bigger size and displacement of a considerably large fragment. In contrast, nondisplaced vertical tears, which are more common, are usually smaller in size and can be repaired in most cases.

Nondisplaced vertical meniscal tears are often treated operatively with partial meniscectomy or repair depending on the age of the patient, the zone and size of the tear, and the physical demands of the patient. Bucket-handle tears are typically treated with either meniscectomy or repair depending on the tissue quality, patient age, and physical demands. The repair of nondisplaced meniscal tears

improves clinical outcomes of pain, catching, and knee function. When comparing the all-inside technique with the inside-out technique, no significant differences in clinical or anatomic failure rates (clinical failure: 11% vs 10%, respectively; anatomic failure: 13% vs 16%, respectively) have been found.<sup>10</sup> Complication rates are 4.6% for the all-inside technique versus 5.1% for the inside-out technique.<sup>10</sup> The clinical healing rates for red-white zone repair are reported to be 83%. Patient age, sex, chronicity, compartment involved (medial vs lateral), and concurrent anterior cruciate ligament (ACL) reconstruction do not influence healing rates.<sup>2</sup> Historically, bucket-handle tears were treated with partial meniscectomy because of the complexity of the tears. Shelbourne and Carr<sup>23</sup> reported no difference between repair of bucket-handle tears and partial meniscectomy.

The importance of preserving meniscal tissue is being increasingly recognized, particularly regarding its role in contact forces, knee stability, and preventing degenerative changes.<sup>9,13,19,20</sup> The degree of meniscal deficiency is correlated to joint contact pressures.<sup>3,14,15</sup> Meniscectomy in the setting of a bucket-handle tear will result in significant meniscal loss and increased joint loading because of the size of the torn meniscus that is resected.<sup>26</sup> Furthermore, meniscectomy or partial meniscectomy in the setting of ACL deficiency or ACL reconstruction will lead to chronic joint instability that has been reported to increase the risk of osteoarthritis. Therefore, a timely and accurate diagnosis and repair of bucket-handle tears are crucial to avoid the cascade of degenerative processes resulting from the absence of meniscal tissue.<sup>13</sup> Although satisfactory outcomes have been reported after bucket-handle meniscal repair,<sup>1,8,23</sup> to our knowledge, no previous study has compared the outcomes after bucket-handle meniscal repair with nondisplaced vertical meniscal repair. The purpose of this study was to report outcomes of surgical reduction and inside-out meniscal repair of bucket-handle tears and to compare those outcomes to patients who underwent repair of vertical meniscal tears with an inside-out technique with a minimum of 2-year follow-up. The hypothesis was that bucket-handle repair outcomes would be comparable with outcomes after vertical meniscal repair.

## METHODS

### Study Design

This was an institutional review board–approved study (#2002-03). All patient data were queried from a prospectively collected data registry. Patients aged  $\geq 16$  years (with

radiographically closed physes) who underwent treatment of a bucket-handle meniscal tear by a single surgeon (R.F.L.) between 2010 and 2014 were included. The primary study group included patients who underwent arthroscopic inside-out repair for a bucket-handle meniscal tear. The comparison group included patients with vertical meniscal tears treated with inside-out repair.<sup>16</sup> Patients were excluded from this study if they had a meniscal root tear, underwent a concomitant procedure for a chondral injury, or underwent previous surgical treatment of the same meniscus. In the present study, 6 weeks was the cutoff point between acute and chronic.

### Patient Demographics and Functional Assessment

Demographic data were documented at the initial clinical evaluation. Patients were categorized into 2 groups: arthroscopic inside-out repair of bucket-handle tears and inside-out repair of vertical meniscal tears. All patients in the bucket-handle tear group were found to have a history of difficulty moving their knee into full extension. Patients in both groups were found to have a history of catching and joint line tenderness. After an evaluation of each patient's presentation, patients in both the vertical and bucket-handle tear groups underwent preoperative magnetic resonance imaging (MRI) confirming the tear type. Preoperatively, and at a minimum of 2 years after surgery, patients were administered a subjective questionnaire, which included the following clinical outcome measures: Lysholm score, Western Ontario and McMaster Universities Osteoarthritis Index (WOMAC), Short Form–12 (SF-12) physical component summary (PCS) and mental component summary (MCS), Tegner activity scale, and patient satisfaction with outcomes. Patient satisfaction was measured on a 1-to-10 scale, with 1 being very unsatisfied and 10 being very satisfied. Concurrent intra-articular ligament reconstruction was also documented.

### Surgical Technique: Inside-Out Meniscal Tear Repair

Standard medial and lateral arthroscopic portals were created adjacent to the patellar tendon, and diagnostic arthroscopic surgery was performed to assess for concurrent injuries.<sup>21</sup> Once the tear was identified, a meniscal rasp was utilized to lightly debride the tear edges. For medial tears, a vertical incision was centered over the joint line, and a dissection was made through the sartorius fascia. The interval anterior to the medial gastrocnemius was developed, and a retracting device was inserted to protect

\*Address correspondence to Robert F. LaPrade, MD, PhD, Steadman Philippon Research Institute, 181 West Meadow Drive, Suite 400, Vail, CO 81657, USA (email: drlaprade@sprivail.org).

\*Steadman Philippon Research Institute, Vail, Colorado, USA.

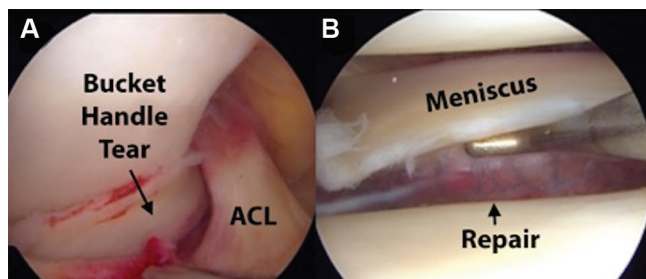
<sup>†</sup>Oslo University Hospital, University of Oslo, Oslo, Norway.

<sup>‡</sup>Oslo Sports Trauma Research Center, Norwegian School of Sport Sciences, Oslo, Norway.

<sup>§</sup>Department of Orthopaedic Surgery, Virginia Commonwealth University School of Medicine, Richmond, Virginia, USA.

<sup>||</sup>The Steadman Clinic, Vail, Colorado, USA.

One or more of the authors has declared the following potential conflict of interest or source of funding: R.F.L. receives royalties from Arthrex and Smith & Nephew; is a paid consultant for Arthrex, Ossur, and Smith & Nephew; and receives research support from Arthrex, Smith & Nephew, Ossur, and Linvatec.



**Figure 1.** Arthroscopic images showing (A) a bucket-handle tear before repair and (B) the meniscus after repair with multiple vertical mattress sutures.

the posterior structures and allow needle capture. For lateral tears, the incision was centered over the posterior aspect of the iliotibial band. The iliotibial band was then split, and the interval between the fibular collateral ligament and lateral gastrocnemius was developed and a retractor inserted. Dual meniscal repair needles loaded with 2-0 nonabsorbable suture (FiberWire; Arthrex) were utilized and passed through the meniscus using a mechanical insertion device (SharpShooter; Stryker) as previously described.<sup>4</sup> Vertical mattress sutures were placed above and/or below the meniscus and tied sequentially with the knee in 90° of flexion. The number of sutures needed depended on the size and complexity of the tear (Figure 1).

### Postoperative Rehabilitation Protocol

The postoperative rehabilitation protocol was dictated by the concurrent injuries. Nonweightbearing was prescribed for the first 6 weeks for isolated bucket-handle or vertical meniscal repair. Passive range of motion was restricted from 0° to 90° of flexion for the first 2 weeks and then progressed as tolerated by the patient. After this initial phase, partial protected weightbearing and cycling on a stationary bicycle were introduced. An unloader brace was utilized to protect the repair construct once the weightbearing phase commenced 4 months postoperatively. Deep squatting, leg lifting, and sitting cross-legged were prohibited for 4 months postoperatively. After 4 months, the patient was allowed to resume unlimited low-impact activities. Patients who underwent bucket-handle or vertical meniscal repair with concurrent ACL reconstruction were allowed to weight bear as tolerated and followed a standard postoperative ACL rehabilitation protocol.<sup>7</sup>

### Statistical Analysis

Assuming 2-tailed testing, an alpha of .05, and an independent-samples *t* test, 27 patients per group were sufficient to detect an effect size of  $d = 0.78$  with 80% statistical power. First, the 2 patient groups were compared on the basis of potentially confounding covariates, including demographics and baseline outcome scores. Independent *t* tests

and Fisher exact tests were used to assess these associations. To address the primary purpose of this study, minimum 2-year outcome scores were compared between bucket-handle tear repair and vertical tear repair. Group effects with 95% CIs were reported. All analyses were completed with SPSS (IBM).

## RESULTS

### Patient Demographics

An initial database query yielded 85 patients (40 patients with bucket-handle tears, 45 patients with vertical tears) who were at least 2 years from surgery. The mean final follow-up for all patients was 3.1 years (range, 2-6 years). Complete follow-up was available for 70 of the 85 eligible patients (82%). This study included 70 knees in 70 patients (44 male, 26 female), with a mean age of 32.2 years (range, 16-65 years). The total patient cohort was divided into 2 groups: 38 patients (29 medial meniscus, 9 lateral meniscus) in the bucket-handle tear repair group and 32 patients (18 medial, 14 lateral) in the vertical tear repair group. The rate of medial and lateral meniscal tears was not significantly different between the 2 groups ( $P = .124$ ). The majority of meniscal tears in both groups were localized to the red-white zone (17 bucket-handle tears, 20 vertical tears) of the meniscus; however, there was not a significant difference in the distribution of meniscal tear zones between the 2 groups ( $P = .317$ ). There were no significant differences in sex ( $P = .143$ ) or age ( $P = .724$ ) between the 2 groups. Demographic variables are summarized for each group in Table 1.

### Postoperative Outcome Comparisons

Significant improvements from baseline in the SF-12 PCS ( $P < .001$ ), WOMAC ( $P < .001$ ), Lysholm ( $P < .001$ ), and Tegner ( $P = .01$ ) scores were observed for the bucket-handle tear group. Similar significant improvements were observed in the vertical tear group: SF-12 PCS ( $P < .001$ ), WOMAC ( $P < .001$ ), Lysholm score ( $P < .001$ ), and Tegner activity scale ( $P = .028$ ). When comparing postoperative outcomes of the bucket-handle tear group versus the vertical tear group, there was no significant difference in the SF-12 PCS ( $P = .244$ ), SF-12 MCS ( $P = .165$ ), WOMAC ( $P = .729$ ), Lysholm ( $P = .276$ ), Tegner ( $P = .970$ ), or patient satisfaction ( $P = .570$ ) scores. Furthermore, no significant differences were found in the SF-12 PCS ( $P = .244$ ), SF-12 MCS ( $P = .165$ ), WOMAC ( $P = .729$ ), Lysholm ( $P = .276$ ), Tegner ( $P = .970$ ), and patient satisfaction ( $P = .570$ ) scores when comparing medial bucket-handle tears to medial nondisplaced vertical tears and lateral bucket-handle tears to lateral nondisplaced vertical tears and between medial and lateral bucket-handle tears. Detailed data on postoperative outcome scores for the groups and laterality comparisons are reported in Tables 2 and 3, respectively.

TABLE 1  
Patient Demographics and Preoperative Outcome Scores for the Bucket-Handle and Vertical Tear Groups<sup>a</sup>

	Bucket-Handle Tear (n = 38)	Vertical Tear (n = 32)	P Value
Sex, male/female, n	27/11	17/15	.143 (FET)
Age, mean (range), y	31.8 (16-65)	32.9 (18-63)	.724 ( <i>t</i> test)
Knee, right/left, n	21/17	21/11	.068 (FET)
Concomitant ligament reconstruction, n (%)			
Anterior cruciate ligament	18 (47)	22 (69)	.090 (FET)
Posterior cruciate ligament	3 (8)	2 (6)	>.999 (FET)
Medial collateral ligament	5 (13)	3 (9)	.719 (FET)
Fibular collateral ligament	2 (5)	4 (13)	.402 (FET)
Baseline outcome scores, mean ± SD			
SF-12 PCS	40.7 ± 11.0	38.2 ± 10.0	.143 ( <i>t</i> test)
SF-12 MCS	54.1 ± 12.0	48.3 ± 13.7	.433 ( <i>t</i> test)
WOMAC	49.3 ± 26.0	39.5 ± 24.0	.272 ( <i>t</i> test)
Lysholm	48.5 ± 23.0	50.2 ± 23.0	.362 ( <i>t</i> test)
Tegner <sup>b</sup>	3.3 (0-10)	3.1 (0-10)	.683 (MWU)
No. of sutures, mean (range)	11 (2-20)	7 (2-22)	.001 (FET)
Meniscal tear zone, red-red/red-white/white-white, n	10/17/11	5/20/7	.317 ( $\chi^2$ )

<sup>a</sup>FET, Fisher exact test; MCS, mental component summary; MWU, Mann-Whitney *U* test; PCS, physical component summary; SF-12, Short Form-12; WOMAC, Western Ontario and McMaster Universities Osteoarthritis Index.

<sup>b</sup>Data are presented as mean (range).

### Effect of Concurrent Intra-articular Reconstruction on Postoperative Outcomes

Twenty-one patients (18 ACL, 3 posterior cruciate ligament) in the bucket-handle tear group and 24 patients (22 ACL, 2 posterior cruciate ligament) in the vertical tear group underwent intra-articular ligament reconstruction at the time of meniscal repair. There was no significant difference in outcomes between patients who underwent concurrent intra-articular ligament reconstruction and those who did not. Comparisons of postoperative outcome scores between those who did and did not undergo concurrent ligament reconstruction are reported in Table 4.

### Effect of Surgery Chronicity on Postoperative Outcomes

In the bucket-handle tear group, 28 (74%) patients were treated acutely, while 10 (26%) patients were treated in the chronic phase (mean, 20 weeks; range, 6-52 weeks). In the vertical tear group, 21 (66%) patients were treated acutely, while 11 (34%) patients were treated in the chronic phase (mean, 30 weeks; range, 6-104 weeks). There was not a significant difference in the number of patients treated in the acute or chronic phase between the 2 groups ( $P = .642$ ). Comparisons of postoperative outcome scores based on treatment chronicity are reported in Table 5.

### Complications and Reoperations

Six patients in the bucket-handle tear group went on to undergo additional surgeries: 3 patients underwent arthroscopic lysis of adhesions, and 3 patients underwent revision ACL reconstruction. In the vertical tear group, 1 patient underwent arthroscopic lysis of adhesions, and 1 patient

TABLE 2  
Postoperative Outcome Scores for the Bucket-Handle and Vertical Tear Groups<sup>a</sup>

	Bucket-Handle Tear	Vertical Tear	P Value
SF-12 PCS	54.0 ± 6.9	51.6 ± 9.1	.244
SF-12 MCS	55.3 ± 5.7	52.5 ± 9.8	.165
WOMAC	8.1 ± 11.9	9.0 ± 10.3	.729
Lysholm	84.6 ± 13.0	80.8 ± 14.9	.276
Tegner	5.5 ± 1.9	5.5 ± 2.5	.970
Patient satisfaction	7.4 ± 3.2	7.7 ± 2.2	.570

<sup>a</sup>Data are presented as mean ± SD. MCS, mental component summary; PCS, physical component summary; SF-12, Short Form-12; WOMAC, Western Ontario and McMaster Universities Osteoarthritis Index.

underwent revision ACL reconstruction. No patients in either group underwent revision meniscal repair procedures.

### DISCUSSION

The most important finding of this study was that repair of bucket-handle meniscal tears with multiple vertical mattress sutures using an inside-out technique produced improved outcomes that are comparable with outcomes after repair of vertical meniscal tears. Furthermore, inside-out repair of acute and chronic bucket-handle meniscal tears had similar outcomes. These results suggest that acute and chronic bucket-handle meniscal tears should be considered for repair with an inside-out technique to improve patient outcomes with low expected failure rates. The decision of repair or meniscectomy should not be based solely on chronicity but rather on the complete evaluation of the patient and the meniscal tissue quality.

TABLE 3  
Comparison of Postoperative Outcome Scores Between Medial and Lateral  
Bucket-Handle and Medial and Lateral Vertical Tears<sup>a</sup>

	Medial			Lateral		
	Bucket-Handle Tear	Vertical Tear	P Value	Bucket-Handle Tear	Vertical Tear	P Value
SF-12 PCS	54.3 ± 7.0	51.4 ± 9.1	.285	52.6 ± 6.5	51.9 ± 9.4	.844
SF-12 MCS	56.2 ± 5.4	52.8 ± 9.0	.405	52.4 ± 6.3	52.1 ± 11.0	.947
WOMAC	6.8 ± 9.5	8.8 ± 9.9	.518	11.8 ± 17.1	9.3 ± 11.2	.690
Lysholm	85.3 ± 12.5	81.0 ± 13.3	.255	82.5 ± 14.7	80.6 ± 17.0	.770
Tegner	5.4 ± 2.1	5.0 ± 2.0	.631	5.7 ± 1.2	6.0 ± 3.0	.735
Patient satisfaction	7.2 ± 3.2	7.5 ± 2.0	.578	7.8 ± 3.0	8.0 ± 2.4	.865

<sup>a</sup>Data are presented as mean ± SD. MCS, mental component summary; PCS, physical component summary; SF-12, Short Form-12; WOMAC, Western Ontario and McMaster Universities Osteoarthritis Index.

TABLE 4  
Comparison of Postoperative Outcome Scores Between the Repair of Bucket-Handle and Vertical Tears  
With and Without Concurrent Intra-articular Ligament Reconstruction<sup>a</sup>

	Bucket-Handle Repair			Vertical Repair		
	Without Concurrent Reconstruction (n = 17)	With Concurrent Reconstruction (n = 21)	P Value	Without Concurrent Reconstruction (n = 8)	With Concurrent Reconstruction (n = 24)	P Value
SF-12 PCS	53.2 ± 8.4	54.4 ± 5.8	.635	52.6 ± 9.5	53.1 ± 9.1	.739
SF-12 MCS	54.8 ± 6.0	55.6 ± 5.6	.706	50.1 ± 9.5	53.8 ± 9.9	.427
WOMAC	8.4 ± 9.4	8.0 ± 13.4	.915	7.0 ± 6.7	8.3 ± 11.3	.422
Lysholm	83.0 ± 14.3	85.5 ± 12.4	.590	84.9 ± 10.6	82.9 ± 16.1	.289
Tegner	5.2 ± 2.4	5.6 ± 1.6	.574	5.4 ± 1.8	5.5 ± 2.7	.904
Patient satisfaction	6.5 ± 3.5	7.9 ± 2.8	.227	6.9 ± 2.3	7.5 ± 2.1	.232

<sup>a</sup>Data are presented as mean ± SD. MCS, mental component summary; PCS, physical component summary; SF-12, Short Form-12; WOMAC, Western Ontario and McMaster Universities Osteoarthritis Index.

TABLE 5  
Comparison of Postoperative Outcome Scores Between Acute and Chronic Treatments of Bucket-Handle and Vertical Tears<sup>a</sup>

	Acute			Chronic		
	Bucket-Handle Tear (n = 28)	Vertical Tear (n = 21)	P Value	Bucket-Handle Tear (n = 10)	Vertical Tear (n = 11)	P Value
SF-12 PCS	52.9 ± 7.2	52.2 ± 8.9	.756	57.3 ± 4.2	50.5 ± 9.6	.060
SF-12 MCS	56.0 ± 5.2	54.2 ± 6.7	.318	53.0 ± 7.1	49.3 ± 13.7	.460
WOMAC	8.9 ± 12.8	10.0 ± 12.1	.759	5.9 ± 9.1	7.2 ± 5.8	.710
Lysholm	85.4 ± 12.4	79.0 ± 17.2	.170	82.3 ± 15.0	84.0 ± 9.6	.760
Tegner	5.6 ± 1.9	5.4 ± 2.4	.751	5.1 ± 2.1	5.5 ± 2.7	.680
Patient satisfaction	7.2 ± 3.3	5.4 ± 2.3	.629	7.9 ± 2.6	8.0 ± 2.0	.060

<sup>a</sup>Data are presented as mean ± SD. MCS, mental component summary; PCS, physical component summary; SF-12, Short Form-12; WOMAC, Western Ontario and McMaster Universities Osteoarthritis Index.

In this study, bucket-handle and vertical meniscal tears were treated surgically with multiple vertical mattress sutures using an inside-out technique. The postoperative Lysholm scores were 84.6 in the bucket-handle tear group and 80.8 in the vertical tear group. Furthermore, there was an improvement of other outcome scores, including the SF-12 PCS, SF-12 MCS, WOMAC, and Tegner, after the

surgical treatment of bucket-handle and vertical meniscal tears. There was no significant difference between the 2 groups. Fifty-nine (84%) of the patients in this cohort had concomitant ligament injuries, which may explain the outcome scores reported. Ahn et al<sup>1</sup> reported on outcomes after repair of isolated, displaced lateral meniscal bucket-handle tears in 13 patients at a median follow-up of 4

years. The authors reported full range of motion in all patients, a median Tegner score of 7, and a mean Lysholm of 94.6.<sup>1</sup>

No difference in outcomes between the acute and chronic bucket-handle tears was observed in the present study. The mean time from injury to surgery for chronic bucket-handle tears was 20 weeks (5 months), demonstrating that improved outcomes after chronic bucket-handle repair, even after several months, can be achieved; therefore, repair should be attempted even in chronic cases if possible. Furthermore, there was no significant difference between acute bucket-handle tears and acute nondisplaced vertical tears and no difference between chronic bucket-handle tears and chronic nondisplaced vertical tears. Previous studies have reported better outcomes for acute tears compared with chronic meniscal tears<sup>6,24</sup>; however, good outcomes have also been demonstrated after repair of chronic meniscal tears.<sup>22</sup> Espejo-Reina et al<sup>8</sup> reported good clinical outcomes after repair of chronic medial bucket-handle tears. In a retrospective evaluation of 24 patients at a mean follow-up of 48 months, the median Tegner score was 7, the median Lysholm score was 95, and there was a 17% failure rate. There was a significantly higher failure rate for repair performed in isolation than that performed in conjunction with ACL reconstruction.<sup>8</sup>

In the present study, there was no difference between meniscal tear repair with concomitant ligament reconstruction and repair without. The combination of the vertical mattress suture construct and the multiple sutures (mean, 11 sutures in the bucket-handle tear group; mean, 7 sutures in the vertical tear group) utilized in the repair procedures provided a mechanically strong construct that facilitated healing. Previous studies have reported that meniscal tears repaired at the time of ACL reconstruction had better outcomes when compared with those repaired in isolation.<sup>12,17,25</sup> It has been suggested that biological agents from marrow venting or tunnel reaming could enhance meniscal healing. A recent study by Dean et al<sup>5</sup> demonstrated that marrow venting and tunnel reaming for ACL reconstruction had comparable effects on outcomes after meniscal repair. The authors reported no difference between meniscal repair with bone marrow venting and that with concurrent ACL reconstruction in a review of 109 patients at a minimum of 2 years' follow-up.<sup>5</sup>

This study is not without limitations. The sample size is relatively small; however, prestudy power analysis demonstrated that 27 patients per group were sufficient to detect an effect size. All patients were treated by an experienced single surgeon at a sports medicine referral center, and the results may not be generalized. Additionally, this study compared results from repair of 2 different types of meniscal tears rather than 2 different techniques for the same type of tear. All patients were treated with an inside-out technique with multiple sutures, and these results may not be applicable for other meniscal repair techniques. No imaging was performed to evaluate meniscal healing; however, no patients had symptoms of failure such as persistent pain, joint line tenderness, and catching/locking.

## CONCLUSION

The repair of bucket-handle meniscal tears with multiple vertical mattress sutures using an inside-out technique yielded improved results and low failure rates, comparable with outcomes after repair of vertical meniscal tears. The findings of this study support repairing bucket-handle meniscal tears with multiple vertical mattress sutures when possible.

## REFERENCES

- Ahn JH, Kim KI, Wang JH, Kyung BS, Seo MC, Lee SH. Arthroscopic repair of bucket-handle tears of the lateral meniscus. *Knee Surg Sports Traumatol Arthrosc*. 2015;23(1):205-210.
- Barber-Westin SD, Noyes FR. Clinical healing rates of meniscus repairs of tears in the central-third (red-white) zone. *Arthroscopy*. 2014;30(1):134-146.
- Cerminara AJ, LaPrade CM, Smith SD, Ellman MB, Wijdicks CA, LaPrade RF. Biomechanical evaluation of a transtibial pull-out meniscal root repair: challenging the bungee effect. *Am J Sports Med*. 2014;42(12):2988-2995.
- Chahla J, Serra Cruz R, Cram TR, Dean SC, LaPrade RF. Inside-out meniscal repair: medial and lateral approach. *Arthrosc Tech*. 2016; 5(1):E163-E168.
- Dean CS, Chahla J, Matheny LM, Mitchell JJ, LaPrade RF. Outcomes after biologically augmented isolated meniscal repair with marrow venting are comparable with those after meniscal repair with concomitant anterior cruciate ligament reconstruction. *Am J Sports Med*. 2017;45(6):1341-1348.
- Eggli S, Wegmuller H, Kosina J, Huckell C, Jakob RP. Long-term results of arthroscopic meniscal repair: an analysis of isolated tears. *Am J Sports Med*. 1995;23(6):715-720.
- Ellman MB, Sherman SL, Forsythe B, LaPrade RF, Cole BJ, Bach BR Jr. Return to play following anterior cruciate ligament reconstruction. *J Am Acad Orthop Surg*. 2015;23(5):283-296.
- Espejo-Reina A, Serrano-Fernandez JM, Martin-Castilla B, Estades-Rubio FJ, Briggs KK, Espejo-Baena A. Outcomes after repair of chronic bucket-handle tears of medial meniscus. *Arthroscopy*. 2014;30(4):492-496.
- Fairbank TJ. Knee joint changes after meniscectomy. *J Bone Joint Surg Br*. 1948;30(4):664-670.
- Fillingham YA, Riboh JC, Erickson BJ, Bach BR Jr, Yanke AB. Inside-out versus all-inside repair of isolated meniscal tears: an updated systematic review. *Am J Sports Med*. 2017;45(1):234-242.
- Houe T, Jørgensen U. Arthroscopic posterior cruciate ligament reconstruction: one- vs. two-tunnel technique. *Scand J Med Sci Sports*. 2004;14(2):107-111.
- Hutchinson ID, Moran CJ, Potter HG, Warren RF, Rodeo SA. Restoration of the meniscus: form and function. *Am J Sports Med*. 2014;42(4):987-998.
- Krause WR, Pope MH, Johnson RJ, Wilder DG. Mechanical changes in the knee after meniscectomy. *J Bone Joint Surg Am*. 1976; 58(5):599-604.
- LaPrade CM, Foad A, Smith SD, et al. Biomechanical consequences of a nonanatomic posterior medial meniscal root repair. *Am J Sports Med*. 2015;43(4):912-920.
- LaPrade CM, Jansson KS, Dornan G, Smith SD, Wijdicks CA, LaPrade RF. Altered tibiofemoral contact mechanics due to lateral meniscus posterior horn root avulsions and radial tears can be restored with in situ pull-out suture repairs. *J Bone Joint Surg Am*. 2014;96(6):471-479.
- LaPrade RF, Moulton SG, Cram TR, Geeslin AG, LaPrade CM, Engebretsen L. Medial and lateral meniscal inside-out repairs. *JBJS Essential Surgical Techniques*. 2015;5(4):E24.

17. Melton JT, Murray JR, Karim A, Pandit H, Wandless F, Thomas NP. Meniscal repair in anterior cruciate ligament reconstruction: a long-term outcome study. *Knee Surg Sports Traumatol Arthrosc.* 2011;19(10):1729-1734.
18. Metcalf MH, Barrett GR. Prospective evaluation of 1485 meniscal tear patterns in patients with stable knees. *Am J Sports Med.* 2004;32(3):675-680.
19. Montgomery SR, Zhang A, Ngo SS, Wang JC, Hame SL. Cross-sectional analysis of trends in meniscectomy and meniscus repair. *Orthopedics.* 2013;36(8):E1007-E1013.
20. Musahl V, Citak M, O'Loughlin PF, Choi D, Bedi A, Pearle AD. The effect of medial versus lateral meniscectomy on the stability of the anterior cruciate ligament-deficient knee. *Am J Sports Med.* 2010;38(8):1591-1597.
21. Nitri M, Chahla J, Civitarese D, et al. Medial meniscus radial tear: a transtibial 2-tunnel technique. *Arthrosc Tech.* 2016;5(4):E889-E895.
22. Popescu D, Sastre S, Caballero M, et al. Meniscal repair using the FasT-Fix device in patients with chronic meniscal lesions. *Knee Surg Sports Traumatol Arthrosc.* 2010;18(4):546-550.
23. Shelbourne KD, Carr DR. Meniscal repair compared with meniscectomy for bucket-handle medial meniscal tears in anterior cruciate ligament-reconstructed knees. *Am J Sports Med.* 2003;31(5):718-723.
24. Tengrootenhuysen M, Meermans G, Pittoors K, van Riet R, Victor J. Long-term outcome after meniscal repair. *Knee Surg Sports Traumatol Arthrosc.* 2011;19(2):236-241.
25. Wasserstein D, Dwyer T, Gandhi R, Austin PC, Mahomed N, Ogilvie-Harris D. A matched-cohort population study of reoperation after meniscal repair with and without concomitant anterior cruciate ligament reconstruction. *Am J Sports Med.* 2013;41(2):349-355.
26. Xu C, Zhao J. A meta-analysis comparing meniscal repair with meniscectomy in the treatment of meniscal tears: the more meniscus, the better outcome? *Knee Surg Sports Traumatol Arthrosc.* 2015;23(1):164-170.