

Review of Arnoczky and Warren on the microvasculature of the human meniscus

Jorge Chahla,¹ Mark E Cinque,¹ Jonathan A Godin,¹ Andrew G Geeslin,¹ Gilbert Moatshe,^{1,2,3} Robert F LaPrade^{1,4}

¹Steadman Philippon Research Institute, Vail, Colorado, USA
²Oslo University Hospital and University of Oslo, Oslo, Norway
³OSTRC, The Norwegian School of Sports Sciences, Oslo, Norway
⁴The Steadman Clinic, Vail, Colorado, USA

Correspondence to

Dr Robert F LaPrade, Chief Medical Officer, Steadman Philippon Research Institute, The Steadman Clinic, 181 West Meadow Drive, Suite 400, Vail, Colorado 81657, USA; rlaprade@thesteadmanclinic.com

Received 19 April 2017

Revised 18 May 2017

Accepted 22 May 2017

ABSTRACT

This classic discusses the original publication 'Microvasculature of the human meniscus' by Drs Arnoczky and Warren on the microvascular anatomy of 20 cadaveric menisci. They described a perimeniscal capillary plexus, which supplies only the peripheral 10%–25% of the menisci. This description laid the anatomical and physiological foundation for meniscus tear treatment including the genesis of the 'red-red', 'red-white' and 'white-white' classification of meniscal lesions based on the visual assessment of blood supply. This was later translated clinically in the peripheral zones of the meniscus typically treated with repairs due to the increased vascularity of these regions. This study has generated 981 citations since 1982, ultimately becoming one of the most cited papers in the orthopaedic literature.

INTRODUCTION

In 1982, Arnoczky and Warren published a classic article on the microvascular of the human meniscus. In this classic article, the authors evaluated the microvascular anatomy of the medial and lateral menisci of the human knee in 20 cadaveric specimens with histology and tissue clearing (Spalteholz) techniques. They reported that the menisci were supplied by branches of the lateral, medial and middle genicular arteries. These arteries provide a perimeniscal capillary plexus (that originated from the capsular and synovial tissues of the joint), which supplies the peripheral 10%–25% of the menisci. Furthermore, they reported that the posterolateral aspect of the lateral meniscus adjacent to the popliteus tendon lacked penetrating peripheral vessels. Finally, the anterior and posterior horn attachments of the menisci were reported to be covered with vascular synovial tissue and appear to have a good blood supply.

CONSIDERATION

Historic perspective

'As with many discoveries, the meniscal vascular study was purely a 'lucky break', Dr Steven

Arnoczky humbly stated. In a recent conversation with Dr Arnoczky, he kindly shared the fascinating history of his studies on the vascularity of the meniscus.

Starting in 1976, Dr Arnoczky studied under Dr John Marshall and others at the Hospital for Special Surgery, where he learnt a vascular injection technique (the Spalteholz technique) from Dr Roy Rubin (a research fellow with Dr Marshall) and Dr Fred Rhinelandt at the Cleveland Clinic. At the time, the biology of the anterior cruciate ligament (ACL) was poorly understood, and Dr John Marshall and Dr John Feagin were evaluating techniques for primary repair of the ACL. Dr Arnoczky's initial research focus was therefore to study the blood supply of the human ACL and to develop an animal model of ACL injury.

His research then focused on revascularisation of patellar tendon grafts used for ACL reconstruction, including vascularisation and the biology of graft incorporation in a canine model. Due to inadequate storage space in their laboratory, he began to triage the human knee sections, keeping only those that included the ACL and/or PCL. As he went through these, he came across the specimen that contained a perfect cross-section of the medial meniscus, which has become known as the 'classic' meniscus slide (figure 1). The 'classic' meniscal slide may, in fact, be the 'most shown histology slide' in orthopaedics.

This finding occurred in 1979 when Dr Ken DeHaven was just starting to repair peripheral meniscal tears. After hearing a lecture given by Dr Arnoczky, Dr DeHaven noted the significance of the findings and urged Dr Marshall to initiate a comprehensive research study on the vasculature of the meniscus. A literature review was performed and identified only two papers that addressed meniscal blood supply. One was a canine study by Dr Don King from 1936¹ in which it was noted 'A torn meniscus can be healed by connective tissue if the tear communicates with the synovial membrane laterally.' The second was the paper by Professor

Summary of the Classic

- ▶ The study described the microvascular anatomy of the menisci of the human knee in 20 cadaveric specimens.
- ▶ First to describe the vasculature of the perimeniscal capillary plexus, which supplies only the peripheral 10%–25% of the menisci.
- ▶ Established the basis to create a meniscal treatment algorithm.
- ▶ Background for the creation of the 'red-red', 'red-white' and 'white-white' classification of meniscal lesions based on visual assessment of blood supply.



CrossMark

To cite: Chahla J, Cinque ME, Godin JA, et al. *JISAKOS* Published Online First: [please include Day Month Year]. doi:10.1136/jisakos-2017-000130

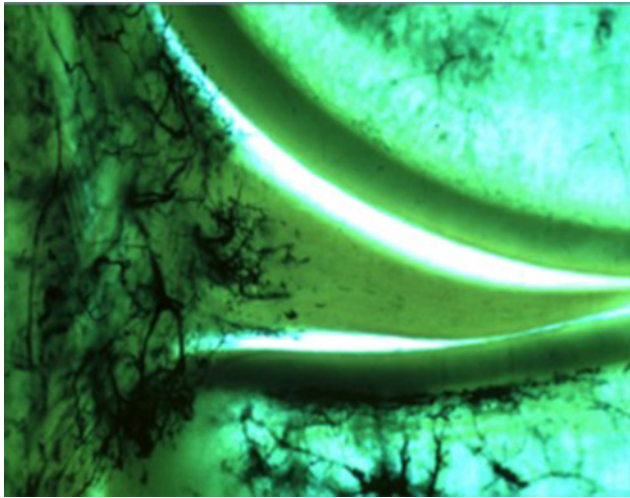


Figure 1 'Perfect' histological cross-section of the medial meniscus demonstrating the vascularisation of the meniscus with the Spalteholz technique. Reproduced with permission from Arnoczky and Warren.³

Scapinelli (Studies on the vasculature of the knee joint, *Acta Anat.* 1968).² Dr Arnoczky wrote to Professor Scapinelli to enquire about his work and received encouragement to complete a study on adult human cadaver knees.

This study was initiated in late 1979; however, Dr Marshall was tragically killed in a plane crash while travelling to the 1980 Winter Olympic Games in Lake Placid, New York. Fortunately, Dr Arnoczky was also working with Dr Russ Warren, who also realised the importance of this topic and enthusiastically supported the study. One of the most remarkable events occurred when he first presented their early results at an American Academy of Orthopaedic Surgeons meeting in Snowbird, Utah. He was in the speaker ready room going over his slides when he reached the 'classic' slide in the tray. He stopped for a moment to figure out how best to describe what was on the screen when someone tapped him on the shoulder. It was Dr DeHaven. He did not know him at all, but they spent the next hour talking about meniscal repair, the canine study and 'vascular access channels'. At the end of their discussion, Dr DeHaven asked if he could have a copy of the slide. Over the years, he has given this slide/image to countless individuals, and because of this, he was able to advance, at least in some way, meniscal repair.

The anatomical study³ and the canine study⁴ (the first of Arnoczky's two O'Donoghue Awards) were published at a time when meniscal repair was in its infancy. Under the guidance of Dr DeHaven, Dr Warren, Dr Chuck Henning, Dr Robert Jackson and Dr Dil Cannon, translational studies on meniscus repair were completed to provide clinically relevant information. Indeed, it was during a phone call with Dr Robert Jackson that Dr Arnoczky coined the term 'white-white' area when describing a meniscal lesion as being in the avascular zone by saying it was in the 'white-white' area. Born from that conversation was the classification system of 'red-red', 'red-white' and 'white-white' classification of the location of meniscal lesions based on visual assessment of blood supply, an easy and reproducible method to clinically correlate intraoperative findings to those documented in the vascular studies.

Scientific and societal impact

The study has generated 981 citations since 1982, ultimately becoming one of the most cited papers in the orthopaedic

literature.⁵ The most common publications citing this study are related to meniscus vascularity and meniscal healing capacity after injury and subsequent surgery. Furthermore, this study has been widely cited in works related to meniscal repair, and it has laid the foundation for laboratory and clinical studies to evaluate the zones of the meniscus that can heal following repair. In Arnoczky's study, he demonstrated that the zones with the greatest vascularity are the red/red and red/white zones of the meniscus. These findings have been further studied in the context of identifying the tears most amenable to repair, including vertical and horizontal tears in the red/red and white/red zones.^{6–8} Furthermore, outcomes following transtibial repair of radial meniscus tears have demonstrated good outcomes compared with those of inside-out repair of vertical meniscus tears.⁹ While early treatment of meniscal tears focused primarily on removal of the injured tissue, discovery of the detrimental mid- to long-term consequences following partial or total meniscectomy¹⁰ has led to increased attempts at meniscus repair whenever possible. While meniscal repairs have been reported to have a higher reoperation rate than meniscectomy, repairs result in better long-term patient-reported outcomes, improved activity levels and slower progression to osteoarthritis.^{11 12}

The vascularity of the menisci is primarily derived from the superior and inferior medial and lateral genicular arteries.³ The inferior medial geniculate artery supplies the peripheral 20%–30% of the medial meniscus, while the inferior lateral genicular artery supplies the peripheral 10%–25% of the lateral meniscus.³ A synovial fringe that extends approximately 3 mm over the surface of each meniscus adds further to the peripheral vascularity. The central 70%–75% of both menisci has been reported to receive nutrition via diffusion only. Consequently, there is significant discrepancy in the vascularity of the menisci, with the peripheral tissue ('red-red' and 'red-white' zones) more vascular than the central zones ('white-white' zone). The vascularity of the menisci has also been shown to diminish and become more peripheral with age.¹³ Therefore, the healing potential of the meniscus depends largely on the location of the lesion and the age of the patient.^{3 14 15} Because of its high vascularity, peripheral meniscal tears (red-red and the peripheral part of the red-white zone) have the greatest potential for healing.¹⁴

Clinically, meniscal tears in the red-red and red-white zones are typically treated with repairs due to the increased vascularity in these regions (dependent also on tissue quality and tear type). In contrast, tears in the white-white zone have classically been treated with debridement and meniscectomy rather than repair given the low likelihood of successful healing of a repair in avascular tissue.⁸ However, recent studies have demonstrated that repair of meniscal avascular white-white zone yielded satisfactory outcomes,¹⁶ and there remains controversy over which tears are best treated with repair versus meniscectomy.^{6 7}

While a handful of prior studies broadly assessed the vasculature of the human meniscus,^{2 17} this article was the first to use India Ink preparation to examine the microvasculature of the human meniscus. The authors used a cutting-edge India Ink perfusion method followed by Spalteholz preparation to analyse the specimens under light microscopy.

The meniscal repair technique (open, inside-out, outside-in, and the all-inside) should also be chosen based on the location of the tear and the surgeons' preference. As the inside-out technique allows for more versatility of placing sutures and the use of low-profile needles that allow for multiple sutures, it should be selected for more challenging patterns in the non-vascular zone. For peripheral tears, the type of technique might not be as relevant because the healing potential remains high.

Current evidence as related to the original article

Radial tears of the meniscus

Historically, radial tears were treated with either partial or total meniscectomy, as they were considered to be unreparable.¹¹ However, further research has demonstrated meniscectomy of complete radial meniscal tears to accelerate articular degeneration of the knee.^{18–20} With an increased emphasis on the detrimental long-term effects of meniscectomy, meniscal preservation is paramount whenever possible. Repair of radial tears of the meniscus was reinforced by a recent systematic review that reported improved patient outcomes with repair of radial meniscal tears when compared with meniscectomy at longer term follow-up.²¹

The literature regarding repair of radial tears and the healing of radial repairs is somewhat sparse. Foad⁷ demonstrated that radial tears may have a self-limited ability to heal, indicating that the repair of radial tears that extend into the vascular zone of the meniscus is advocated. In a later clinical study, Anderson *et al*²² reported on eight patients with a lateral meniscal radial tear that were treated with an inside-out horizontal suture repair. Mean Lysholm, International Knee Documentation Committee and Tegner scores were 86.9, 81.6 and 5.8, respectively, at a mean follow-up of 70.5 months. Choi *et al*²³ studied outcomes at a mean of 36.3 months after an all-inside repair of radial tears and reported a mean postoperative Lysholm and Tegner scores of 94.7 and 5.7, respectively. Bhatia *et al*²⁴ recently reported a biomechanical comparison of horizontal mattress inside-out repair versus two-tunnel repair techniques for midbody radial tears of the medial meniscus. The authors found the two-tunnel repairs displayed significantly less gapping distance after cyclic loading and significantly stronger ultimate failure loads compared with the horizontal mattress suture repairs.

Meniscal root tears

In recent years, there has been increasing focus on meniscal root tears. These injuries have been demonstrated to have similar biomechanical effects as total meniscectomy, leading to rapid joint degeneration. Therefore, early meniscal root tear diagnosis and repair have been advocated in patients without advanced osteoarthritis (Outerbridge grades 3 and 4). Improved functional outcomes and good healing rates have been reported in this patient population. Arnoczky and Warren reported on the microvasculature of the meniscal root, which can have implications on healing. The anterior horn and posterior root of both the medial and lateral meniscus were reported to be covered with a layer of vascular synovial tissue. Vessels within the anterior horn and posterior attachments were found to penetrate the meniscal tissue for a short distance and end in terminal capillary loops. These findings suggest that, comparable to the red-red zone of the meniscus, there is a good vascular supply and thereby good healing potential, in the anterior horn and posterior root of the menisci.

In a recent systematic review by Feucht *et al*,²⁵ of the 137 patients who underwent second look arthroscopy and MRI, 62% were rated as complete healing; 34%, as partial healing; and only 3%, as failed.²⁵ The high healing rates (complete and partial) were supported by good functional outcomes with Lysholm score improvement from 52.4 to 85.9 at a mean follow-up of 30.2 months.²⁵ Eighty-four per cent showed no progression of Kellgren-Lawrence grading. In another recent study, meniscal root repairs using a transtibial technique were demonstrated to achieve improved outcomes despite patient age.²⁶ It is worth noting that the healing rate of the posterior

meniscal roots can also be a result of creating a bony bed during repair and biological factors from tunnel reaming in the transtibial repair technique.

Peripheral meniscus tears

As previously noted, the article by Arnoczky and Warren was the basis for dividing the meniscus into three zones based on vascularity. The authors reported that there was a small reflection of vascular synovial tissue present throughout the peripheral border of the menisci on both the femoral and tibial surfaces, extending 1–3 mm, and containing small terminally looped vessels. Furthermore, vessels from the perimeniscal capillary plexus gave off smaller radial branches that penetrated the meniscal stroma for a short distance (10%–30% of meniscal width) and terminated in small capillary loops. These findings suggest that the red-red zone of the meniscus is highly vascularised and has therefore good healing potential.

There is a general consensus in the literature that peripheral tears in the red-red zone of the meniscus should be repaired. However, tears in the red-white zone have been a subject of controversy. Arnoczky and Warren reported that there was a variable degree of vascular penetration into the periphery of the medial meniscus; however, there was no correlation for his variation with regard to age, sex, race or anatomical location. In a clinical study, Noyes *et al*²⁷ reported that 62% of meniscal repairs in the red-white zone had normal or nearly normal characteristics in all of the parameters assessed, while 38% were documented as failures at a mean 16.8 years of follow-up.²⁷ Failures included partial resection, failure according to MRI criteria and loss of joint space. In a systematic review by Barber-Westin *et al*, a total of 637 of the 767 repairs (83%) were considered clinically healed. Both the inside-out technique (81%) and all-inside technique (86%) achieved good healing rates.⁶ The range in the healing rates was high; however, age, chronicity of injury, involved tibiofemoral compartment, gender and ACL reconstruction were not demonstrated to adversely affect the results. These findings could be explained by the variable vascularity of the red-white zone.

At present, there are no factors that have been correlated to vascularity in this zone, making it difficult to select patients who will achieve good healing after repair. Most of the medial meniscus tears are in the posterior horn. Cipolla *et al*²⁸ found good blood supply in 57% of the posterior horn tears and 39% of the bucket-handle tears when evaluating 40 adult menisci.²⁸ Therefore, repair is recommended because the healing potential cannot be determined preoperatively. This also calls for further research into methods to enhance meniscus healing in the avascular zones.

Lessons learnt

Biomechanical and clinical studies have demonstrated the importance of the meniscus in knee stability, joint congruity and load distribution. This has led to an increased focus on meniscus preservation as an important procedure for joint preservation. Despite advances in technology, there is a still relatively high failure rate after meniscus repair. Predicting failures after meniscus repairs has shown to be challenging. Most of the studies have few patients, and different techniques have been used. It has been difficult to demonstrate if it was patient related or procedure related. Kimura *et al* reported that the most important factors influencing meniscal healing were the presence of ACL tears, ligamentous reconstruction and vascularity of the tear site.²⁹ Several studies have demonstrated improved healing

The Classic

rates of meniscus repairs with a concurrent ACL reconstruction. Healing has also been demonstrated in the so called avascular zone of the meniscus, and this calls for re-evaluating the vascularity of the human meniscus and factors assessing vascularity in order to optimise meniscus repairs.

FUTURE DIRECTIONS

While this was an advanced technique at the time, the study could be further advanced by applying modern techniques. For example, Kobayashi *et al*³⁰ quantified the microvasculature of the canine ACL using several advanced techniques, including scanning electron microscopy (SEM) and transmission electron microscopy (TEM). The technique they describe of examining vascular corrosion casts under SEM allows for the differentiation of arteries and veins on the basis of the impression pattern on the cast surface.

Moreover, TEM has afforded researchers the ability to quantify tissue permeability. As a result, repeating this classic study using today's technology would yield a greater understanding of the arterial and venous composition of the menisci while also accounting for the permeability of the menisci to both synovial fluid and blood supply. In addition, blood vessels can now be stained for CD31 and von Willebrand factor, two common blood vessel markers. Staining can then be evaluated via histomorphological evaluation of the tissue and quantification of blood vessels in the white-white, red-white and red-red zones. Finally, immunohistochemical staining for smooth muscle markers CD34 (stem cell marker), CD146 (pericyte marker) and α -smooth muscle actin can detect the location of smooth muscle cells around the arterioles. Applying these specific staining techniques will allow a greater understanding of the cell composition surrounding the microvasculature of the meniscus.

Contributors All authors contributed to the development and execution of this work.

Competing interests RFL receives royalties from Arthrex and Smith & Nephew; is a paid consultant for Arthrex, Ossur and Smith & Nephew; and receives research support from Arthrex, Smith & Nephew, Ossur and Linvatec. RFL is also on the editorial/governing board for AJSM and KSSTA and has member/committee appointments for AOSSM, ISAKOS, AANA and ESSKA.

Provenance and peer review Commissioned; externally peer reviewed.

© International Society of Arthroscopy, Knee Surgery and Orthopaedic Sports Medicine (unless otherwise stated in the text of the article) 2017. All rights reserved. No commercial use is permitted unless otherwise expressly granted.

REFERENCES

- King D. The healing of semilunar cartilages. 1936. *Clin Orthop Relat Res* 1990;4–7.
- Scapinelli R. Studies on the vasculature of the human knee joint. *Acta Anat* 1968;70:305–31.
- Arnoczky SP, Warren RF. Microvasculature of the human meniscus. *Am J Sports Med* 1982;10:90–5.
- Arnoczky SP, Warren RF. The microvasculature of the meniscus and its response to injury. An experimental study in the dog. *Am J Sports Med* 1983;11:131–41.
- Ahmad SS, Evangelopoulos DS, Abbasian M, *et al*. The hundred most-cited publications in orthopaedic knee research. *J Bone Joint Surg Am* 2014;96:e190–1.
- Barber-Westin SD, Noyes FR. Clinical healing rates of meniscus repairs of tears in the central-third (red-white) zone. *Arthroscopy* 2014;30:134–46.
- Foad A. Self-limited healing of a radial tear of the lateral meniscus. *Knee Surg Sports Traumatol Arthrosc* 2012;20:933–6.
- Grant JA, Wilde J, Miller BS, *et al*. Comparison of inside-out and all-inside techniques for the repair of isolated meniscal tears: a systematic review. *Am J Sports Med* 2012;40:459–68.
- Cinque ME, Geeslin AG, Chahla J, *et al*. Two-tunnel transtibial repair of radial meniscus tears produces comparable results to inside-out repair of vertical meniscus tears. *Am J Sports Med* 2017;45:036354651770442.
- Fairbank TJ. Knee joint changes after meniscectomy. *J Bone Joint Surg Br* 1948;30B:664–70.
- Chahla J, Dean CS, Matheny LM, *et al*. Outcomes of inside-out meniscal repair in the setting of multiligament reconstruction in the knee. *Am J Sports Med* 2017;363546517698944.
- Dean CS, Chahla J, Matheny LM, *et al*. Outcomes after biologically augmented isolated meniscal repair with marrow venting are comparable with those after meniscal repair with concomitant anterior cruciate ligament reconstruction. *Am J Sports Med* 2017;45:1341–8.
- Petersen W, Tillmann B. Age-related blood and lymph supply of the knee menisci. A cadaver study. *Acta Orthop Scand* 1995;66:308–12.
- Johnson D, Weiss B. Meniscal repair using the inside-out suture technique. *Sports Med Arthrosc* 2012;20:68–76.
- Helms CA. The meniscus: recent advances in MR imaging of the knee. *AJR Am J Roentgenol* 2002;179:1115–22.
- Longo UG, Campi S, Romeo G, *et al*. Biological strategies to enhance healing of the avascular area of the meniscus. *Stem Cells Int* 2012;2012:1–7.
- Danzig L, Resnick D, Gonsalves M, *et al*. Blood supply to the normal and abnormal menisci of the human knee. *Clin Orthop Relat Res* 1983;172:271–6.
- Bedi A, Kelly NH, Baad M, *et al*. Dynamic contact mechanics of the medial meniscus as a function of radial tear, repair, and partial meniscectomy. *J Bone Joint Surg Am* 2010;92:1398–408.
- LaPrade CM, Jansson KS, Dornan G, *et al*. Altered tibiofemoral contact mechanics due to lateral meniscus posterior horn root avulsions and radial tears can be restored with in situ pull-out suture repairs. *J Bone Joint Surg Am* 2014;96:471–9.
- Mononen ME, Jurvelin JS, Korhonen RK. Effects of radial tears and partial meniscectomy of lateral meniscus on the knee joint mechanics during the stance phase of the gait cycle—a 3D finite element study. *J Orthop Res* 2013;31:1208–17.
- Moulton SG, Bhatia S, Civitaresse DM, *et al*. Surgical techniques and outcomes of repairing meniscal radial tears: a systematic review. *Arthroscopy* 2016;32:1919–25.
- Anderson L, Watts M, Shapter O, *et al*. Repair of radial tears and posterior horn detachments of the lateral meniscus: minimum 2-year follow-up. *Arthroscopy* 2010;26:1625–32.
- Choi NH, Kim TH, Victoroff BN. Comparison of arthroscopic medial meniscal suture repair techniques: inside-out versus all-inside repair. *Am J Sports Med* 2009;37:2144–50.
- Bhatia S, Civitaresse DM, Turnbull TL, *et al*. A novel repair method for radial tears of the medial meniscus: biomechanical comparison of transtibial 2-tunnel and double horizontal mattress suture techniques under cyclic loading. *Am J Sports Med* 2016;44:639–45.
- Feucht MJ, Kühle J, Bode G, *et al*. Arthroscopic transtibial pullout repair for posterior medial meniscus root tears: a systematic review of clinical, radiographic, and second-look arthroscopic results. *Arthroscopy* 2015;31:1808–16.
- LaPrade RF, Matheny LM, Moulton SG, *et al*. Posterior meniscal root repairs: outcomes of an anatomic transtibial pull-out technique. *Am J Sports Med* 2017;45:884–91.
- Noyes FR, Chen RC, Barber-Westin SD, *et al*. Greater than 10-year results of red-white longitudinal meniscal repairs in patients 20 years of age or younger. *Am J Sports Med* 2011;39:1008–17.
- Cipolla M, Cerullo G, Puddu G. Microvasculature of the human medial meniscus: operative findings. *Arthroscopy* 1992;8:522–5.
- Kimura M, Shirakura K, Hasegawa A, *et al*. Second look arthroscopy after meniscal repair. Factors affecting the healing rate. *Clin Orthop Relat Res* 1995:185–91.
- Kobayashi S, Baba H, Uchida K, *et al*. Microvascular system of anterior cruciate ligament in dogs. *J Orthop Res* 2006;24:1509–20.



Review of Arnoczky and Warren on the microvasculature of the human meniscus

Jorge Chahla, Mark E Cinque, Jonathan A Godin, Andrew G Geeslin, Gilbert Moatshe and Robert F LaPrade

J ISAKOS published online June 23, 2017

Updated information and services can be found at:
<http://jisakos.bmj.com/content/early/2017/06/23/jisakos-2017-000130>

These include:

References

This article cites 27 articles, 3 of which you can access for free at:
<http://jisakos.bmj.com/content/early/2017/06/23/jisakos-2017-000130>
#BIBL

Email alerting service

Receive free email alerts when new articles cite this article. Sign up in the box at the top right corner of the online article.

Notes

To request permissions go to:
<http://group.bmj.com/group/rights-licensing/permissions>

To order reprints go to:
<http://journals.bmj.com/cgi/reprintform>

To subscribe to BMJ go to:
<http://group.bmj.com/subscribe/>