

# Double-Bundle Posterior Cruciate Ligament Reconstruction in 100 Patients at a Mean 3 Years' Follow-up

## Outcomes Were Comparable to Anterior Cruciate Ligament Reconstructions

Robert F. LaPrade,<sup>\*†‡</sup> MD, PhD, Mark E. Cinque,<sup>†</sup> BS, Grant J. Dornan,<sup>†</sup> MSc, Nicholas N. DePhillipo,<sup>‡</sup> MS, ATC, OTC, Andrew G. Geeslin,<sup>†</sup> MD, Gilbert Moatshe,<sup>‡§||</sup> MD, and Jorge Chahla,<sup>†</sup> MD, PhD

*Investigation performed at Steadman Philippon Research Institute, Vail, Colorado, USA*

**Background:** Historically, outcomes of posterior cruciate ligament (PCL) reconstructions have been less predictable and reported to yield inferior results when compared with those for anterior cruciate ligament (ACL) reconstructions.

**Purpose:** To report on the outcomes of double-bundle PCL reconstructions (DB PCLRs) in isolated versus combined injuries and acute versus chronic PCL reconstructions. To compare the outcomes of isolated DB PCLR with isolated ACL reconstruction.

**Study Design:** Cohort study; Level of evidence, 3.

**Methods:** All patients who underwent a primary endoscopic DB PCLR for complete PCL tears (grade III) between May 2010 and March 2015 were reviewed. Patient-reported outcome scores (Tegner, Lysholm, WOMAC [Western Ontario and McMaster Universities Osteoarthritis Index], SF-12 [12-item Short Form Health Survey]) and objective posterior stress radiographs were collected preoperatively and at a minimum 2 years postoperatively. A cohort subanalysis was additionally performed between isolated and combined PCL reconstruction and acute versus chronic PCL reconstruction. Patients who underwent isolated ACL reconstructions over the same inclusion period (2010-2015) were selected as a comparison group.

**Results:** One hundred patients who underwent DB PCLR were included in this study. There were 31 isolated PCL injuries, and 69 patients had concurrent combined PCL injuries requiring surgery. The mean follow-up for the PCL cohort was 2.9 years (range, 2-6 years). The median Tegner activity score improved from 2 to 5, Lysholm from 48 to 86, WOMAC from 35.5 to 5, and SF-12 Physical Component Summary from 34 to 54.8 (all  $P$  values  $<.001$ ). The mean side-to-side difference in posterior tibial translation on kneeling stress radiographs improved from  $11.0 \pm 3.5$  mm preoperatively to  $1.6 \pm 2.0$  mm postoperatively ( $P < .001$ ). There were no differences in postoperative functional scores between isolated PCL reconstructions and PCL-based multiligament reconstructions (all  $P$  values  $>.229$ ). There was no significant difference in the reported outcome scores between acute and chronic reconstructions (all  $P$  values  $>.087$ ) except for Tegner scores ( $P < .001$ ) and patient satisfaction ( $P = .011$ ) favoring acutely treated PCL injuries. There were no significant differences between patients who had an isolated DB PCLR and patients who underwent an isolated ACL reconstruction ( $n = 141$ ) in postoperative outcome scores (all  $P$  values  $>.064$ ).

**Conclusion:** Significantly improved functional and objective outcomes were observed after anatomic DB PCLR at a mean 3 years' follow-up, with low complication rates, regardless of concomitant ligamentous injury or timing to surgery. Additionally, contrary to previous reports, comparable subjective and functional clinical outcomes were achieved compared with an isolated ACL reconstruction control cohort.

**Keywords:** posterior cruciate ligament; anatomic; reconstruction; PCL; double bundle; stress radiographs

Posterior cruciate ligament (PCL) injuries are increasingly being recognized as a cause of morbidity and reduced

function.<sup>11</sup> These injuries decrease joint longevity by causing degenerative changes when left untreated.<sup>19,29</sup> These factors have led to an increased focus on and improvement in surgical treatment of these injuries. Historically, indications for PCL reconstructions (PCLRs) were acute PCL injuries combined with other ligamentous pathology. However, a significant controversy exists in cases of isolated and chronic injuries.<sup>19</sup> In this regard, magnetic resonance imaging (MRI) is less

sensitive for the evaluation of chronic PCL injuries because the signal intensity and shape of the torn PCL can be restored; however, residual laxity can be present and stress radiographs therefore play a fundamental role.<sup>11</sup>

PCLR was recently reported to produce more satisfactory and consistent knee stability when compared with nonoperative treatment.<sup>1</sup> While improvements in single-bundle PCLR tunnel placement, fixation type, and optimal graft fixation angles have been achieved, biomechanical and clinical studies demonstrated residual laxity after single-bundle PCLR.<sup>17</sup> A recent systematic review with a meta-analysis reported that double-bundle PCLRs (DB PCLRs) provided significantly improved objective posterior tibial stability and objective International Knee Documentation Committee scores when compared with single-bundle PCLR in randomized clinical trials.<sup>7</sup>

Additionally, outcomes of PCLR were less predictable and were reported to yield inferior results when compared with anterior cruciate ligament (ACL) reconstruction.<sup>25</sup> The purported inferior outcomes of PCLR may be due to the heterogeneity in the diagnosis, treatment indications, surgical techniques, and rehabilitation protocols.<sup>7</sup> In this regard, an improved understanding of the anatomy and biomechanics of the PCL (where both bundles have been reported to be codominant for the native biomechanics) has led to the development of advanced surgical techniques and rehabilitation protocols.<sup>9,19,27</sup>

Despite improvements in the understanding of PCL anatomy and biomechanics and in surgical instrumentation and techniques, outcomes of DB PCLR in a large patient series is currently lacking in the literature. Therefore, the purposes of this study were to report on the outcomes after DB PCLR in isolated versus combined injuries and acute versus chronic PCLR and to compare the outcomes of isolated DB PCLR with those of isolated ACL reconstruction. The hypothesis was that DB PCLR would result in improved subjective clinical outcomes and restoration of knee stability with low complication rates. Furthermore, comparable results could be obtained from isolated and combined PCLRs, performed acutely or chronically. Additionally, it was hypothesized that results similar to those of isolated ACL reconstructions could be obtained.

## METHODS

### Study Design

This prospective study was approved by our institutional review board (No. 2002-03). Patients were included if they

underwent a primary endoscopic DB PCLR for complete PCL tears (grade III)<sup>2</sup> by a single surgeon (R.F.L.) between May 2010 and March 2015. Indications for surgery were as follows: isolated symptomatic acute grade III PCL tears (comparative kneeling radiographs with >8-mm difference), combined reconstructions for multiligament lesions, or combined reconstructions with repairable meniscal body tears in the acute setting. Patients were excluded from the procedure if they had arthritic changes greater than Kellgren-Lawrence grade 2, previous ipsilateral knee surgery, or a previous infection of the same joint. All patients who met inclusion criteria underwent clinical examination, radiography (plain, alignment, and posterior stress), and MRI before surgery. All operations were performed as a single stage.

Consecutive isolated ACL reconstructions over the same inclusion period (2010-2015) were selected to create a comparison group for the isolated PCLR group. In addition to the aforementioned exclusion criteria, patients undergoing isolated ACL reconstruction were excluded if they had any concomitant full-thickness chondral lesions (International Cartilage Repair Society grade IV), meniscus radial or root tears, or other ligamentous pathology requiring surgery at the time of ACL reconstruction.

### Surgical Technique

The grafts were prepared on the back table: the anterolateral bundle (ALB) graft was prepared from an Achilles tendon allograft with an 11 mm–diameter and 20 mm–long calcaneal bone plug, and the distal soft tissue aspect of the graft was tubularized. The posteromedial bundle (PMB) graft was prepared from a 7 mm–diameter soft tissue tibialis anterior allograft by tubularizing each end of the graft.

Standard anterolateral and anteromedial arthroscopic portals were created, and the femoral attachments of the ALB and PMB were identified. The ALB attachment was first outlined between the trochlear point and medial arch point, adjoining the edge of the articular cartilage.<sup>3</sup> The outline of the PMB attachment was then marked approximately 5.8 mm proximal to the edge of the articular cartilage of the medial femoral condyle and slightly posterior to the ALB tunnel. Next, an 11 mm–diameter closed socket tunnel was reamed to a depth of 25 mm for the ALB bundle, and a 7-mm reamer was placed against the previously outlined PMB to create the second tunnel of the same depth. A 2-mm bone bridge was maintained between the femoral tunnels (Figure 1).

To identify the tibial attachment, a posteromedial portal was created to facilitate the identification and preparation of the tibial PCL attachment site. A tibial guide pin was

\*Address correspondence to Robert F. LaPrade, MD, PhD, Steadman Philippon Research Institute, The Steadman Clinic, 181 West Meadow Drive, Suite 400, Vail, CO 81657, USA (email: drlaprade@sprivail.org).

†Steadman Philippon Research Institute, Vail, Colorado, USA.

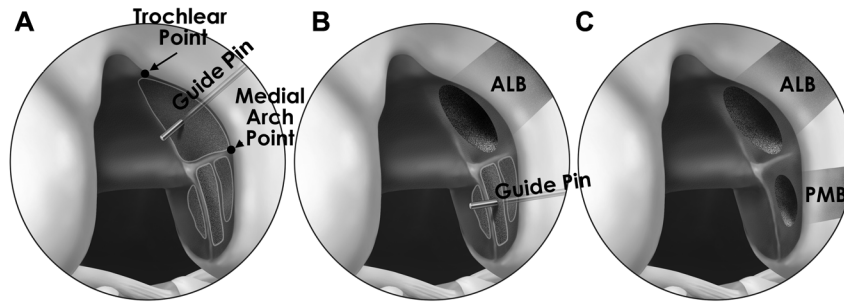
‡The Steadman Clinic, Vail, Colorado, USA.

§Oslo Sports Trauma Research Center, The Norwegian School of Sports Sciences, Oslo, Norway.

||Oslo University Hospital, Oslo University, Oslo, Norway.

Presented at the 44th annual meeting of the AOSSM, San Diego, California, USA, July 2018.

One or more of the authors has declared the following potential conflict of interest or source of funding: R.F.L. receives royalties from Arthrex Inc and Smith & Nephew; is a paid consultant for Arthrex Inc, Ossur, and Smith & Nephew; and receives research support from Arthrex Inc, Smith & Nephew, Ossur, and Linvatec.



**Figure 1.** Schematic representation of the medial aspect of the femoral notch in a right knee demonstrating the sequence for a double-bundle posterior cruciate ligament reconstruction. (A) A guide pin is inserted (through an 11-mm reamer between the trochlear point and the medial arch point, adjacent to the cartilage) to re-create the anterolateral bundle (ALB). (B) Then, an 11 mm-diameter closed socket tunnel is reamed to a depth of 25 mm for the ALB. The posteromedial bundle (PMB) attachment is reproduced next, approximately 5 mm posterior to the edge of the articular cartilage of the medial femoral condyle and distal to the medial arch point (also with the help of a 7-mm reamer placed in the medial wall to assess for final position). (C) Finally, a closed socket tunnel is reamed to a depth of 25 mm for the second tunnel (PMB). Of note, a bone bridge of 2 mm should be always present between the tunnels.

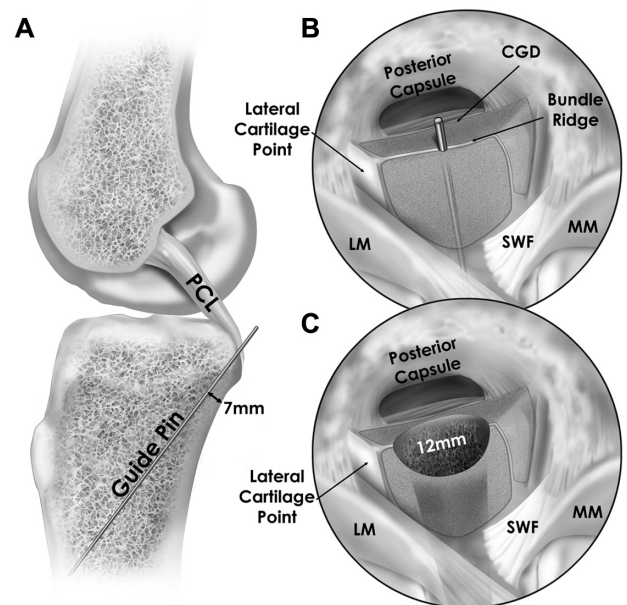
drilled, entering the anteromedial aspect of the tibia approximately 6 cm distal to the joint line and exiting posteriorly at the center of the PCL tibial attachment along the PCL bundle ridge. A 12-mm acorn reamer was used to overream the tibial guide pin under direct posterior arthroscopic visualization (Figure 2).

Next, a large smoother (Gore Smoother Crucial Tool; Smith & Nephew) was inserted up the tibial tunnel to facilitate graft passage, and the end of the smoother was passed out the anterolateral arthroscopic portal. The PMB graft was then fixed in the femoral tunnel with a 7 × 23-mm bio-absorbable interference screw; then, the ALB graft was fixed with a 7 × 20-mm titanium interference screw (Arthrex Inc). After the grafts were fixed in the femoral tunnels, the sutures in the ends of both grafts were then passed through the loop tip of the smoother. The smoother and the graft sutures in its eyelet tip were pulled distally down the tibial tunnel and out the anteromedial aspect of the tibia. The grafts were cycled and individually secured with a 6.5-mm cancellous bicortical screw and 18-mm spiked washers. The ALB was secured first at 90° with an anterior drawer force to reproduce the normal tibiofemoral step-off, and then the PMB was secured at 0° (Figure 3).

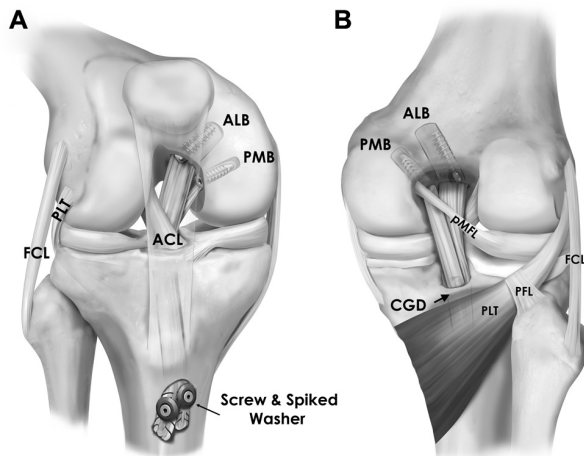
Previously described techniques were utilized for ACL reconstruction,<sup>8</sup> posterolateral corner reconstructions,<sup>31</sup> posteromedial reconstructions,<sup>32</sup> and meniscal repair<sup>10</sup> (Figure 3).

### Postoperative Rehabilitation

Postoperatively, all patients remained nonweightbearing for 6 weeks. For the first 6 months postoperatively, a dynamic PCL brace (PCL Rebound; Ossur Americas) was applied and worn at all times, except during bathing and dressing. Range of motion and edema control started on postoperative day 1. Prone knee flexion was limited to 90° for the first 2 weeks; thereafter, knee motion was increased as tolerated. Weightbearing was initiated at 6 weeks postoperatively with low-resistance cycling on a stationary bike and leg



**Figure 2.** Schematic representation of the tibial attachment of the posterior cruciate ligament (PCL) for a double-bundle PCL reconstruction. (A) A guide pin is drilled, entering the anteromedial aspect of the tibia approximately 6 cm distal to the joint line and exiting at the center of the PCL tibial attachment along the PCL bundle ridge. Positioning of the guide pin should be assessed with fluoroscopy (7 mm anterior to the posterior cortex on the lateral view and medial to the lateral eminence on the anteroposterior view). (B) Arthroscopically, the pin should exit at the center of the bundle ridge, posterior to the shiny white fibers (SWF) and medial to the lateral cartilage point. (C) Next, a 12-mm acorn reamer was used to overream the tibial guide pin under direct posterior arthroscopic visualization. CGD, champagne glass drop-off; LM, lateral meniscus; MM, medial meniscus.



**Figure 3.** (A) Anterior and (B) posterior views of the anatomic double-bundle posterior cruciate ligament reconstruction. The reconstructed anterolateral bundle (ALB) and posteromedial bundle (PMB) are shown, as well as the size, shape, and location of their femoral and tibial tunnels. The PMB enters the tibial tunnel posteromedial to the ALB. The PMB is posterior in the transtibial tunnel, exits deep to the ALB, and then is fixed medially and distally to the ALB. Femoral fixations of both bundles and the champagne glass drop-off (CGD)—the anatomic landmark for transtibial tunnel drilling—are also displayed. ACL, anterior cruciate ligament; FCL, fibular collateral ligament; PFL, popliteofibular ligament; PLT, popliteus tendon, pMFL, posterior menisiofemoral ligament (ligament of Wrisberg).

presses performed to a maximum of 70° of knee flexion. Progressive evolution into low-impact knee exercises was allowed as tolerated starting 12 weeks after surgery.

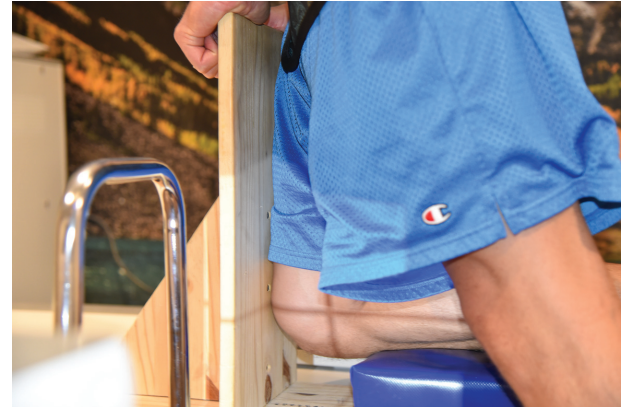Six months postoperatively, patients were evaluated clinically and with kneeling posterior stress radiographs. Patients were allowed to discontinue the dynamic PCL brace for routine daily use if the side-to-side difference (SSD) in kneeling stress radiographs were <2 mm, and they could initiate a jogging program, side-to-side activities, and proprioceptive exercises. Functional testing (the Vail Sports Test) was performed between 9 and 12 months postoperatively to determine the ability of the patients to return to full activities. The dynamic PCL brace was worn for sporting activities for the first year of athletic competition.

### Patient Demographics

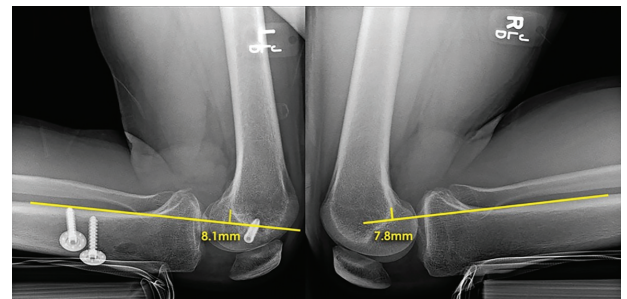
Collected patient demographic information included sex, age at time of surgery, and specific ligament injury pattern. Concomitant chondral and meniscal pathology was identified and documented at the time of surgery. Furthermore, patients were defined to have an acute injury if they underwent reconstruction surgery within 6 weeks of the injury.<sup>14</sup>

### Patient-Reported Outcomes

Patients completed a subjective outcome questionnaire preoperatively and at a minimum 2 years postoperatively that



**Figure 4.** Setup for PCL kneeling stress radiographs. Patient is kneeling with his right limb on a custom-designed fixture that allows the tibial tubercle to sit at the edge of the stand, leaving the femoral aspect anterior against gravity. A PCL-deficient knee will let the femur displace more distally in comparison with the uninjured knee. PCL, posterior cruciate ligament.



**Figure 5.** PCL stress radiographs (kneeling) demonstrating a side-to-side difference of +0.3 mm 2 years postoperatively after a double-bundle PCL reconstruction of the left knee. PCL, posterior cruciate ligament.

included the Lysholm score, Tegner activity scale, WOMAC (Western Ontario and McMaster Universities Osteoarthritis Index), SF-12 PCS (12-item Short Form Health Survey Physical Component Summary), and satisfaction with outcome. Patient satisfaction with outcome was rated on a 10-point scale (1, highly unsatisfied, up to 10, highly satisfied). All patients were administered a questionnaire on a tablet at the time of the office visit or via email.

### Objective Measurements: Kneeling Stress Radiographs

Bilateral posterior stress radiographs based on the kneeling technique<sup>16</sup> to measure posterior translation were obtained preoperatively, 6 months postoperatively, and at last follow-up (Figure 4).

This measurement technique has high intra- and inter-observer reliability.<sup>16</sup> SSD in posterior tibial translation of 8 to 12 mm has been associated with an isolated complete

TABLE 1  
Patient Demographics and Preoperative Outcome Scores  
Demonstrating That the Initial Status of Both Cohorts Was Comparable<sup>a</sup>

Variable	Reconstruction Cohort		P Value
	PCL (n = 100)	ACL (n = 141)	
Age, y, mean (range)	31.7 (14-66)	35.2 (14-81)	.042 <sup>b</sup> (MWU)
Sex, No.			<.001 <sup>b</sup> (FET)
Male	77	63	
Female	23	78	
Follow-up interval, y, mean (range)	2.9 (2-6)	3.1 (2-7)	.289 (MWU)
Chronicity, No.			.033 (FET)
Acute	52	93	
Chronic	48	48	
Meniscus tear distribution, No.			.590 ( $\chi^2$ )
None	45	55	
Medial meniscus	23	39	
Lateral meniscus	16	21	
Medial and lateral meniscus	7	15	
Outerbridge grade IV chondral lesions, No.	11 <sup>c</sup>	0	N/A
Preoperative outcome scores, mean $\pm$ SD			
Tegner Activity Scale <sup>d</sup>	2 [1, 3]	2 [1, 5]	.135 (MWU)
Lysholm score	49.6 $\pm$ 25.1	51.0 $\pm$ 23.2	.691 ( <i>t</i> test)
WOMAC	38.7 $\pm$ 27.9	35.2 $\pm$ 23.1	.333 ( <i>t</i> test)
SF-12 PCS	37.6 $\pm$ 10.9	40.3 $\pm$ 9.7	.015 <sup>b</sup> ( <i>t</i> test)

<sup>a</sup>ACL, anterior cruciate ligament; FET, Fisher exact test; MWU, Mann-Whitney *U* test; N/A, not applicable; PCL, posterior cruciate ligament; SF-12 PCS, 12-item Short Form Health Survey Physical Component Summary; WOMAC, Western Ontario and McMaster Universities Arthritis Index.

<sup>b</sup>*P* < .05.

<sup>c</sup>Full-thickness lesions.

<sup>d</sup>Median [first quartile, third quartile].

PCL tear, and >12 mm has been reported with combined posterolateral or posteromedial corner injuries<sup>30</sup> (Figure 5).

### Statistical Analysis

Postoperative outcome scales exhibited substantial skew, so results were summarized with medians and quartiles. To address this study's hypotheses, group comparisons involving postoperative outcomes were made with Mann-Whitney *U* tests for independent samples and Wilcoxon signed rank tests for change-from-baseline comparisons of patient-reported outcomes. To further aid in interpretation of clinically relevant group differences, 95% bias-corrected and accelerated bootstrap CIs for the difference in group medians were computed and plotted. Preoperative outcome scales (except Tegner) were normally distributed and were compared between groups with independent *t* tests. Fisher's exact tests and chi-square tests were used to compare binary and categorical variables between groups, respectively. Statistical power for the group comparisons was inferred by the CI widths. Additionally, statistical power was considered a priori. Based on the assumption of nonparametric 2-tailed testing and an alpha of .05, 100 PCL patients were sufficient to detect effect sizes (*d*) of 0.29 and 0.41 with 80% power for matched pairs and independent samples tests, respectively. Thus, we cannot rule out effect sizes smaller than

these values in our study. All graphs and analyses were completed with the statistical package R (R Development Core Team).<sup>28</sup>

### RESULTS

#### PCLR Cohort and Control Group Demographics

There were 101 patients who met the inclusion criteria; 1 patient was unavailable for final follow-up, resulting in a final cohort of 100 patients who underwent PCLR. A total of 228 isolated ACL reconstructions over the same inclusion period were identified. Of these 228 patients, 160 patients met the inclusion criteria; 19 were lost to follow-up, leaving 141 patients. Table 1 reports patient demographics and concomitant injuries for the PCL and ACL reconstructions.

#### DB PCLR Cohort Patient-Reported Outcomes

After PCLR, the median Tegner activity score improved from 2 to 5 (*P* < .001), Lysholm from 48.0 to 86.0 (*P* < .001), WOMAC from 35.5 to 5.0 (*P* < .001), and SF-12 PCS from 34.0 to 54.8 (*P* < .001). The mean SSD in posterior tibial translation on stress radiographs was 11.0  $\pm$  3.5 mm preoperatively and 1.6  $\pm$  2.0 mm postoperatively (*P* < .001). Table 2 reports pre- and postoperative outcome score summaries for the PCL group.

TABLE 2  
Pre- and Postoperative Outcome Scores for All Patients Who Underwent  
Double-Bundle Posterior Cruciate Ligament Reconstruction (N = 100)<sup>a</sup>

Outcome Scale	Score		P Value <sup>b</sup>
	Preoperative	Postoperative	
Tegner Activity Scale	2 [1, 3]	5 [3, 6.5]	<.001
Lysholm score	48.0 [34.5, 68.5]	86 [70.0, 94.0]	<.001
WOMAC	35.5 [12.3, 59.0]	5 [2, 13]	<.001
SF-12 PCS	34.0 [29.1, 45.9]	54.8 [43.1, 57.8]	<.001
Patient satisfaction	N/A	9 [6, 10]	N/A

<sup>a</sup>Data presented as median [first quartile, third quartile]. N/A, not applicable; SF-12 PCS, 12-item Short Form Health Survey Physical Component Summary; WOMAC, Western Ontario and McMaster Universities Arthritis Index.

<sup>b</sup>P values correspond to Wilcoxon signed rank test.

TABLE 3  
Pre- and Postoperative Outcome Scores for Patients Who Underwent  
Isolated or Combined Double-Bundle PCL Reconstruction<sup>a</sup>

Outcome Scale	Score		P Value
	Isolated PCL Reconstruction (n = 31)	PCL-Based Multiligament Reconstruction <sup>b</sup> (n = 69)	
	Preoperative		
Tegner Activity Scale	2 [1, 3.5]	2 [0.5, 3]	.441 (MWU)
Lysholm score	57.0 ± 21.7	46.7 ± 26.0	.058 ( <i>t</i> test)
WOMAC	31.5 ± 20.7	41.6 ± 30.1	.072 ( <i>t</i> test)
SF-12 PCS	38.2 ± 10.8	37.4 ± 11.1	.748 ( <i>t</i> test)
	Postoperative		
Tegner Activity Scale	5 [3, 7]	5 [3, 6]	.896 (MWU)
Lysholm score	87 [70, 95]	83.5 [70.5, 91]	.229 (MWU)
WOMAC	3 [1, 13]	6 [2, 15]	.268 (MWU)
SF-12 PCS	56.8 [46.6, 57.8]	53.4 [42.3, 57.6]	.329 (MWU)
Patient satisfaction	9 [6, 10]	9 [6, 10]	.663 (MWU)

<sup>a</sup>Data presented as mean ± SD or median [first quartile, third quartile]. MWU, Mann-Whitney *U* test; PCL, posterior cruciate ligament; SF-12 PCS, 12-item Short Form Health Survey Physical Component Summary; WOMAC, Western Ontario and McMaster Universities Arthritis Index.

<sup>b</sup>With additional cruciate or collateral ligament reconstruction.

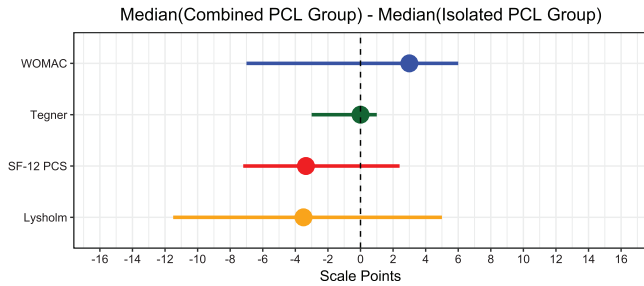
### Isolated PCL vs Combined PCLR Outcomes

The PCLR cohort (N = 100) was divided into patients who underwent isolated PCLR (n = 31) and patients who had a PCLR with concomitant ACL and/or collateral ligament reconstructions (n = 69). The cohort that had an additional procedure associated with a PCLR included the following: 19 PCL + ACL + fibular collateral ligament (FCL), 16 PCL + medial collateral ligament (MCL), 14 PCL + FCL, 8 PCL + ACL + MCL + FCL, 7 PCL + ACL + FCL, 2 PCL + PLC, 2 PCL + ACL, and 1 PCL + MCL + FCL. Combined PCLR cases were more likely than isolated PCLR to be acute ( $P < .003$ ). The mean SSD in preoperative posterior tibial translation on stress radiographs was  $8.7 \pm 1.9$  mm for isolated PCL tears and  $11.9 \pm 3.6$  mm for combined PCL tears with other ligamentous injuries. The mean SSD in postoperative posterior tibial translation on stress radiographs was  $1.2 \pm 1.1$  mm for isolated PCL tears and  $1.7 \pm 2.2$  mm for combined PCL tears. Pre- to postoperative improvement in posterior tibial translation was significant for the isolated and combined PCL injury

groups ( $P < .001$ ). Table 3 presents summaries of pre- and postoperative outcome scores for both groups. Figure 6 presents CIs for the difference in group medians for each postoperative outcome scale.

### Acute vs Chronic DB PCLR Outcomes

Fifty-two patients had a DB PCLR in the acute phase (<6 weeks), while 48 patients underwent surgery in the chronic phase. Preoperatively, there was a significant difference in the Lysholm and WOMAC scores between the acutely treated patients and those treated in the chronic phase (each  $P \leq .001$ ). At final follow-up, there was no significant difference in the reported outcome scores between acute and chronic reconstructions (all  $P$  values  $>.087$ ), except for Tegner scores ( $P < .001$ ) and patient satisfaction ( $P = .011$ ) (Table 4). The mean SSD in posterior tibial translation on stress radiographs improved from  $11.6 \pm 3.1$  mm preoperatively to  $1.9 \pm 2.5$  mm postoperatively ( $P < .001$ ) for acute PCL tears and from  $10.3 \pm 3.7$  mm



**Figure 6.** Difference in medians for several outcome scales between the isolated PCL group and the PCL-based combined reconstruction group. Horizontal lines indicate 95% bootstrap CIs. PCL, posterior cruciate ligament; SF-12 PCS, 12-item Short Form Health Survey Physical Component Summary; WOMAC, Western Ontario and McMaster Universities Osteoarthritis Index.

to  $1.2 \pm 1.0$  mm ( $P < .001$ ) for chronic PCL tears. Table 4 and Figure 7 present comparisons between acute and chronic DB PCLR groups

### Isolated PCL vs Isolated ACL Reconstruction Outcomes

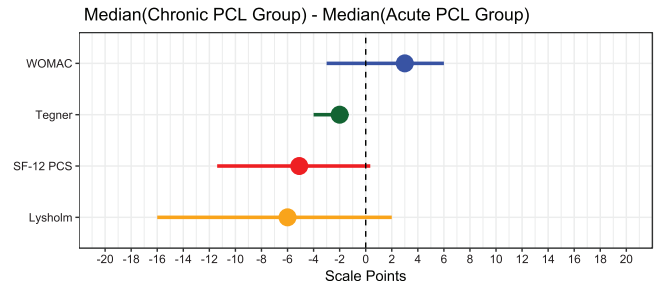
The group undergoing isolated DB PCLR had significantly more chronic injuries ( $P < .001$ ) and more male patients ( $P < .001$ ) than the group undergoing isolated ACL reconstruction. There was no significant difference in the pattern of meniscus lesion involvement between the groups ( $P = .826$ ). There were also no significant differences between patients who had an isolated DB PCLR and patients who underwent an isolated ACL reconstruction at preoperative status (all  $P$  values  $> .210$ ). Patients in the isolated ACL reconstruction cohort experienced a significant increase in all outcome scores from pre- to postoperative status ( $P < .001$ ). The groups demonstrated no significant differences in postoperative outcome scores (all  $P$  values  $> .064$ ). Table 5 presents a comparison of pre- and postoperative outcome scores between the groups, and Figure 8 illustrates the differences in group medians with 95% CIs.

### Complications

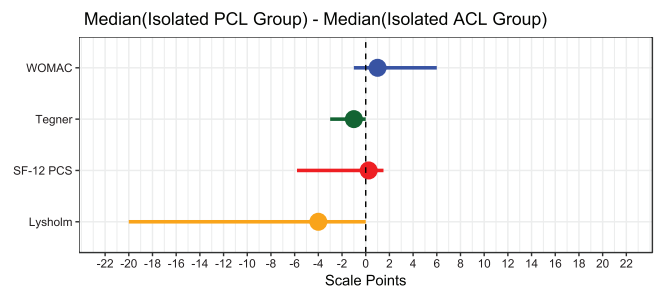
Six patients (6%) in the PCLR group had postsurgical complications requiring additional surgery. Three patients had a lysis-of-adhesions procedure for persistent stiffness at a mean 3 years after the initial PCLR. One patient had a revision PCL procedure after graft failure owing to tunnel osteolysis. One patient had a revision popliteus reconstruction 3 years after index surgery for residual laxity. One patient, who had a PCL/MCL reconstruction, sustained a sports-related MCL retear requiring surgical intervention.

### DISCUSSION

The most important findings of this study were that subjective and objective stability outcomes significantly improved



**Figure 7.** Difference in medians for several outcome scales between the acute and chronic PCL groups. Horizontal lines indicate 95% bootstrap CIs. PCL, posterior cruciate ligament; SF-12 PCS, 12-item Short Form Health Survey Physical Component Summary; WOMAC, Western Ontario and McMaster Universities Osteoarthritis Index.



**Figure 8.** Difference in medians for several outcome scales between the isolated ACL and PCL groups. Horizontal lines indicate 95% bootstrap CIs. ACL, anterior cruciate ligament; PCL, posterior cruciate ligament; SF-12 PCS, 12-item Short Form Health Survey Physical Component Summary; WOMAC, Western Ontario and McMaster Universities Osteoarthritis Index.

following anatomic DB PCLRs. Moreover, comparable results were observed between both isolated and combined, and acute and chronic DB PCLRs (with the exception of Tegner and patient satisfaction in the chronic group). Outcomes following isolated PCL reconstructions were not significantly different when compared to isolated ACL reconstructions.

Significantly improved subjective outcomes and functional scores from the preoperative states occurred after a DB PCLR. Furthermore, DB PCLRs significantly restored posterior tibial translation as evaluated by kneeling stress radiographs. The SSD in posterior tibial translation improved from 11.0 mm preoperatively to 1.6 mm postoperatively. These findings are consistent with biomechanical studies demonstrating that a DB PCLR restores knee kinematics to near normal.<sup>18</sup> The use of a biomechanically validated technique with an 11-mm Achilles allograft and a 7-mm tibialis anterior allograft also provides a strong construct that improves objective stability. The literature describes other techniques that utilize smaller grafts<sup>15,24,34,38</sup> with improved outcomes.

TABLE 4  
Pre- and Postoperative Outcome Scores for Patients Who Underwent  
Double-Bundle PCL Reconstruction in the Acute or Chronic Phase<sup>a</sup>

Outcome Scale	Score		P Value
	Acute PCL Reconstruction (n = 52)	Chronic PCL Reconstruction (n = 48)	
	Preoperative		
Tegner Activity Scale	1 [0, 3.5]	2 [1, 3]	.222 (MWU)
Lysholm score	41.6 ± 28.6	58.2 ± 17.4	.001 <sup>b</sup> (t test)
WOMAC	48.4 ± 29.7	28.6 ± 22.1	<.001 <sup>b</sup> (t test)
SF-12 PCS	36.8 ± 11.4	38.6 ± 10.4	.407 (t test)
	Postoperative		
Tegner Activity Scale	6 [4, 7]	4 [3, 6]	<.001 <sup>b</sup> (MWU)
Lysholm score	87 [75, 95]	81 [69, 91]	.121 (MWU)
WOMAC	4 [1, 11.5]	7 [2, 16]	.248 (MWU)
SF-12 PCS	56.5 [50.4, 57.8]	51.4 [40.9, 57.7]	.087 (MWU)
Patient satisfaction	10 [9, 10] <sup>c</sup>	8 [5, 10]	.011 <sup>b</sup> (MWU)

<sup>a</sup>Data presented as mean ± SD or median [first quartile, third quartile]. MWU, Mann-Whitney *U* test; PCL, posterior cruciate ligament; SF-12 PCS, 12-item Short Form Health Survey Physical Component Summary; WOMAC, Western Ontario and McMaster Universities Arthritis Index.

<sup>b</sup>*P* < .05.

<sup>c</sup>Mean, 8.1 (range, 1-10).

TABLE 5  
Pre- and Postoperative Outcome Scores for Patients Who Underwent  
Isolated Double-Bundle PCL Reconstruction and Isolated ACL Reconstruction<sup>a</sup>

Outcome Scale	Score		P Value
	Isolated PCL Reconstruction (n = 31)	Isolated ACL Reconstruction (n = 141)	
	Preoperative		
Tegner Activity Scale	2 [1, 3.5]	2 [1, 5]	.575 (MWU)
Lysholm score	57.0 ± 21.7	51.0 ± 23.2	.210 (t test)
WOMAC	31.5 ± 20.7	35.2 ± 23.1 <sup>b</sup>	.411 (t test)
SF-12 PCS	38.2 ± 10.8	40.3 ± 9.7	.306 (t test)
	Postoperative		
Tegner Activity Scale	5 [3, 7]	6 [5, 7]	.064 (MWU)
Lysholm score	87 [70, 95]	91 [84, 95]	.194 (MWU)
WOMAC	3 [1, 13]	2 [0, 6]	.181 (MWU)
SF-12 PCS	56.8 [46.6, 57.8]	56.5 [51.7, 57.8]	.698 (MWU)
Patient satisfaction	9 [6, 10]	9 [7, 10]	.309 (MWU)

<sup>a</sup>Data presented as mean ± SD or median [first quartile, third quartile]. ACL, anterior cruciate ligament; MWU, Mann-Whitney *U* test; PCL, posterior cruciate ligament; SF-12 PCS, 12-item Short Form Health Survey Physical Component Summary; WOMAC, Western Ontario and McMaster Universities Arthritis Index.

<sup>b</sup>[18, 52].

Isolated and combined PCLRs demonstrated no significant differences in outcome scores, despite a trend for poorer scores in the latter group. In recent years, there has been improvement in anatomic PCLRs,<sup>3</sup> supported by biomechanical studies,<sup>17,18</sup> and postoperative rehabilitation and bracing,<sup>21</sup> which potentially explains the observed findings of improved objective and subjective outcomes. A recent systematic review with meta-analysis reported DB PCLR to have superior International Knee Documentation Committee outcomes as compared with single-bundle PCLR.<sup>7</sup> Conversely, Spiridonov et al<sup>35</sup> reported that combined PCL injuries had inferior outcomes

versus isolated PCLR; however, the authors included only 39 patients, as opposed to 100 patients in the present study.

Acute and chronic DB PCLRs revealed no significant differences in the reported outcome scores, except for Tegner scores (*P* < .001) and patient satisfaction (*P* = .011). The mean postoperative SSDs in posterior tibial translation on stress radiographs were 1.9 ± 2.5 mm and 1.2 ± 1.0 mm for acute and chronic PCL tears, respectively. Importantly, >50% of PCL injuries were seen by clinicians >1 year after injury.<sup>30</sup> Although MRI has a high diagnostic accuracy for acute PCL tears (>95%),



the sensitivity in chronic cases is reported to be as low as 62.5%<sup>12</sup> because the ligament tends to heal in an elongated and attenuated condition, which might not be identifiable in MRI scans.<sup>33,36</sup> Use of stress radiographs is therefore fundamental for evaluation to provide proper treatment, which even in chronic cases can yield satisfactory outcomes. Additionally, studies reported that performing ligament reconstruction in a patient with a coronal or sagittal malalignment leads to increased stress on the grafts and thus a higher chance of graft failure.<sup>5,6,13,20,22,37</sup> Thus, long-limb alignment radiographs should be obtained to address alignment disorders before or concurrently with ligament reconstruction.<sup>5,6,37</sup>

With regard to the comparison of isolated PCL and ACL reconstructions, the postoperative outcome scores were comparable. These findings demonstrate that, contrary to previous reports that PCLR produces less predictable results than ACL reconstructions,<sup>23,25</sup> significantly improved outcomes can be achieved with DB PCLRs that are comparable to those of ACL reconstructions. Owesen et al<sup>26</sup> reported that patients undergoing PCLR had the same improvements in Knee injury and Osteoarthritis Outcome Score as patients undergoing ACL reconstruction, although the former had inferior pre- and postoperative scores. Arøen et al<sup>4</sup> reported inferior preoperative scores in PCL- versus ACL-injured knees, using data from the Norwegian registry; however, the present study revealed no significant difference in the preoperative outcome scores between the isolated ACL reconstruction group and the DB PCLR group.

This study has some limitations. An experienced surgeon (R.F.L.) in a tertiary referral center performed all surgical procedures, potentially limiting generalizability. Furthermore, the Lysholm score has a known susceptibility to a ceiling effect, which potentially leads to information loss and reduced statistical power for group comparisons. However, nonparametric statistical tools and bootstrap CIs mitigated this potential bias as much as possible. Additionally, the utilization of biomechanically and clinically validated reconstruction techniques enhanced the external validity of this study.

## CONCLUSION

Significantly improved functional and objective outcomes were observed after anatomic-based DB PCLR at a mean 3 years' follow-up, with low complication rates, regardless of concomitant ligamentous pathology or timing to surgery. Additionally, contrary to previous reports, comparable subjective and functional clinical outcomes were achieved as compared with an isolated ACL reconstruction control cohort.

## REFERENCES

- Ahn S, Lee YS, Song YD, Chang CB, Kang SB, Choi YS. Does surgical reconstruction produce better stability than conservative treatment in the isolated PCL injuries? *Arch Orthop Trauma Surg.* 2016;136(6):811-819.
- American Medical Association, Committee on the Medical Aspects of Sports, Subcommittee on Classification of Sports Injuries. *Standard*

*Nomenclature of Athletic Injuries.* Chicago, IL: American Medical Association; 1966:99-100.

- Anderson CJ, Ziegler CG, Wijdicks CA, Engebretsen L, LaPrade RF. Arthroscopically pertinent anatomy of the anterolateral and posteromedial bundles of the posterior cruciate ligament. *J Bone Joint Surg Am.* 2012;94(21):1936-1945.
- Arøen A, Sivertsen EA, Owesen C, Engebretsen L, Granan LP. An isolated rupture of the posterior cruciate ligament results in reduced preoperative knee function in comparison with an anterior cruciate ligament injury. *Knee Surg Sports Traumatol Arthrosc.* 2013;21(5):1017-1022.
- Arthur A, LaPrade RF, Agel J. Proximal tibial opening wedge osteotomy as the initial treatment for chronic posterolateral corner deficiency in the varus knee: a prospective clinical study. *Am J Sports Med.* 2007;35(11):1844-1850.
- Badhe NP, Forster IW. High tibial osteotomy in knee instability: the rationale of treatment and early results. *Knee Surg Sports Traumatol Arthrosc.* 2002;10(1):38-43.
- Chahla J, Moatshe G, Cinque M, et al. Single-bundle and double-bundle posterior cruciate ligament reconstructions: a systematic review and meta-analysis of 441 patients at a minimum 2 years' follow-up. *Arthroscopy.* 2017;33(11):2066-2080.
- Chahla J, Moatshe G, Cinque ME, Godin J, Mannava S, LaPrade RF. Arthroscopic anatomic single-bundle anterior cruciate ligament reconstruction using bone-patellar tendon-bone autograft: pearls for an accurate reconstruction. *Arthrosc Tech.* 2017;6(4):e1159-e1167.
- Chahla J, Nitri M, Civitaresse D, Dean CS, Moulton SG, LaPrade RF. Anatomic double-bundle posterior cruciate ligament reconstruction. *Arthrosc Tech.* 2016;5(1):e149-e156.
- Chahla J, Serra Cruz R, Cram TR, Dean SC, LaPrade RF. Inside-out meniscal repair: medial and lateral approach. *Arthrosc Tech.* 2016; 5(1):163-168.
- Chahla J, von Bormann R, Engebretsen L, LaPrade RF. Anatomic posterior cruciate ligament reconstruction: state of the art [published online August 17, 2016]. *J ISAKOS.* doi:10.1136/jisakos-2016-000078
- Fischer SP, Fox JM, Del Pizzo W, Friedman MJ, Snyder SJ, Ferkel RD. Accuracy of diagnoses from magnetic resonance imaging of the knee: a multi-center analysis of one thousand and fourteen patients. *J Bone Joint Surg Am.* 1991;73(1):2-10.
- Gaskill TR, Pierce CM, James EW, LaPrade RF. Anterolateral proximal tibial opening wedge osteotomy to treat symptomatic genu recurvatum with valgus alignment: a case report. *JBJS Case Connect.* 2014;4(3):e71-e75.
- Geeslin AG, LaPrade RF. Outcomes of treatment of acute grade-III isolated and combined posterolateral knee injuries: a prospective case series and surgical technique. *J Bone Joint Surg Am.* 2011;93(18):1672-1683.
- Hatayama K, Higuchi H, Kimura M, Kobayashi Y, Asagumo H, Takagishi K. A comparison of arthroscopic single- and double-bundle posterior cruciate ligament reconstruction: review of 20 cases. *Am J Orthop (Belle Mead NJ).* 2006;35(12):568-571.
- Jackman T, LaPrade RF, Pontinen T, Lender PA. Intraobserver and interobserver reliability of the kneeling technique of stress radiography for the evaluation of posterior knee laxity. *Am J Sports Med.* 2008;36(8):1571-1576.
- Kennedy NI, LaPrade RF, Goldsmith MT, et al. Posterior cruciate ligament graft fixation angles, part 1: biomechanical evaluation for anatomic single-bundle reconstruction. *Am J Sports Med.* 2014; 42(10):2338-2345.
- Kennedy NI, LaPrade RF, Goldsmith MT, et al. Posterior cruciate ligament graft fixation angles, part 2: biomechanical evaluation for anatomic double-bundle reconstruction. *Am J Sports Med.* 2014; 42(10):2346-2355.
- LaPrade CM, Civitaresse DM, Rasmussen MT, LaPrade RF. Emerging updates on the posterior cruciate ligament: a review of the current literature. *Am J Sports Med.* 2015;43(12):3077-3092.
- LaPrade RF, Oro FB, Ziegler CG, Wijdicks CA, Walsh MP. Patellar height and tibial slope after opening-wedge proximal tibial osteotomy: a prospective study. *Am J Sports Med.* 2010;38(1):160-170.

21. LaPrade RF, Smith SD, Wilson KJ, Wijdicks CA. Quantification of functional brace forces for posterior cruciate ligament injuries on the knee joint: an in vivo investigation. *Knee Surg Sports Traumatol Arthrosc.* 2015;23(10):3070-3076.
22. LaPrade RF, Spiridonov SI, Nystrom LM, Jansson KS. Prospective outcomes of young and middle-aged adults with medial compartment osteoarthritis treated with a proximal tibial opening wedge osteotomy. *Arthroscopy.* 2012;28(3):354-364.
23. Lenschow S, Zantop T, Weimann A, et al. Joint kinematics and in situ forces after single bundle PCL reconstruction: a graft placed at the center of the femoral attachment does not restore normal posterior laxity. *Arch Orthop Trauma Surg.* 2006;126(4):253-259.
24. Li Y, Li J, Wang J, Gao S, Zhang Y. Comparison of single-bundle and double-bundle isolated posterior cruciate ligament reconstruction with allograft: a prospective, randomized study. *Arthroscopy.* 2014;30(6):695-700.
25. Matava MJ, Ellis E, Gruber B. Surgical treatment of posterior cruciate ligament tears: an evolving technique. *J Am Acad Orthop Surg.* 2009;17(7):435-446.
26. Owesen C, Sandven-Thrane S, Lind M, Forssblad M, Granan LP, Aroen A. Epidemiology of surgically treated posterior cruciate ligament injuries in Scandinavia. *Knee Surg Sports Traumatol Arthrosc.* 2017;25(8):2384-2391.
27. Pierce CM, O'Brien L, Griffin LW, LaPrade RF. Posterior cruciate ligament tears: functional and postoperative rehabilitation. *Knee Surg Sports Traumatol Arthrosc.* 2013;21(5):1071-1084.
28. *R: A Language and Environment for Statistical Computing* [computer program]. Vienna, Austria: R Foundation for Statistical Computing; 2010.
29. Sanders TL, Pareek A, Barrett IJ, et al. Incidence and long-term follow-up of isolated posterior cruciate ligament tears. *Knee Surg Sports Traumatol Arthrosc.* 2017;25(10):3017-3023.
30. Schulz MS, Russe K, Weiler A, Eichhorn HJ, Strobel MJ. Epidemiology of posterior cruciate ligament injuries. *Arch Orthop Trauma Surg.* 2003;123(4):186-191.
31. Serra Cruz R, Mitchell JJ, Dean CS, Chahla J, Moatshe G, LaPrade RF. Anatomic posterolateral corner reconstruction. *Arthrosc Tech.* 2016;5(3):e563-e572.
32. Serra Cruz R, Olivetto J, Dean CS, Chahla J, LaPrade RF. Superficial medial collateral ligament of the knee: anatomic augmentation with semitendinosus and gracilis tendon autografts. *Arthrosc Tech.* 2016;5(2):347-352.
33. Shelbourne KD, Davis TJ, Patel DV. The natural history of acute, isolated, nonoperatively treated posterior cruciate ligament injuries: a prospective study. *Am J Sports Med.* 1999;27(3):276-283.
34. Shon OJ, Lee DC, Park CH, Kim WH, Jung KA. A comparison of arthroscopically assisted single and double bundle tibial inlay reconstruction for isolated posterior cruciate ligament injury. *Clin Orthop Surg.* 2010;2(2):76-84.
35. Spiridonov SI, Slinkard NJ, LaPrade RF. Isolated and combined grade-III posterior cruciate ligament tears treated with double-bundle reconstruction with use of endoscopically placed femoral tunnels and grafts: operative technique and clinical outcomes. *J Bone Joint Surg Am.* 2011;93(19):1773-1780.
36. Tewes DP, Fritts HM, Fields RD, Quick DC, Buss DD. Chronically injured posterior cruciate ligament: magnetic resonance imaging. *Clin Orthop Relat Res.* 1997;335:224-232.
37. van de Pol GJ, Arnold MP, Verdonchot N, van Kampen A. Varus alignment leads to increased forces in the anterior cruciate ligament. *Am J Sports Med.* 2009;37(3):481-487.
38. Wang CJ, Weng LH, Hsu CC, Chan YS. Arthroscopic single- versus double-bundle posterior cruciate ligament reconstructions using hamstring autograft. *Injury.* 2004;35(12):1293-1299.