

### Principles That Will Improve Your Physical Examination



Following is an excerpt from one of sports medicine's finest, Dr. John A. Feagin, on principles that will improve your physical examination. Historically, doctors diagnosed different pathologies using their own senses, by poking, prodding, looking, and listening. From all these observations, a skilled doctor could interpret a patient's symptoms and physical signs to ultimately arrive at an extraordinarily accurate suspicion about what ailed the patient. With the advent of modern technologies, many physicians are abbreviating the time-honored physical examination<sup>1</sup> or even skipping it altogether. In this regard, a sports medicine legend, Dr. Feagin, preaches about how precise our hands can be with the appropriate training (being able to detect millimeters of anterior tibial translation in an anterior cruciate ligament injury or the location of the exact point of pain in a meniscus tear).<sup>2</sup> This letter is intended to emphasize the need and the significance of the first point of contact with our patients, which in most cases is vital for developing a solid attending-patient relation.

In the following paragraphs, Dr. Feagin emphasizes in his own words the importance of the initial evaluation of the patient. The physical examination is the point of contact for most of our patient interactions.<sup>3</sup> As such, an organized, patient-centric approach can enhance our effectiveness as physicians and improve bilateral communication.<sup>4</sup> Although attention is being more and more centered on improving the outcomes associated with medical treatment, an accurate diagnosis is the key part of the treatment pipeline that guides the content and timing of the treatment<sup>5</sup> and may be considered the "value on the front end" that optimizes the overall treatment process. There is much evidence in orthopaedics that deficiencies exist and often limit the implementation of the most beneficial treatments.<sup>6</sup> The Institute of Medicine acknowledged the significance of the initial diagnosis in health care and consequently the urge to improve a doctor's diagnostic skills.<sup>7</sup> To effectively collect important information about different knee pathologies, a description of the definable and describable principles that lead to more efficient and effective patient care is presented herein.

#### History

The history is an implicit part of the physical examination. The history guides us to a diagnostic category, which in turn dictates the specific clinical examination to

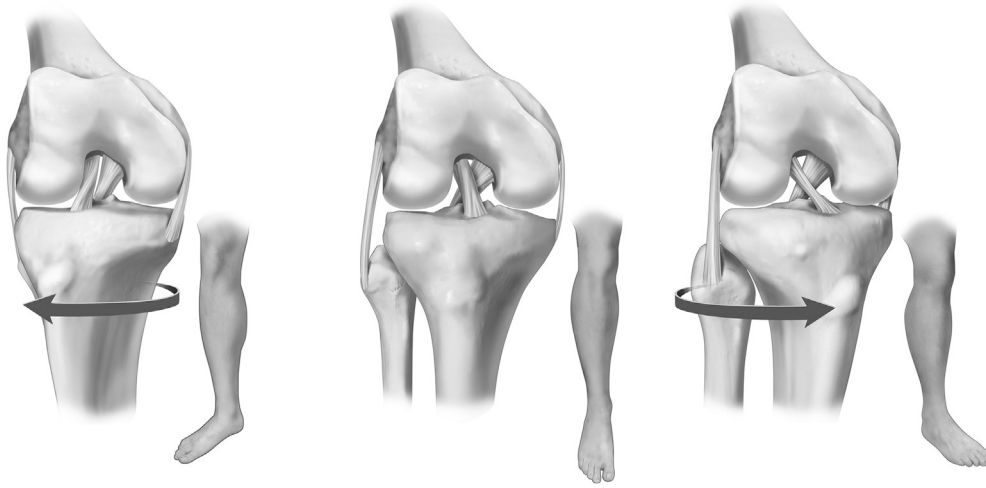
be performed. The history should be brief and concise, and the patient should never be interrupted. The simplest, most effective questions we have found to elicit a meaningful history are as follows: (1) The patient with an acute knee injury is asked to "describe what happened to your knee." (2) The patient with a chronic knee problem is asked to "tell me all about your knee."

Once the patient has initiated the response to the question, we usually begin an observation and then a gentle palpable examination of the well knee. The normal contour is thus defined, as well as the anatomy, the temperature, and the tissue tension. The sense of one's touch is a signal to the patient of the doctor's concern. When the patient has finished providing the history, we proceed to explain to him or her that the examination of the well knee is going to be performed so that we have a point of comparison for the injured or symptomatic knee.

#### Positions for Examination

We usually begin the examination in the position in which we find the patient, because we assume that this is either the position of comfort or the position they ended up in after injury. Three positions are effective in defining the full extent of the pathology, with an optional fourth position.

1. The first position is the sitting position with the legs dangling because this is so often the way the patient is found in an office practice. This position is usually comfortable, puts distraction or gravity on the examiner's side in the examination, and leaves the distal segment with 6 degrees of freedom. Also, this position allows us to examine the anterior and posterior cruciate ligaments first and thus establish the primary ligamentous knee restraints before seeking the secondary restraints (Fig 1).
2. The second position, which has historically served us well, is the figure-of-4 position. Herein, it is especially important that you have examined the well leg first. In the figure-of-4 position, the medial meniscus will extrude if there is pathology within the meniscus; the medial collateral ligament and the posterior oblique ligaments are palpable; and laterally, the fibular collateral ligament is palpable and well posterior. The lateral border of the patellar tendon is palpable and so is the anterolateral ligament. The lateral meniscus is

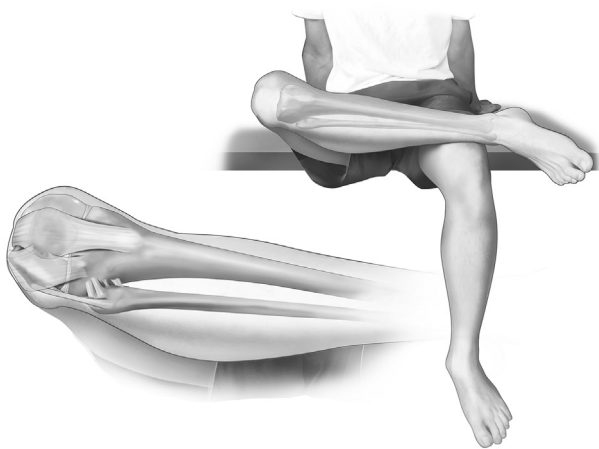

**Fig 1.** Hip and knee flexed 90°; tibia externally rotated (left), in neutral position (center), and internally rotated (right). Note tightening of the cruciates with internal rotation.

thus “uncovered,” and if palpable or tender, it is abnormal because it should be well retracted in this position. The patella is buried deep in the trochlear groove, its ligaments are taut and palpable, and it should be stable and centered (Fig 2).

3. The third position is the supine position; it allows a comparison between flexion and extension, an effective varus-valgus test, a pivot-shift test, and hip motion, which may be ascertained as part of the knee examination (Fig 3).
4. The fourth position, which is optional, is the prone position. In this position, full extension is easier to compare with the contralateral well knee and the quadriceps is relaxed, allowing for more effective Lachman and posterior displacement tests and a patellofemoral examination that can include displacement as well as containment through a range of motion (Fig 4).

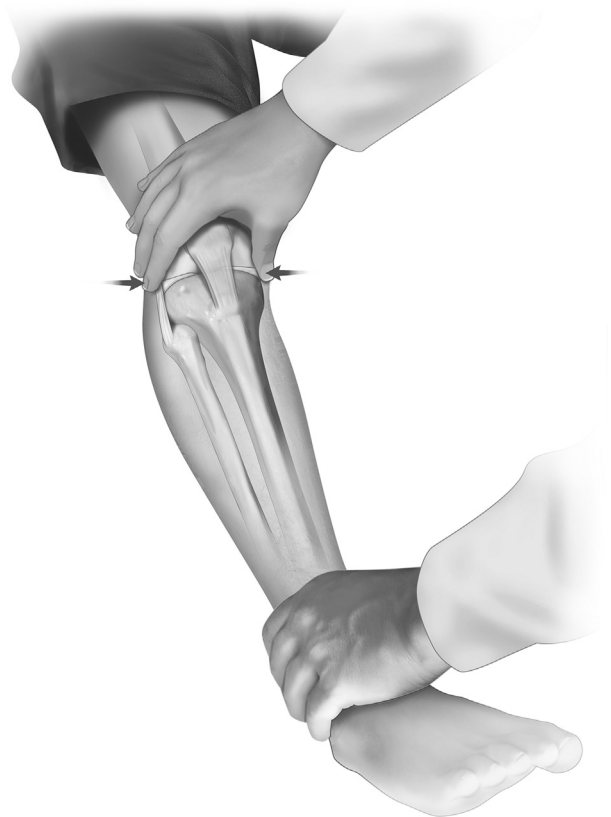
During the performance of the physical examination, we explain to the patient what we are examining and what are we finding. Thus, the physical examination is



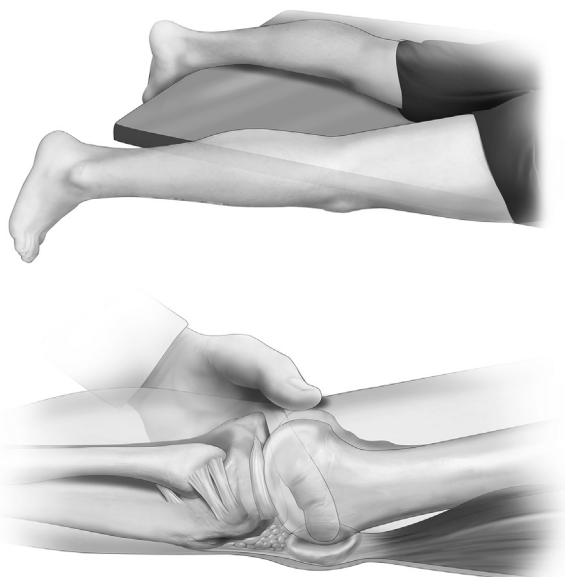
**Fig 2.** The figure-of-4 position (top image). Schematic drawing of the relation of anatomic structures on the bottom image.

an integral, important, and effective part of communication with the patient.

After the physical examination, it is usual to review the imaging findings with the patient. His or her understanding of the imaging discussion is enhanced by the communication during the physical examination.



**Fig 3.** A varus-valgus test should be performed in the supine position, at 20° to 30° of knee flexion for evaluation of the collateral ligaments (medial collateral ligament in valgus and fibular collateral ligament in varus) and at extension to evaluate the posterior elements of the medial and lateral complex (posterior oblique ligament and compromise of the posterolateral corner).



**Fig 4.** The prone position (top image) is particularly helpful in examination of the patella. The examiner can determine the tenderness along the capsule as well as the swelling and/or tenderness of the fat pad and the inferior capsular ligaments (bottom image).

Finally, this is an opportunity for the patient to ask any questions and advocate for himself or herself (family members or support personnel are encouraged to add advocacy also). This is critical. After this, one can summarize the diagnosis and recommendations in the context of the patient's diagnosis and needs.

We hope this detailed explanation of the principles and technique of examination of the knee is helpful to all clinicians. It has served me well in almost 60 years of orthopaedics.

John A. Feagin, M.D.  
Durham, North Carolina

These important details on the collection of information during the history and physical examination are as true today as they were back in the 1970s when the use of an arthroscope and magnetic resonance imaging were still future dreams. Dr. Feagin is still recognized as one of the world's experts on the details of the knee physical examination, and his wise advice is even more important to our current generation of physicians, as well as physicians to be, as we strive to provide the best care possible to our patients.

Jorge Chahla, M.D., Ph.D.  
Santa Monica, California

Robert F. LaPrade, M.D., Ph.D.  
Vail, Colorado

**Note:** The authors report the following potential conflict of interest or source of funding: R.F.L. receives

support from Arthrex; Smith & Nephew; Ossur; Health East, Norway; NIH R-13 grant for biologics. Institution provided support by Arthrex, Ossur, Siemens, and Smith & Nephew. Full ICMJE author disclosure forms are available for this article online, as [supplementary material](#).

© 2017 by the Arthroscopy Association of North America  
<https://doi.org/10.1016/j.arthro.2017.10.001>

## References

1. Stansfield RB, Diponio L, Craig C, et al. Assessing musculoskeletal examination skills and diagnostic reasoning of 4th year medical students using a novel objective structured clinical exam. *BMC Med Educ* 2016;16:268.
2. Feagin JA. *The crucial ligaments: Diagnosis and treatment of ligamentous injuries about the knee*. Philadelphia: Churchill Livingstone, 1988.
3. Chivers MD, Howitt SD. Anatomy and physical examination of the knee menisci: a narrative review of the orthopedic literature. *J Can Chiropr Assoc* 2009;53:319-333.
4. Bunting RF Jr, Groszkruger DP. From to err is human to improving diagnosis in health care: The risk management perspective. *J Healthc Risk Manag* 2016;35:10-23.
5. Manske RC, Prohaska D. Physical examination and imaging of the acute multiple ligament knee injury. *N Am J Sports Phys Ther* 2008;3:191-197.
6. Kibler WB. Value on the front end: Making the effective diagnosis for optimal treatment. *Arthroscopy* 2017;33:493-495.
7. National Academies of Sciences, Engineering, and Medicine. *Improving diagnosis in health care*. Washington, DC: National Academies Press, 2016.

## Regarding “Hip and Anterior Cruciate Ligament Crossroads”



The orthopaedic community has been at a crossroads when faced with the growing acceptance of the relation between restricted hip mobility, mainly internal rotation, and anterior cruciate ligament (ACL) tears as described by Dr. Harris.<sup>1</sup> Since we reported this problem<sup>2-6</sup> the same questions came to our minds about prophylactic measures that could be more effective in preventing ACL injuries in patients with identified hip restriction. Arthroscopic hip resection of femoroacetabular impingement in asymptomatic individuals is a risky decision, especially in high-level athletes. Although we were lucky in avoiding iatrogenic hip pain in our study group of young soccer players, no real benefit was observed following a year of our stretching program directed at improving hip range of motion.<sup>7</sup> With abrupt movements such as a quick turn to the right side with the right foot planted onto the floor during dribbling, the pelvis imposes a femoral external