

Meniscal root tears: a silent epidemic

Mark E Cinque,¹ Jorge Chahla,¹ Gilbert Moatshe,^{1,2,3} Scott C Faucett,⁴ Aaron J Krych,⁵ Robert F LaPrade^{1,6}

THE CLINICAL PROBLEM

Half of adults will experience knee pain at some point during their lives, resulting in approximately 4 million primary care office visits in the USA annually.¹ The majority of these visits for knee pain evaluation are due to osteoarthritis (OA).² As of 2015, it was estimated that 14 million people in the USA have symptomatic knee OA,³ and this number is expected to increase to up to 28 million over the next decade.⁴ One of the most common factors that can initiate the cascade of knee OA is meniscus tears.⁵

Meniscus root tears are a specific type of meniscal injury that have gained attention over the past 5 years and have been reported to account for 10%–21% of all meniscal tears, affecting nearly 100 000 patients annually.^{6–8} Untreated meniscal root tears have been reported to result in altered joint biomechanics and accelerated articular cartilage degeneration. In this regard, the ‘recently’ recognised pathology of meniscal root tears has been reported to precipitously worsen articular cartilage degeneration (figure 1), cause painful bone oedema and lead to progressive OA (figure 2) if left untreated.^{9–13} Furthermore, it is important to recognise the association of meniscal injuries leading to subchondral insufficiency and potentially spontaneous osteonecrosis of the knee (SONK). Previously, SONK was a pathology often diagnosed as an ‘idiopathic’ osteonecrosis of the knee prior to the recognition that this pathology was caused by a meniscal tear.^{9 13–15} However, the pathogenesis of SONK continues to be debated in the literature with many aetiologies, including certain meniscal tears and meniscectomy, reported to be the primary cause of insufficiency fracture

development. It was recently reported that the term SONK is a misrepresentation of the aetiology and pathogenesis of the condition, and should be replaced with ‘subchondral insufficiency fractures of the knee’ (SIFK).¹⁶

Early detection of degenerative root tears in patients over 50 years old is crucial, because knee joint loading can be restored to a near native state if this lesion is properly diagnosed and timely treated,¹⁷ and the progression of OA can be significantly slowed.^{18 19} It is also important to actively look for acute root tears in patients with multiligament knee injuries and ACL tears because of the increased risk of root tears in these patient populations. Thus, the purpose of this clinical practice work, given the drastic and costly downstream effects of untreated meniscal root tears progressing to OA for both patients and society, is to note that significant attention should be directed towards this ‘silent epidemic,’ and therefore it is important that all physicians recognise this pathology.

STRATEGIES AND EVIDENCE

Pathophysiology

Meniscal root tears are defined either as an avulsion of the insertion of the meniscus attachment or complete radial tears that are located within 1 cm of the meniscus insertion.^{10 20} Meniscal root tears have been previously classified into five types²¹: (1) partial root tear, (2) complete radial root tear, (3) complete root tear with a bucket handle meniscus tear, (4) oblique tear into the root attachment and (5) root avulsion fracture (figure 3). Due to the recent recognition of the effects of this pathology, there has been a recent emphasis to characterise the effects of meniscal root tears including an early diagnosis of this pathology, biomechanical consequences of root tears, optimal techniques for root repairs and overall long-term outcomes.

Biomechanical studies have demonstrated that meniscal root injuries interrupt the continuity of the circumferential fibres, and hence lead to failure of the normal meniscal function to convert axial loads into transverse hoop stresses.^{10 17 22–24} A root tear effectively results in a disruption of its attachment and can lead to meniscal extrusion, which results in increased intra-articular pressure on the medial and lateral knee compartments during joint loading

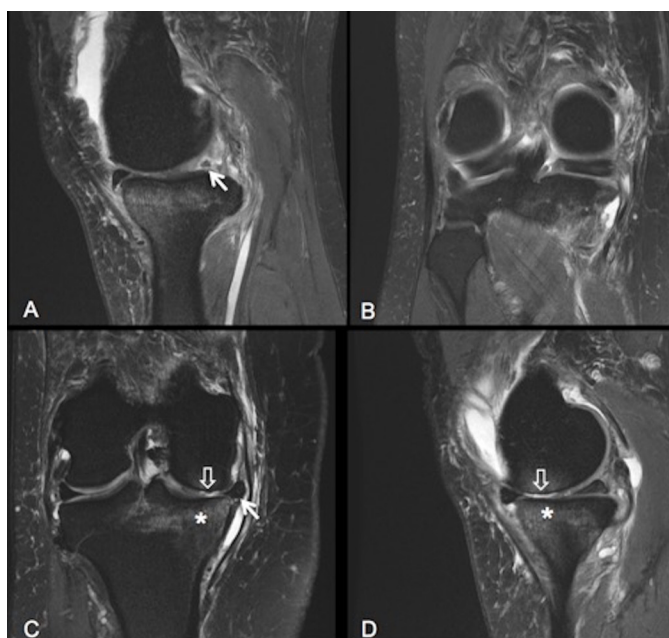


Figure 1 Sagittal (A) and coronal (B) fast spin echo (FSE) T2-weighted fat suppression images show the oblique tear of the posterior horn of the medial meniscus extending into the root attachment (white arrow). Coronal (C) and sagittal (D) FSE T2-weighted fat suppression images show the peripheral meniscal extrusion at the medial joint line (arrow), grade IV chondromalacia (block arrow) and subchondral marrow oedema (asterisk).

¹Steadman Philippon Research Institute, Vail, Colorado, USA

²Oslo University Hospital, Oslo, Norway

³OSTRC, Norwegian School of Sports Sciences, Oslo, Norway

⁴Centers for Advanced Orthopaedics, Washington, District of Columbia, USA

⁵Orthopedic Surgery and Sports Medicine, Mayo Clinic, Rochester, Minnesota, USA

⁶The Steadman Clinic, Vail, Colorado, USA

Correspondence to Dr. Robert F LaPrade; rlaprade@thesteadmanclinic.com

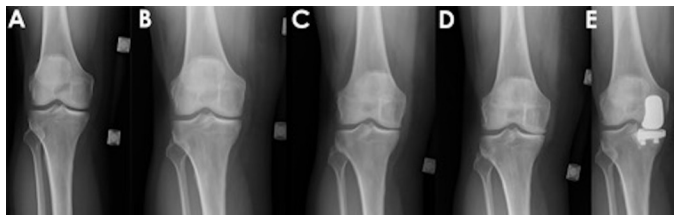


Figure 2 (A–E) Right knee plain radiographs' sequence demonstrating the natural history of a medial compartment with an unrepaired posterior medial meniscal root tear over a period of 12 months with progressive medial compartment joint space narrowing and ultimately a conversion to a medial compartment hemiarthroplasty.

(figure 4),^{17 25} which ultimately can lead to arthritis. Increased joint contact pressure over time is detrimental to both the articular cartilage and underlying supporting bone and can lead to rapid degenerative changes, which are comparable with the arthritic changes seen following a total meniscectomy.¹⁰ The deleterious effects of a meniscectomy have long been known since Fairbank reported in 1948 increased degenerative changes in knees that had undergone meniscectomy.²⁶

Medial meniscus root repair

To restore the function of the meniscus after medial meniscus root tears, a transosseous meniscal root repair technique is most commonly used and involves the passing of two simple sutures through the meniscal root tear edge and tunnels

in the proximal tibia (figure 5).^{14 27 28} After passing the repair sutures through the two tibial tunnels, the sutures are then tied over a bone bridge or a surgical button^{14 29 30} (figure 5). The two-tunnel repair technique allows for a higher ultimate load to failure, a broader anatomical footprint and the release of biological factors to enhance healing of the meniscal root repair.^{17 31–37} The advantage of this technique is the ability to reduce and fix the meniscal root to the broad anatomical footprint to maximise its healing potential.¹⁷ In addition, the transtibial tunnels may contribute to the release of biological factors that can enhance the healing of the meniscal root repair.^{33–37}

Clinical evidence

The important findings in the biomechanical studies of the effects of meniscal root

tears on joint contact loads^{10 17 21 23–25} have been supported by clinical studies. Chung *et al*³⁸ reported that medial meniscal root repairs slowed the progression of intra-articular arthritic changes compared with patients who underwent a partial meniscectomy.³⁸ Along with the overall difference in arthritic changes, 35% of the patients who had undergone a meniscectomy to treat a meniscal root tear underwent conversion to total knee arthroplasty (TKA) by 5-year follow-up, whereas none of the patients who had undergone a meniscal root repair underwent conversion to TKA.³⁸ To further support the importance of recognising and repairing meniscal root tears, Krych *et al*³⁹ reported poor clinical outcomes, worsening of OA and a 31% conversion to arthroplasty in 52 patients treated conservatively for posterior root tears at a mean follow-up of 5 years.

In a study of 197 consecutive TKAs, 92.8% of patients under 60 years had a meniscal root tear as a primary identified factor leading to the development of OA.⁴⁰ The potential for early progression to knee OA, resulting in TKA, after a meniscal root tear treated non-operatively or with meniscectomy, has large implications given the US\$57 900 overall cost of a TKA. Moreover, studies have indicated that indirect costs associated with TKA can grow to as much as US\$68 000 per patient, increasing the economic burden on the patient and the overall healthcare infrastructure. In this regard, Krych *et al* reported that the 16 patients (31%) with untreated meniscal root tears that underwent conversion to TKA by 5-year follow-up resulted in a US\$1.1 million direct cost to society.³⁹ Although TKA is a cost-effective treatment when compared with non-operative management for end-stage OA, treating medial meniscal root tears conservatively or with meniscectomy will likely accelerate the rise in the projected volume of TKA cases, putting further strain on the US healthcare system due to the increased costs. This is particularly important because OA caused by meniscal root tears can be prevented by early diagnosis and treatment.

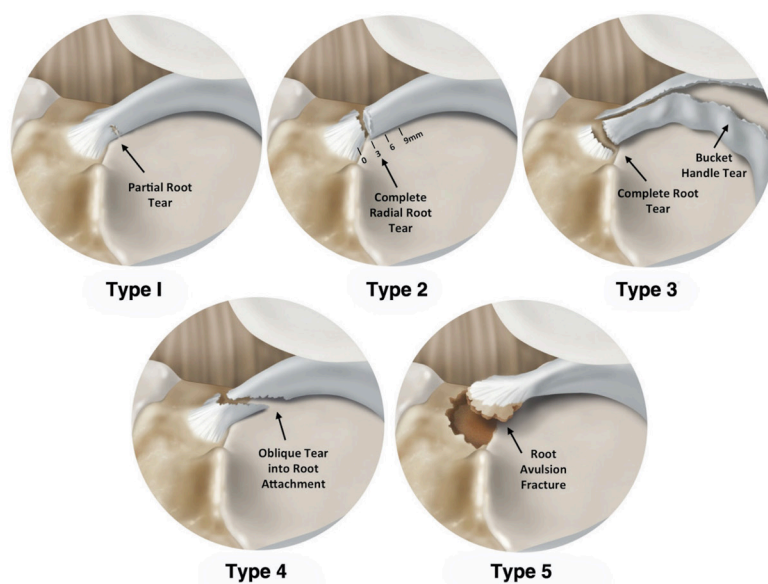


Figure 3 Illustrations of the meniscal root tear classification system in five different groups based on tear morphology. All meniscal tears are shown as medial meniscal posterior root tears for consistency in this illustration. The five tear patterns were classified based on morphology: partial stable root tear (type 1), complete radial tear within 9 mm from the bony root attachment (type 2), bucket-handle tear with complete root detachment (type 3), complex oblique or longitudinal tear with complete root detachment (type 4) and bony avulsion fracture of the root attachment (type 5). Reproduced with permission from LaPrade *et al*.²¹

KEY SURGICAL CONSIDERATIONS

It is important to repair the posterior medial meniscal root tear at its anatomical attachment site to restore normal joint loading profiles. Biomechanical studies have reported that a 3 mm non-anatomical displacement significantly alters meniscal function by failing to restore joint loading and contact areas.^{41 42} This

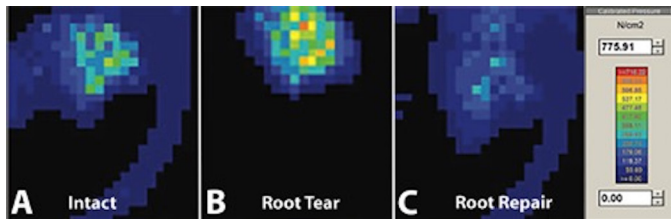


Figure 4 Representative Tekscan contact area and pressure maps of the medial and lateral compartments of a cadaveric specimen at 30° of flexion undergoing nine medial meniscus root tear and repair conditions. Root tears are noted to induce high pressures (indicated by the yellow and red colours), while root repairs significantly restore joint contact loads (blue and purple). Reproduced with permission from Padalecki *et al.*¹⁷

has been supported by clinical findings that meniscal extrusion >3 mm was associated with degenerative changes in the joint.¹² Other potential problems have been reported with the current repair techniques. These include the overall repair construct strength and a risk of meniscal repair displacement with early weight bearing.^{32 43}

AREAS OF UNCERTAINTY

Repairs of posterior medial meniscal root tears have been reported to improve clinical outcomes and slow the progression of OA.^{18 28 38 44} However, these studies have also demonstrated that the progression to OA is not completely diminished, which may reflect poor patient selection for

repair in some circumstances. Patients with obesity (body mass index (BMI) >30), uncorrected malalignment or advanced cartilage changes at the time of presentation may not benefit from root repair.⁴⁵ In addition, non-anatomical repair of the meniscal root does not properly restore contact forces in the joint.⁴² Furthermore, poor healing and cyclic displacement during loading can lead to the suture repair loosening and can cause meniscal extrusion, and can lead to an ineffective transmission of the hoop stress function of the meniscus and in turn negate the beneficial effects of a root repair.

In a recent systematic review of the outcomes of posterior medial meniscal root repairs, MRI examination demonstrated that medial meniscus extrusion was reduced in only 56% of the patients. In addition, second-look arthroscopy demonstrated that the healing status was complete in 62%, partial in 34% and failed in 3%.¹⁸ In addition, in a recent study, clinical outcomes were correlated with reduction of meniscus extrusion.¹⁹ Thus, improved root repair techniques with reduction of meniscal extrusion should be pursued to improve patient outcomes.

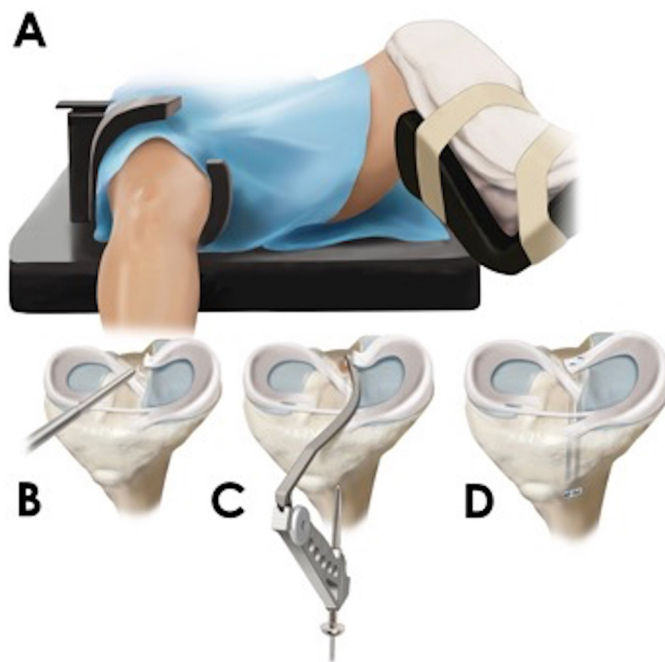


Figure 5 Technique of a transtibial meniscal root repair. The patient is placed in the supine position on the operating table (A). Standard anterolateral and anteromedial portals are created and the root tear is assessed with a probe for its severity and tear pattern. An accessory posteromedial portal is created to access the meniscal root and an arthroscopic grasper is used to mobilise the root and to determine the ideal location for repair (B). For a posterior medial root tear, an initial incision for the transtibial tunnels is made just medial to the tibial tubercle. Two transtibial tunnels are created at the location of the root with the use of a cannulated aiming device to position a drill pin with a cannulated sleeve (C). A suture-passing device is passed through the far posterior portion of the detached meniscal root, approximately 5 mm medial to its lateral edge, passing from the tibial to the femoral side. Before passing the second suture through the meniscus, the first suture is shuttled down through the more posteriorly placed tibial tunnel to avoid intra-articular suture tangling. The same steps are repeated with the second suture positioned through the mid-portion of the meniscal root, anterior to the first suture placed into the meniscus. The second suture is then pulled down through the anterior positioned tibial cannula. The sutures are tied over a cortical fixation device on the anteromedial tibia with the knee flexed to 90° (D).

GUIDELINES

A history of sudden posterior knee pain, especially after deep knee flexion or squatting, should alert the clinician to the possibility of a meniscus root tear (figure 6). Most patients with meniscal root injuries recall a precise time point when their knee pain began, and it often occurs with a minor traumatic event such as squatting.¹⁴ The most common presenting symptoms in meniscal root tears are posterior knee pain and joint line tenderness, especially with deep squatting.⁴⁶ Another common symptom is a popping sound that is heard while participating in light activities, like ascending stairs or squatting.⁴⁷ Seil *et al*⁴⁸ described a test that has proven useful in diagnosing a medial meniscal root tear. It involves applying a varus stress to the knee while it is relaxed and in full extension and palpating the anteromedial joint line.⁴⁸ When there is a medial meniscal root avulsion, meniscal extrusion may be palpated at the medial joint line and the extrusion disappears when the knee is moved back to its normal anatomical position.⁴⁸ In addition, when performing a physical exam, it is important to identify if the patient has varus alignment or a high BMI because these have also been

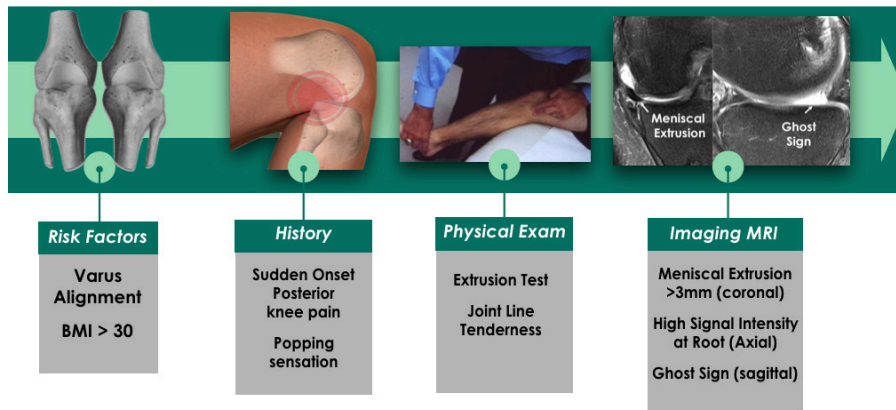


Figure 6 Flow chart describing the evaluation for a meniscal root tear. BMI, body mass index.

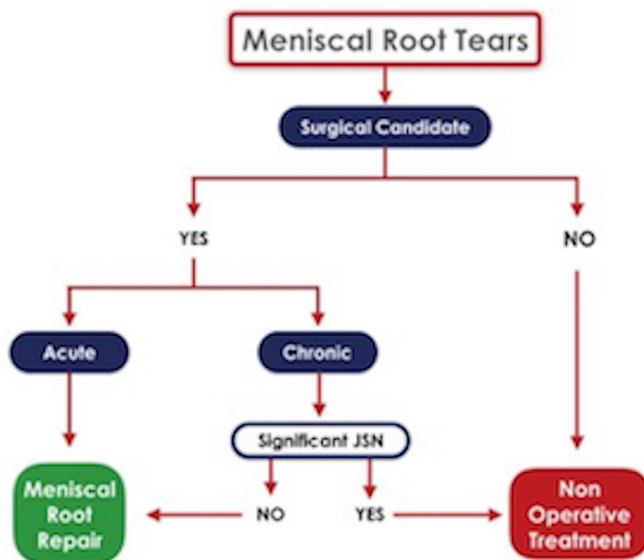


Figure 7 Flow chart demonstrating the different treatment options and patient selection criteria for a patient that is diagnosed with a meniscus root tear. Adapted with permission from Bhatia *et al.*¹⁴ JSN, joint space narrowing.

reported to be significant risk factors for medial meniscal root tears⁴⁵

Positive physical exam signs should raise suspicion for a meniscal root tear and the clinician should consider ordering an MRI or a referral to a specialist. However, full length alignment, Antero-Posterior (AP) and knee flexion (Rosenberg) weight-bearing radiographs should always be ordered prior to ordering an MRI to assess the severity of the joint space narrowing and other degenerative signs. When the history and physical exam are suggestive of a meniscal root tear and there is sufficient medial compartment articular cartilage remaining, an MRI should be indicated. A physical exam consistent with a root tear should be combined with an MRI since many meniscal root tears are missed by physical examination alone.⁴⁹ MRI signs of medial meniscus root tears include (1) medial meniscal extrusion of ≥ 3 mm in a

coronal section; (2) high signal indicating a disruption of the posterior meniscal root region in an axial view; and (3) a 'ghost sign', which is the absence of an identifiable meniscus in the sagittal plane, or increased signal replacing the normally dark meniscal tissue signal at the posterior root attachment (Figure 2). Because there is no specific physical examination specific for a meniscal root tear, when the history and physical exam are suggestive of a meniscal tear and there is sufficient medial compartment joint space remaining on weight-bearing radiographs, an MRI is indicated. Medial meniscal extrusions greater than 3 mm have been reported to be significantly associated with severe meniscal degeneration and meniscal root tears.⁴⁴ Meniscal extrusion and therefore a meniscal root tear can also be suspected with ultrasound examination. Meniscus extrusion, however, is not pathognomonic for a root tear, because

other meniscus or articular cartilage pathologies can cause extrusion.⁵⁰

TREATMENT RECOMMENDATIONS

The first key to successful treatment is to recognise the presence of a meniscus root tear. A clinician must maintain a high level of suspicion and obtain a knee MRI early in the clinical course when appropriate and before the rapid progression of arthritis initiates. Non-operative treatment is recommended for patients with significant comorbidities and those with advanced OA (Kellgren-Lawrence grade ≥ 3) on radiographs. For this subset of patients, symptomatic treatment with analgesics and a medial compartment unloader brace can help alleviate the symptomatology. For patients who progress to knee OA and fail non-operative treatment, a partial or TKA can be considered.

Active patients, regardless of age, should be referred early and considered for a meniscal root repair. Indications for a meniscal root repair include acute, traumatic root tears in patients with nearly normal or normal cartilage and chronic symptomatic root tears in young or middle-aged patients without significant pre-existing OA (figure 7). Meniscal root repair has been demonstrated to have high satisfaction rates and superior outcomes than arthroscopic meniscectomy for root tears.^{6 10 11 44 51 52} Early referral of these patients for surgery had been demonstrated to significantly decrease the progression of knee OA and the requirement for TKA at mid-term follow-up.^{14 38 39}

Contributors All authors contributed equally to this work.

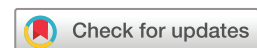Funding This research received no specific grant from any funding agency in the public, commercial or not-for-profit sectors.

Competing interests None declared.

Patient consent Not required.

Provenance and peer review Not commissioned; externally peer reviewed.

© Article author(s) (or their employer(s) unless otherwise stated in the text of the article) 2018. All rights reserved. No commercial use is permitted unless otherwise expressly granted.



To cite Cinque ME, Chahla J, Moatshe G, *et al.* *Br J Sports Med* Epub ahead of print: [please include Day Month Year]. doi:10.1136/bjsports-2017-098942

Accepted 20 February 2018

Br J Sports Med 2018;0:1–5.
doi:10.1136/bjsports-2017-098942

REFERENCES

- Baker P, Reading I, Cooper C, *et al.* Knee disorders in the general population and their relation to occupation. *Occup Environ Med* 2003;60:794–7.
- Grover M. Evaluating acutely injured patients for internal derangement of the knee. *Am Fam Physician* 2012;85:247–52.
- Deshpande BR, Katz JN, Solomon DH, *et al.* Number of Persons With Symptomatic Knee Osteoarthritis in the US: Impact of Race and Ethnicity, Age, Sex, and Obesity. *Arthritis Care Res* 2016;68:1743–50.
- Centers for Disease Control and Prevention (CDC). Prevalence of doctor-diagnosed arthritis and arthritis-attributable activity limitation—United States, 2010–2012. *MMWR Morb Mortal Wkly Rep* 2013;62:869–73.
- Badlani JT, Borrero C, Golla S, *et al.* The effects of meniscus injury on the development of knee osteoarthritis: data from the osteoarthritis initiative. *Am J Sports Med* 2013;41:1238–44.
- Bonasia DE, Pellegrino P, D'Amelio A, *et al.* Meniscal Root Tear Repair: Why, When and How? *Orthopedic Reviews* 2015.2.
- LaPrade RF, Ho CP, James E, *et al.* Diagnostic accuracy of 3.0 T magnetic resonance imaging for the detection of meniscus posterior root pathology. *Knee Surg Sports Traumatol Arthrosc* 2015;23:152–7.
- Sihvonen R, Paavola M, Malmivaara A, *et al.* Arthroscopic partial meniscectomy versus sham surgery for a degenerative meniscal tear. *N Engl J Med* 2013;369:2515–24.
- Robertson DD, Armfield DR, Towers JD, *et al.* Meniscal root injury and spontaneous osteonecrosis of the knee: an observation. *J Bone Joint Surg Br* 2009;91:190–5.
- Allaire R, Muriuki M, Gilbertson L, *et al.* Biomechanical consequences of a tear of the posterior root of the medial meniscus. Similar to total meniscectomy. *J Bone Joint Surg Am* 2008;90:1922–31.
- Seo JH, Li G, Shetty GM, *et al.* Effect of repair of radial tears at the root of the posterior horn of the medial meniscus with the pullout suture technique: a biomechanical study using porcine knees. *Arthroscopy* 2009;25:1281–7.
- Lerer DB, Umans HR, Hu MX, *et al.* The role of meniscal root pathology and radial meniscal tear in medial meniscal extrusion. *Skeletal Radiol* 2004;33:569–74.
- Sung JH, Ha JK, Lee DW, *et al.* Meniscal extrusion and spontaneous osteonecrosis with root tear of medial meniscus: comparison with horizontal tear. *Arthroscopy* 2013;29:726–32.
- Bhatia S, LaPrade CM, Ellman MB, *et al.* Meniscal root tears: significance, diagnosis, and treatment. *Am J Sports Med* 2014;42:3016–30.
- Koo JH, Choi SH, Lee SA, *et al.* Comparison of Medial and Lateral Meniscus Root Tears. *PLoS One* 2015;10:e0141021.
- Hussain ZB, Chahla J, Mandelbaum BR, *et al.* The Role of Meniscal Tears in Spontaneous Osteonecrosis of the Knee: a Systematic Review of Suspected Etiology and a Call to Revisit Nomenclature. *Am J Sports Med* 2017;036354651774373.
- Padalecki JR, Jansson KS, Smith SD, *et al.* Biomechanical consequences of a complete radial tear adjacent to the medial meniscus posterior root attachment site: in situ pull-out repair restores derangement of joint mechanics. *Am J Sports Med* 2014;42:699–707.
- Feucht MJ, Kühle J, Bode G, *et al.* Arthroscopic Trans tibial Pullout Repair for Posterior Medial Meniscus Root Tears: A Systematic Review of Clinical, Radiographic, and Second-Look Arthroscopic Results. *Arthroscopy* 2015;31:1808–16.
- Chung KS, Ha JK, Ra HJ, *et al.* Pullout Fixation of Posterior Medial Meniscus Root Tears: Correlation Between Meniscus Extrusion and Midterm Clinical Results. *Am J Sports Med* 2017;45:42–9.
- LaPrade CM, Ellman MB, Rasmussen MT, *et al.* Anatomy of the anterior root attachments of the medial and lateral menisci: a quantitative analysis. *Am J Sports Med* 2014;42:2386–92.
- LaPrade CM, James EW, Cram TR, *et al.* Meniscal root tears: a classification system based on tear morphology. *Am J Sports Med* 2015;43:363–9.
- LaPrade CM, Jansson KS, Dornan G, *et al.* Altered tibiofemoral contact mechanics due to lateral meniscus posterior horn root avulsions and radial tears can be restored with in situ pull-out suture repairs. *J Bone Joint Surg Am* 2014;96:471–9.
- Marzo JM, Gurske-DePerio J. Effects of medial meniscus posterior horn avulsion and repair on tibiofemoral contact area and peak contact pressure with clinical implications. *Am J Sports Med* 2009;37:124–9.
- Schillhammer CK, Werner FW, Scuderi MG, *et al.* Repair of lateral meniscus posterior horn detachment lesions: a biomechanical evaluation. *Am J Sports Med* 2012;40:2604–9.
- Geeslin AG, Civitarese D, Turnbull TL, *et al.* Influence of lateral meniscal posterior root avulsions and the meniscofemoral ligaments on tibiofemoral contact mechanics. *Knee Surg Sports Traumatol Arthrosc* 2016;24:1469–77.
- Fairbank TJ. Knee joint changes after meniscectomy. *J Bone Joint Surg Br* 1948;30B:664–70.
- Chahla J, Moulton SG, LaPrade CM, *et al.* Posterior Meniscal Root Repair: The Trans tibial Double Tunnel Pullout Technique. *Arthrosc Tech* 2016;5:e291–6.
- LaPrade RF, Matheny LM, Moulton SG, *et al.* Posterior meniscal root repairs: outcomes of an anatomic trans tibial pull-out technique. *Am J Sports Med* 2017;45:884–91.
- Kim YM, Rhee KJ, Lee JK, *et al.* Arthroscopic pullout repair of a complete radial tear of the tibial attachment site of the medial meniscus posterior horn. *Arthroscopy* 2006;22:795.e1–4.
- Ahn JH, Wang JH, Yoo JC, *et al.* A pull out suture for transection of the posterior horn of the medial meniscus: using a posterior trans-septal portal. *Knee Surg Sports Traumatol Arthrosc* 2007;15:1510–3.
- LaPrade CM, LaPrade MD, Turnbull TL, *et al.* Biomechanical evaluation of the trans tibial pull-out technique for posterior medial meniscus root repairs using 1 and 2 trans tibial bone tunnels. *Am J Sports Med* 2015;43:899–904.
- LaPrade RF, LaPrade CM, Ellman MB, *et al.* Cyclic displacement after meniscal root repair fixation: a human biomechanical evaluation. *Am J Sports Med* 2015;43:892–8.
- de Girolamo L, Galliera E, Volpi P, *et al.* Why menisci show higher healing rate when repaired during ACL reconstruction? Growth factors release can be the explanation. *Knee Surg Sports Traumatol Arthrosc* 2015;23:90–6.
- Murrell WD, Anz AW, Badsha H, *et al.* Regenerative treatments to enhance orthopedic surgical outcome. *Pm R* 2015;7:S41–52.
- Delos D, Rodeo SA. Enhancing meniscal repair through biology: platelet-rich plasma as an alternative strategy. *Instr Course Lect* 2011;60:453–60.
- Halpern B, Chaudhury S, Rodeo SA, *et al.* Clinical and MRI outcomes after platelet-rich plasma treatment for knee osteoarthritis. *Clin J Sport Med* 2013;23:238–9.
- Hutchinson ID, Rodeo SA, Perrone GS, *et al.* Can platelet-rich plasma enhance anterior cruciate ligament and meniscal repair? *J Knee Surg* 2015;28:019–28.
- Chung KS, Ha JK, Yeom CH, *et al.* Comparison of Clinical and Radiologic Results Between Partial Meniscectomy and Refixation of Medial Meniscus Posterior Root Tears: A Minimum 5-Year Follow-up. *Arthroscopy* 2015;31:1941–50.
- Krych AJ, Reardon PJ, Johnson NR, *et al.* Non-operative management of medial meniscus posterior horn root tears is associated with worsening arthritis and poor clinical outcome at 5-year follow-up. *Knee Surg Sports Traumatol Arthrosc* 2017;25.
- Choi ES, Park SJ. Clinical Evaluation of the Root Tear of the Posterior Horn of the Medial Meniscus in Total Knee Arthroplasty for Osteoarthritis. *Knee Surg Relat Res* 2015;27:90–4.
- Stärke C, Kopf S, Gröbel KH, *et al.* The effect of a nonanatomic repair of the meniscal horn attachment on meniscal tension: a biomechanical study. *Arthroscopy* 2010;26:358–65.
- LaPrade CM, Foad A, Smith SD, *et al.* Biomechanical consequences of a nonanatomic posterior medial meniscal root repair. *Am J Sports Med* 2015;43:912–20.
- Cerminara AJ, LaPrade CM, Smith SD, *et al.* Biomechanical evaluation of a trans tibial pull-out meniscal root repair: challenging the bungee effect. *Am J Sports Med* 2014;42:2988–95.
- Chung KS, Ha JK, Ra HJ, *et al.* A meta-analysis of clinical and radiographic outcomes of posterior horn medial meniscus root repairs. *Knee Surg Sports Traumatol Arthrosc* 2016;24:1455–68.
- Hwang BY, Kim SJ, Lee SW, *et al.* Risk factors for medial meniscus posterior root tear. *Am J Sports Med* 2012;40:1606–10.
- Feucht MJ, Salzmann GM, Bode G, *et al.* Posterior root tears of the lateral meniscus. *Knee Surg Sports Traumatol Arthrosc* 2015;23:119–25.
- Lee DW, Ha JK, Kim JG. Medial meniscus posterior root tear: a comprehensive review. *Knee Surg Relat Res* 2014;26:125–34.
- Seil R, Dück K, Pape D. A clinical sign to detect root avulsions of the posterior horn of the medial meniscus. *Knee Surg Sports Traumatol Arthrosc* 2011;19:2072–5.
- De Smet AA, Mukherjee R. Clinical, MRI, and arthroscopic findings associated with failure to diagnose a lateral meniscal tear on knee MRI. *AJR Am J Roentgenol* 2008;190:22–6.
- Nogueira-Barbosa MH, Greggio-Junior E, Lorenzato MM, *et al.* Ultrasound assessment of medial meniscal extrusion: a validation study using MRI as reference standard. *AJR Am J Roentgenol* 2015;204:584–8.
- LaPrade RF, Matheny LM, Moulton SG, *et al.* Posterior Meniscal Root Repairs: Outcomes of an Anatomic Trans tibial Pull-Out Technique. *Am J Sports Med* 2017;45.
- Tengrootenhuisen M, Meermans G, Pittoors K, *et al.* Long-term outcome after meniscal repair. *Knee Surg Sports Traumatol Arthrosc* 2011;19:236–41.



Meniscal root tears: a silent epidemic

Mark E Cinque, Jorge Chahla, Gilbert Moatshe, Scott C Faucett, Aaron J Krych and Robert F LaPrade

Br J Sports Med published online March 24, 2018

Updated information and services can be found at:

<http://bjsm.bmj.com/content/early/2018/03/24/bjsports-2017-098942>

These include:

References

This article cites 48 articles, 3 of which you can access for free at:
<http://bjsm.bmj.com/content/early/2018/03/24/bjsports-2017-098942#ref-list-1>

Email alerting service

Receive free email alerts when new articles cite this article. Sign up in the box at the top right corner of the online article.

Notes

To request permissions go to:

<http://group.bmj.com/group/rights-licensing/permissions>

To order reprints go to:

<http://journals.bmj.com/cgi/reprintform>

To subscribe to BMJ go to:

<http://group.bmj.com/subscribe/>