

# Ortho-Biologics for Ligament Repair and Reconstruction



Jorge Chahla, MD, PhD<sup>a,\*</sup>, Mitchell I. Kennedy, BS<sup>b</sup>,  
Zach S. Aman, BA<sup>b</sup>, Robert F. LaPrade, MD, PhD<sup>c</sup>

## KEYWORDS

- Platelet-rich plasma • Anterior cruciate ligament • Growth factor
- Transforming growth factor • Bone marrow aspirate concentrate

## KEY POINTS

- Despite the recent appraisal of biologics within treatment protocols, no clear algorithm for indication, processing methodology, or application exists currently.
- There is a significant potential for enhancement of tissue healing within both acute and chronic conditions in restoring native or near native tissue.
- Biologics may provide an alternative to surgical intervention when nonoperative treatment is preferred by patients or surgeons.
- When biologics are used in addition to surgical intervention, there is a potential for enhanced bone mineral density, bone volume, overall graft integrity, and vascularity within cells.
- Currently, the literature is inconsistent in providing definite conclusions on outcomes and usage of biologics for the treatment of musculoskeletal injuries; but laboratory, animal, and some clinical studies have provided promising results for the future direction of orthopedic treatment protocols and rehabilitation.

## INTRODUCTION

Novelties and technology improvement for ortho-biological therapies, tissue grafting, and surgical augmentation have exhibited overwhelming growth in the past decade.<sup>1</sup> At first, biologics were envisioned to enhance tissue healing in both acute and chronic conditions by stimulating the recovery processes to restore native or near-native tissue while reducing risks for treatment failure. Nonetheless, symptom

---

Disclosure Statement: The authors have nothing to disclose.

<sup>a</sup> Sports Medicine and Shoulder Service, Midwest Orthopaedics at Rush, 1611 Harrison Avenue, Suite 300, Chicago, IL 60612, USA; <sup>b</sup> The Steadman Philippon Research Institute, 181 West Meadow Drive, Suite 400, Vail, CO 81657, USA; <sup>c</sup> The Steadman Clinic, 181 West Meadow Drive, Suite 400, Vail, CO 81657, USA

\* Corresponding author. 181 West Meadow Drive, Suite 400, Vail, CO 81657.

E-mail address: [jachahla@msn.com](mailto:jachahla@msn.com)

Clin Sports Med 38 (2019) 97–107  
<https://doi.org/10.1016/j.csm.2018.08.003>

[sportsmed.theclinics.com](http://sportsmed.theclinics.com)

0278-5919/19/© 2018 Elsevier Inc. All rights reserved.

management has recently become another important indication for their use.<sup>2-4</sup> The most popular biological modalities currently used for the treatment of acute and chronic musculoskeletal conditions and as adjuvants for conservative and surgical approaches include hyaluronic acid, single/combined growth factors (GFs) therapy, platelet-rich plasma (PRP) (Figs. 1 and 2), and bone marrow aspirate concentrate (BMAC) (Fig. 3).

However, despite the upsurge on the use and reported success of many of these therapies, there is no clear algorithm for the indications, processing methodology, application, and reporting that has led to inconsistencies in clinical and basic science results.<sup>5-7</sup> Hence, establishing an optimal protocol for the treatment of various musculoskeletal entities remains a challenge because the specific treatment or combination of them, the number of applications, the processing method, and the real and long-term efficacy of these biological approaches has yet to be determined.<sup>8,9</sup>

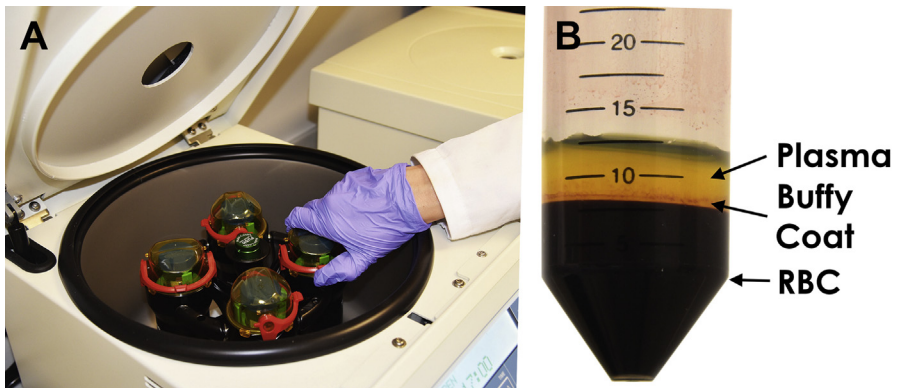
Complex biomechanics, different vectors of load, and an intra-articular hostile environment have also been reported as serious obstacles to successfully adhere tissue-engineered and autologous biologics to damaged tissue, regenerate homogeneous tissue, and finally revascularize the tissue sufficiently and timely to prevent a future reinjury.<sup>10-12</sup> For the aforementioned reasons, the purpose of this article is to review current concepts on several biological treatment approaches as an adjuvant for the most commonly performed ligament injuries repair or reconstructions.

## KNEE

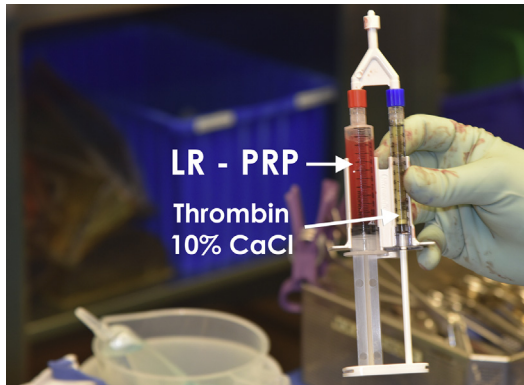### *Anterior Cruciate Ligament*

Despite being one of the most frequent procedures in orthopedics (reported to be the sixth most common),<sup>13</sup> limited progress has been made to improve anterior cruciate ligament (ACL) reconstruction and its healing capacity or to improve the time of ACL graft ligament incorporation to enhance knee biomechanics, reduce the return to sports times, and ultimately limit the development of degenerative joint changes.<sup>14-17</sup>

In this regard, regenerative treatment protocols are thought to have the potential to improve current surgical ACL interventions by enhancing graft incorporation and



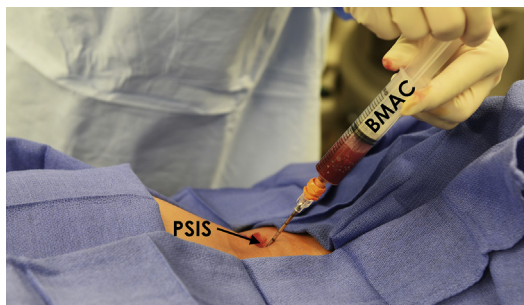
**Fig. 1.** (A) The centrifuge setup for processing of PRP and (B) the final result with 3 distinct layers of cellular material after processing the sample. At the top of the test tube is the platelet-poor plasma; beneath this layer is the buffy coat where most platelets lie (the deepest layer of the buffy coat layer contains high concentrations of white blood cells), and at the bottom layer are the red blood cells (RBCs).



**Fig. 2.** A double syringe system for injection (1:1 ratio allowing homologous mixture of the PRP [left] and a gelling agent solution [right], respectively). Gelling agent solution typically consists of thrombin and 10% calcium chloride (CaCl) solution (1000 IUs thrombin:1 mL CaCl). LR, leukocyte rich.

strength, gene activation, trophic induction, and microenvironment facilitation and signaling with cells or bioactive factors to optimize, delay, or prevent premature progression of osteoarthritis.<sup>18</sup> It is accepted that the success of an ACL reconstruction depends heavily on biological processes for each phase of the healing process. Commonly reported regenerative modalities contain various GFs, including transforming GF  $\beta$ -1 (TGF- $\beta$ 1), fibroblast GF-2 (FGF-2), insulinlike GF, epidermal GF, platelet-derived GF (PDGF), and vascular endothelial GF (VEGF). These GFs have demonstrated positive effects on cell proliferation, cell migration, angiogenesis, and extracellular matrix (ECM) production in numerous cell types of both in vivo and in vitro models.<sup>19</sup>

The primary cell in the ACL is the fibroblast. The fibroblast has receptors for many of these GFs, including PDGF, TGF- $\beta$ , and FGF. For example, PDGF stimulates fibroblast growth, migration, and biosynthetic activity,<sup>20</sup> which could promote an improved ligamentization of the graft used for ACL repair or reconstruction and minimize the proinflammatory factors released immediately after surgery but might also contribute to a better and faster integration of the graft within the femoral and tibial tunnels, thus, avoiding an increased failure risk.<sup>21</sup>



**Fig. 3.** A patient in ventral decubitus for BMAC from the left posterior superior iliac spine (PSIS).

### **Preclinical studies**

Important basic science studies have been performed in the area of ligament healing in an attempt to regenerate/repair ligaments in a less invasive approach using the tissue remnants available. Although in clinical practice this is not often possible, because of the lack of viable tissue pending the severity and/or chronicity of the injury, growing preclinical work has provided the basis to improve these biological approaches. GFs, such as TGF- $\beta$ 1,<sup>22</sup> FGF-2,<sup>23</sup> and basic-FGF,<sup>24</sup> have been reported to regulate and improve cellular activities and proliferation and ECM deposition and to influence the differentiation of mesenchymal stem cells (MSCs) into fibroblasts in the repair process of torn ligaments. Particularly, the GFs outlined later have exhibited positive effects on various biological processes needed to improve ACL healing.

The TGF- $\beta$  family is a key regulator during embryologic development and also plays a significant role in the early modulation of scar tissue formation during connective tissue healing.<sup>25</sup> Studies comparing the application of different GFs in animals with partial ACL tears and ACL explant models suggested that TGF- $\beta$ 1 might stimulate initial healing and overall healing both histologically and biomechanically.<sup>26,27</sup> Kondo and colleagues<sup>26</sup> reported on the effect of TGF- $\beta$ 1 in a rabbit ACL injury model and reported significant improvement of the biomechanical and histologic healing properties of injured ACLs treated with TGF- $\beta$ 1 when compared with controls. Recently, it has been reported that blocking VEGF reduces angiogenesis, graft maturation, and biomechanical strength following an ACL reconstruction in a rat model.<sup>28</sup> Further, a different group studied 18 sheep undergoing ACL reconstruction with either a VEGF-augmented graft or a control group. The VEGF group demonstrated improved vascularization and fibroblast infiltration; however, increased graft laxity was found at 12 weeks.<sup>29</sup>

Murray and colleagues<sup>30</sup> reported on a porcine ACL repair model using clotted PRP, suggesting that there was no beneficial effect of adding PRP when compared with controls. It was theorized that the fibrin clot containing the platelets may have been prematurely dissolved in the intra-articular environment by circulating plasmin in the synovial fluid.

These findings directed the attention to developing scaffolds to protect the graft from early degradation due to the hostile intra-articular environment. Consequently, Cheng and colleagues<sup>31</sup> showed that the addition of PRP to a collagen hydrogel resulted in a significantly increased cellular metabolic activity, reduced apoptotic rate, and stimulation of collagen production in the cells from the immature and adolescent animals but had less effect on adult cells animals.

A study using a rat model compared ACL regeneration between animal groups subjected to intra-articular injection of fresh whole bone marrow cells (BMCs), cultured MSCs, or saline in partial ACL tears.<sup>32</sup> The investigators suggested that intra-articular bone marrow transplantation using fresh whole BMCs is an effective treatment of ACL partial rupture and reported nearly normal strength and ligament healing compared with control subjects. Similarly, Kanaya and colleagues<sup>33</sup> reported that intra-articular injection of MSCs resulted in a healed ligament with superior histologic scores and a greater failure load compared with nontreated control knees. A recent study by Lui and colleagues<sup>34</sup> compared ACL reconstructions with tendon-derived stem cell sheets (after treatment with connective tissue GF) and a control group in 97 rats. The treatment arm exhibited higher tunnel bone mineral density and bone volume, better graft osteointegration, and higher intra-articular graft integrity with lower cellularity, vascularity, and cell alignment compared with the control group.

### **Clinical studies**

Improvements in tissue engineering and regenerative medicine technology have resulted in a new interest in the biological augmentation of ACL repairs and reconstructions, including GF, PRP, stem cells, and bio-scaffolds. A recent systematic review<sup>35</sup> reported on 23 studies, including one reporting on stem cells, one on concomitant application of PRP and stem cells, and 21 articles on PRP. Two studies reported on ACL repair with biologics and the remaining 21 on ACL reconstruction augmented with PRP. The investigators concluded that the role of PRP on ACL repair/reconstruction is still controversial and is only related to improved graft maturation over time, without beneficial effects in terms of clinical outcome, bone-graft integration, and prevention of bony tunnel enlargement in the short-term outcome.

Seijas and colleagues<sup>36</sup> reported on 19 professional soccer players with partial ACL tears treated with intraligamentous placement of PDGFs into the intact bundle. Eighteen of 19 players were able to return to their previous level of play at a mean of 16.20 weeks. Platelet-rich GF (PRGF-Endoret)<sup>37</sup> was applied in the intact posterolateral bundle intra-articularly in a different study by Anitua and colleagues.<sup>37</sup> No complications and satisfactory objective results (KT-1000; MEDMETRIC, San Diego, CA) were reported in this study, and postoperative MRI evaluation demonstrated complete ligamentization at 1 year after surgery with good anatomic arrangement.

Radice and colleagues<sup>38</sup> reported on 100 ACL reconstructions prospectively, comparing PRP gel (PRPG) with a control group. Notably, graft homogeneity was 48% shorter in the PRPG group (179 vs 369 days). Additionally, Vogrin and colleagues<sup>39</sup> reported on 50 patients (25 thrombin-activated PRP-soaked grafts and 25 control group) and demonstrated improved anterior-posterior instrumented knee stability via a KT-2000 (MEDMETRIC; San Diego, CA) arthrometer at 6 months. Conversely, Nin and colleagues<sup>40</sup> reported on 100 patients undergoing an ACL reconstruction with bone-tendon-bone allograft (double-blind randomized clinical trial). The investigators reported no difference was found in terms of subjective outcome, biomechanical integration, or graft integration at 2 years' follow-up.

Gobbi and colleagues<sup>41</sup> evaluated the 5-year clinical results of PRP injection in 58 athletes treated by ACL suture repair in addition to microfracture of the intercondylar notch. They reported that 78% of the patients returned to their sports activities. The side-to-side difference in anterior translation significantly decreased from 4.1 mm (SD = 1.6) preoperatively to 1.4 mm (SD = 0.8) postoperatively ( $P < .05$ ). Four patients had a retear during sporting activity and underwent an ACL reconstruction within 2 years from the primary repair surgery. This case series concluded that PRP injection was effective in restoring knee stability and function in young individuals with acute partial ACL tears.

Limited evidence exists on histologic data for PRP application after ACL reconstruction. Sanchez and colleagues<sup>42</sup> compared PRGF-assisted ACL reconstructions versus nonaugmented ACL reconstructions that required a second-look arthroscopy (loose body or hardware removal, meniscal tears treatment, or cyclops lesions resection) at a minimum of 6 months. Although gross morphology demonstrated no difference, histologically, newly formed connective tissue enveloping the graft was found in 77.3% of the intervention group versus 40.0% of control subjects.

Concerning BMAC application as an adjuvant for ACL surgery, Centeno and colleagues<sup>43</sup> reported on 10 patients with ACL tears treated with an intraligamentous injection of autologous bone marrow concentrate and PRP using fluoroscopic guidance. ACL laxity and MRI evidence of a grade I, II (partial), or III (complete) tears were documented (always with <1 cm retraction of the ACL stump). ACL tears were assessed by MRI, and software was used to objectively quantify changes of ligament integrity

through 5 different types of measurements of ACL pixel intensity. Seven of 10 patients showed improvement in at least 4 of these 5 objective MRI measures. The mean visual analog scale change decreased by 1.7 ( $P = .25$ ), and the mean Lower Extremity Functional Scale increased by 23.3 ( $P = .03$ ); a mean improvement of 86.7% was reported.

### **Medial Collateral Ligament**

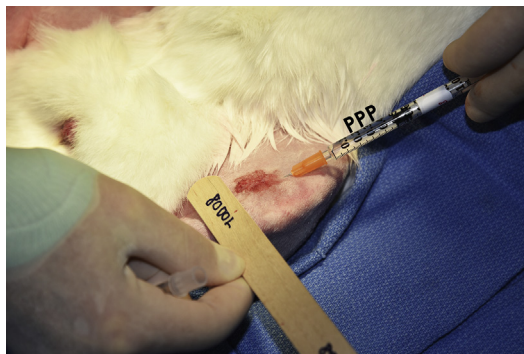
Isolated medial collateral ligament (MCL) injuries are the most common knee ligament injuries and are typically managed with conservative treatment resulting in satisfactory results. However, mechanical and histologic properties typically do not return to normal.<sup>44,45</sup> For this reason, the use of PRP to advance MCL healing has been proposed.<sup>46</sup>

#### **Preclinical studies**

Despite the frequent use of PRP to treat ligamentous injuries, there is limited information on the use of PRP in basic science; clinical trials to determine if improvement can be achieved for biomechanics or ligamentous healing can be accelerated.<sup>47</sup> LaPrade and colleagues<sup>48</sup> reported that one single dose of either PPP or a 2-times dose of PRP at the time of injury did not accelerate ligament healing (Fig. 4). Additionally, a 4-times dose of PRP demonstrated a significant negative effect on ligament strength and collagen orientation (relative to the sham group) at 6 weeks after injury. The investigators concluded that MCL tears treated with PRP immediately after injury or surgery may not improve healing at low doses of PRP and could be harming ligament healing at higher PRP doses. In a biomechanical analysis, Yoshioka and colleagues<sup>49</sup> reported significantly improved structural properties of MCLs in rabbits treated with leukocyte-reduced PRP relative to controls. However, no analysis was performed taking the native ligament biomechanical properties; only a comparison between the PRGF and untreated group was made.

#### **Clinical studies**

Literature on the beneficial effect of PRP treatment of MCL injuries is limited. Only one level IV case study report has evaluated the clinical use of PRP with outcomes of isolated grade II MCL injuries.<sup>50</sup> Eirale and colleagues<sup>50</sup> described a successful case of a competitive soccer player in which they opted for conservative treatment with multiple PRP injections and rehabilitation. The athlete returned to play after 18 days with excellent functional scores and without symptoms, but radiological imaging showed



**Fig. 4.** A rabbit MCL being injected with PPP after creating a grade III tear to the ligament to determine the effect of different concentrations of platelets in MCL healing.

incomplete healing of the ligament.<sup>50</sup> Despite this, the athlete had no recurrence of injury or further complications at 16 months' follow-up.<sup>50</sup> This study gives evidence that PRP may play a role in MCL healing with conservative treatment; however, it is encouraged that further clinical outcome studies be performed to elucidate the value of PRP with MCL injury.

### ***Ulnar Collateral Ligament of the Elbow***

---

Enhancing the treatment options for ulnar collateral ligament (UCL) deficiency has long been of interest in the world of sports medicine. Highly prevalent among overhead-throwing athletes, primarily with baseball pitchers from youth to professional levels, improved UCL reconstruction techniques have resulted in increased return-to-play rates between 53% and 90% after once being thought of as a career-ending injury.<sup>51–56</sup> However, there is a disparity in the literature on the postoperative UCL reconstruction outcomes because it has been reported that 3% to 40% of surgical reconstructions result in complications.<sup>57–60</sup> Although there is a multitude of factors that influence UCL recovery, adjunctive treatments like PRP and MSCs may accelerate the timetable for athletes returning to sport and improve overall outcomes. Additionally, biological injections could possibly serve as a nonoperative treatment, acting to bypass a year-long recovery period and pose as an alternative to the perceptually adhered to Tommy John surgery.<sup>56,61,62</sup>

#### ***Preclinical studies***

To the authors' knowledge, no preclinical studies have been performed specifically evaluating the use of biologics for UCL healing. Because of the potential therapeutic use that has been seen for ACL, rotator cuff, and Achilles tendon injury in animal models, it is thought that PRP and MSCs can be applied to UCL injury and are frequently used in clinical settings.

#### ***Clinical studies***

Two studies have used biological adjuncts for nonoperative treatment of a partial UCL tear with promising results, in contrast to clinical outcomes seen in other joints.<sup>59,63</sup> In a case series of overhead-throwing athletes, Podesta and colleagues<sup>63</sup> reported that 88% of athletes with partial UCL tears returned to normal levels of play at 12 weeks after a single PRP injection. Along with satisfying functionality, the investigators also reported decreased medial elbow joint space on valgus loading.<sup>63</sup> Furthermore, another study of 44 competitive baseball players reported that 73% of athletes had good to excellent results following a PRP injection when supplemented with a return-to-play rehabilitation program.<sup>59</sup> Unfortunately, no clinical studies of conservative management of complete UCL injuries with MSCs or scaffolds have been published.<sup>62</sup> However, with the increasing popularity of these methods for treatment of shoulder and knee joint injuries, it should be expected that MSCs and scaffolds would serve a significant role in future UCL treatment techniques.

### **SUMMARY OF RECOMMENDATIONS**

In recent literature, biologics have been shown to have positive results in improving tissue regeneration in laboratory and animal studies; but in the clinical setting, results are mixed in demonstrating its efficacy for patient care. The use of PRP has been tested in both forms of rehabilitation following surgery as well as a replacement to ligamentous reconstructions for patients/surgeons wishing to avoid surgical intervention, but outcomes are clouded among beneficial and neutral effects. With more consistent results of MSC and PRP effects on patient outcomes (preferably with objective data,

such as imaging or histology), the future direction of orthopedic treatment may continue to progress further into less invasive procedures.

## REFERENCES

1. Doral MN, Tandoğan RN, Mann G, et al. Sports injuries: prevention, diagnosis, treatment and rehabilitation. Verlag Berlin, Heidelberg: Springer; 2011.
2. Toolan BC. Current concepts review: orthobiologics. *Foot Ankle Int* 2006;27(7):561–6.
3. Goodman SB, Yao Z, Keeney M, et al. The future of biologic coatings for orthopaedic implants. *Biomaterials* 2013;34(13):3174–83.
4. LaPrade RF, Geeslin AG, Murray IR, et al. Biologic treatments for sports injuries II think tank—current concepts, future research, and barriers to advancement, part 1: biologics overview, ligament injury, tendinopathy. *Am J Sports Med* 2016;44(12):3270–83.
5. DeLong JM, Russell RP, Mazzocca AD. Platelet-rich plasma: the PAW classification system. *Arthroscopy* 2012;28(7):998–1009.
6. Dohan Ehrenfest DMA I, Zumstein MA, Zhang CQ, et al. Classification of platelet concentrates (Platelet-Rich Plasma-PRP, Platelet-Rich Fibrin-PRF) for topical and infiltrative use in orthopedic and sports medicine: current consensus, clinical implications and perspectives. *Muscles Ligaments Tendons J* 2014;4(1):3–9.
7. Holton J, Imam M, Ward J, et al. The basic science of bone marrow aspirate concentrate in chondral injuries. *Orthop Rev (Pavia)* 2016;8(3):6659.
8. Foster TE, Puskas BL, Mandelbaum BR, et al. Platelet-rich plasma: from basic science to clinical applications. *Am J Sports Med* 2009;37(11):2259–72.
9. Sheth U, Simunovic N, Klein G, et al. Efficacy of autologous platelet-rich plasma use for orthopaedic indications: a meta-analysis. *J Bone Joint Surg Am* 2012;94(4):298–307.
10. Zhang L, Hu J, Athanasiou KA. The role of tissue engineering in articular cartilage repair and regeneration. *Crit Rev Biomed Eng* 2009;37(1–2):1–57.
11. Amini AR, Laurencin CT, Nukavarapu SP. Bone tissue engineering: recent advances and challenges. *Crit Rev Biomed Eng* 2012;40(5):363–408.
12. Frohlich M, Grayson WL, Wan LQ, et al. Tissue engineered bone grafts: biological requirements, tissue culture and clinical relevance. *Curr Stem Cell Res Ther* 2008;3(4):254–64.
13. Garrett WE Jr, Swiontkowski MF, Weinstein JN, et al. American Board of Orthopaedic Surgery Practice of the Orthopaedic Surgeon: part-II, certification examination case mix. *J Bone Joint Surg Am* 2006;88(3):660–7.
14. Brown CH Jr, Carson EW. Revision anterior cruciate ligament surgery. *Clin Sports Med* 1999;18(1):109–71.
15. Gottlob CA, Baker CL Jr, Pellissier JM, et al. Cost effectiveness of anterior cruciate ligament reconstruction in young adults. *Clin Orthop Relat Res* 1999;(367):272–82.
16. Kim S, Bosque J, Meehan JP, et al. Increase in outpatient knee arthroscopy in the United States: a comparison of National Surveys of Ambulatory Surgery, 1996 and 2006. *J Bone Joint Surg Am* 2011;93(11):994–1000.
17. Spindler KP, Wright RW. Clinical practice. Anterior cruciate ligament tear. *N Engl J Med* 2008;359(20):2135–42.
18. Kiapour AM, Murray MM. Basic science of anterior cruciate ligament injury and repair. *Bone Joint Res* 2014;3(2):20–31.



19. Hutchinson ID, Rodeo SA, Perrone GS, et al. Can platelet-rich plasma enhance anterior cruciate ligament and meniscal repair? *J Knee Surg* 2015;28(1):19–28.
20. Molloy T, Wang Y, Murrell G. The roles of growth factors in tendon and ligament healing. *Sports Med* 2003;33(5):381–94.
21. Andriolo L, Di Matteo B, Kon E, et al. PRP augmentation for ACL reconstruction. *Biomed Res Int* 2015;2015:371746.
22. Xie J, Wang C, Huang DY, et al. TGF-beta1 induces the different expressions of lysyl oxidases and matrix metalloproteinases in anterior cruciate ligament and medial collateral ligament fibroblasts after mechanical injury. *J Biomech* 2013;46(5):890–8.
23. Madry H, Kohn D, Cucchiari M. Direct FGF-2 gene transfer via recombinant adeno-associated virus stimulates cell proliferation, collagen production, and the repair of experimental lesions in the human ACL. *Am J Sports Med* 2013;41(1):194–202.
24. Kobayashi D, Kurosaka M, Yoshiya S, et al. Effect of basic fibroblast growth factor on the healing of defects in the canine anterior cruciate ligament. *Knee Surg Sports Traumatol Arthrosc* 1997;5(3):189–94.
25. Muller B, Bowman KF Jr, Bedi A. ACL graft healing and biologics. *Clin Sports Med* 2013;32(1):93–109.
26. Kondo E, Yasuda K, Yamanaka M, et al. Effects of administration of exogenous growth factors on biomechanical properties of the elongation-type anterior cruciate ligament injury with partial laceration. *Am J Sports Med* 2005;33(2):188–96.
27. Spindler KP, Imro AK, Mayes CE, et al. Patellar tendon and anterior cruciate ligament have different mitogenic responses to platelet-derived growth factor and transforming growth factor beta. *J Orthop Res* 1996;14(4):542–6.
28. Takayama K, Kawakami Y, Mifune Y, et al. The effect of blocking angiogenesis on anterior cruciate ligament healing following stem cell transplantation. *Biomaterials* 2015;60:9–19.
29. Yoshikawa T, Tohyama H, Katsura T, et al. Effects of local administration of vascular endothelial growth factor on mechanical characteristics of the semitendinosus tendon graft after anterior cruciate ligament reconstruction in sheep. *Am J Sports Med* 2006;34(12):1918–25.
30. Murray MM, Palmer M, Abreu E, et al. Platelet-rich plasma alone is not sufficient to enhance suture repair of the ACL in skeletally immature animals: an in vivo study. *J Orthop Res* 2009;27(5):639–45.
31. Cheng M, Johnson VM, Murray MM. Effects of age and platelet-rich plasma on ACL cell viability and collagen gene expression. *J Orthop Res* 2012;30(1):79–85.
32. Oe K, Kushida T, Okamoto N, et al. New strategies for anterior cruciate ligament partial rupture using bone marrow transplantation in rats. *Stem Cell Dev* 2011;20(4):671–9.
33. Kanaya A, Deie M, Adachi N, et al. Intra-articular injection of mesenchymal stromal cells in partially torn anterior cruciate ligaments in a rat model. *Arthroscopy* 2007;23(6):610–7.
34. Lui PP, Wong OT, Lee YW. Application of tendon-derived stem cell sheet for the promotion of graft healing in anterior cruciate ligament reconstruction. *Am J Sports Med* 2014;42(3):681–9.
35. Di Matteo B, Kon E, Filardo G. Intra-articular platelet-rich plasma for the treatment of osteoarthritis. *Ann Transl Med* 2016;4(3):63.
36. Seijas R, Ares O, Cusco X, et al. Partial anterior cruciate ligament tears treated with intraligamentary plasma rich in growth factors. *World J Orthop* 2014;5(3):373–8.

37. Anitua E. Plasma rich in growth factors: preliminary results of use in the preparation of future sites for implants. *Int J Oral Maxillofac Implants* 1999;14(4):529–35.
38. Radice F, Yanez R, Gutierrez V, et al. Comparison of magnetic resonance imaging findings in anterior cruciate ligament grafts with and without autologous platelet-derived growth factors. *Arthroscopy* 2010;26(1):50–7.
39. Vogrin M, Ruprecht M, Crnjac A, et al. The effect of platelet-derived growth factors on knee stability after anterior cruciate ligament reconstruction: a prospective randomized clinical study. *Wien Klin Wochenschr* 2010;122(Suppl 2):91–5.
40. Nin JR, Gasque GM, Azcarate AV, et al. Has platelet-rich plasma any role in anterior cruciate ligament allograft healing? *Arthroscopy* 2009;25(11):1206–13.
41. Gobbi A, Karnatzikos G, Sankineani SR, et al. Biological augmentation of ACL re-fixation in partial lesions in a group of athletes: results at the 5-year follow-up. *Tech Orthop* 2013;28(2):180–4.
42. Sanchez M, Anitua E, Azofra J, et al. Ligamentization of tendon grafts treated with an endogenous preparation rich in growth factors: gross morphology and histology. *Arthroscopy* 2010;26(4):470–80.
43. Centeno CJ, Pitts J, Al-Sayegh H, et al. Anterior cruciate ligament tears treated with percutaneous injection of autologous bone marrow nucleated cells: a case series. *J Pain Res* 2015;8:437–47.
44. Niyibizi C, Kavalkovich K, Yamaji T, et al. Type V collagen is increased during rabbit medial collateral ligament healing. *Knee Surg Sports Traumatol Arthrosc* 2000;8(5):281–5.
45. Scheffler SU, Clineff TD, Papageorgiou CD, et al. Structure and function of the healing medial collateral ligament in a goat model. *Ann Biomed Eng* 2001;29(2):173–80.
46. Andia I, Maffulli N. Use of platelet-rich plasma for patellar tendon and medial collateral ligament injuries: best current clinical practice. *J Knee Surg* 2015;28(1):11–8.
47. Engebretsen L, Steffen K, Alsousou J, et al. IOC consensus paper on the use of platelet-rich plasma in sports medicine. *Br J Sports Med* 2010;44(15):1072–81.
48. LaPrade RF, Goodrich LR, Philipps J, et al. Use of platelet-rich plasma immediately post-injury to improve ligament healing was not successful in an in vivo animal model. *Am J Sports Med* 2018;46(3):702–12.
49. Yoshioka T, Kanamori A, Washio T, et al. The effects of plasma rich in growth factors (PRGF-Endoret) on healing of medial collateral ligament of the knee. *Knee Surg Sports Traumatol Arthrosc* 2013;21(8):1763–9.
50. Eirale C, Mauri E, Hamilton B. Use of platelet rich plasma in an isolated complete medial collateral ligament lesion in a professional football (soccer) player: a case report. *Asian J Sports Med* 2013;4(2):158–62.
51. Erickson BJ, Gupta AK, Harris JD, et al. Rate of return to pitching and performance after Tommy John surgery in Major League Baseball pitchers. *Am J Sports Med* 2014;42(3):536–43.
52. Makhni EC, Lee RW, Morrow ZS, et al. Performance, return to competition, and reinjury after tommy john surgery in major league baseball pitchers: a review of 147 cases. *Am J Sports Med* 2014;42(6):1323–32.
53. Osbahr DC, Cain EL Jr, Raines BT, et al. Long-term outcomes after ulnar collateral ligament reconstruction in competitive baseball players: minimum 10-year follow-up. *Am J Sports Med* 2014;42(6):1333–42.
54. Park JY, Oh KS, Bahng SC, et al. Does well maintained graft provide consistent return to play after medial ulnar collateral ligament reconstruction of the elbow joint in elite baseball players? *Clin Orthop Surg* 2014;6(2):190–5.

55. Rohrbough JT, Altchek DW, Hyman J, et al. Medial collateral ligament reconstruction of the elbow using the docking technique. *Am J Sports Med* 2002;30(4):541–8.
56. Jobe FW, Stark H, Lombardo SJ. Reconstruction of the ulnar collateral ligament in athletes. *J Bone Joint Surg Am* 1986;68(8):1158–63.
57. Conway JE, Jobe FW, Glousman RE, et al. Medial instability of the elbow in throwing athletes. Treatment by repair or reconstruction of the ulnar collateral ligament. *J Bone Joint Surg Am* 1992;74(1):67–83.
58. Dodson CC, Thomas A, Dines JS, et al. Medial ulnar collateral ligament reconstruction of the elbow in throwing athletes. *Am J Sports Med* 2006;34(12):1926–32.
59. Dines JS, Williams PN, ElAttrache N, et al. Platelet-rich plasma can be used to successfully treat elbow ulnar collateral ligament insufficiency in high-level throwers. *Am J Orthop (Belle Mead NJ)* 2016;45(5):296–300.
60. Azar FM, Andrews JR, Wilk KE, et al. Operative treatment of ulnar collateral ligament injuries of the elbow in athletes. *Am J Sports Med* 2000;28(1):16–23.
61. Ahmad CS, Grantham WJ, Greiwe RM. Public perceptions of Tommy John surgery. *Phys Sportsmed* 2012;40(2):64–72.
62. Rebolledo BJ, Dugas JR, Bedi A, et al. Avoiding Tommy John Surgery: what are the alternatives? *Am J Sports Med* 2017;45(13):3143–8.
63. Podesta L, Crow SA, Volkmer D, et al. Treatment of partial ulnar collateral ligament tears in the elbow with platelet-rich plasma. *Am J Sports Med* 2013;41(7):1689–94.