



# Carbon Dioxide Insufflation of the Knee in the Treatment of Full-Thickness Chondral Defects With Micronized Human Articular Cartilage

Raffy Mirzayan, M.D., Joseph D. Cooper, M.D., and Jorge Chahla, M.D., Ph.D.

**Abstract:** BioCartilage (BC) is dehydrated, minced human hyaline articular cartilage that was developed as an adjunct to microfracture surgery to help stimulate the bone marrow and stem cells to form hyaline-like tissue in full-thickness chondral defects. The minced pieces of BC require a dry environment for application and can easily be disrupted by residual moisture of saline solution in the surrounding tissues. We present a technique of carbon dioxide insufflation during knee arthroscopy as a means of maintaining a dry environment for preparation of the bony bed during BC augmentation of microfracture surgery. This technique is safe and provides more than adequate visualization, as well as a dry environment, to make the arthroscopic application of BC significantly more efficient.

Microfracture procedure is a commonly used technique to address small (<2 cm<sup>2</sup>) articular cartilage defects in the knee. However, review studies have shown that the resulting fibrocartilage does not have long-term durability or the biomechanical characteristics of the native articular cartilage.<sup>1,2</sup> A recent systematic review concluded that failure of the repair could be expected beyond 5 years after the procedure.<sup>3</sup> BioCartilage (BC) (Arthrex, Naples, FL) was developed as an adjunct to microfracture surgery. It is dehydrated, micronized human hyaline articular cartilage that can be stored on the shelf and rehydrated by autologous conditioned plasma (ACP; Arthrex) before application. It acts as a scaffold and stimulates

the bone marrow and stem cells to form hyaline-like tissue in the defect. The challenge with arthroscopic application of BC is that it requires a dry environment for successful application. Saline solution arthroscopy, even after fluid ingress has been shut off and the joint has been suctioned dry, leaves the tissues moist, and residual saline solution drips from the surrounding tissues into the repair bed.

With the use of gas insufflation instead of saline solution, a dry environment can be achieved throughout the case, with optimal visualization. Medical-grade carbon dioxide is readily available in operating rooms and is used by general surgeons for insufflation of the abdomen for endoscopic procedures. It is easily absorbed by the tissues and exhaled by the patient without detrimental side effects.<sup>4-7</sup> The use of carbon dioxide for knee arthroscopy has been in practice since the 1980s, and authors have found that it increases the field of view, provides a more natural appearance of the knee joint, and increases visualization by eliminating floating debris of a blurred field due to bleeding synovial villi.<sup>5,8-10</sup> More recently, a group from Italy described a technique of temporarily insufflating the knee with carbon dioxide during matrix-induced autologous chondrocyte implantation (MACI), which also requires a dry environment.<sup>11</sup> In the described procedure, most of the case was completed with saline solution; however, for the placement of the MACI scaffold, the saline solution was drained and carbon dioxide insufflation was used. A subsequent analysis of the safety of this method showed no complications.<sup>12</sup>

From the Department of Orthopaedic Surgery, Kaiser Permanente (R.M.), Baldwin Park, California; Department of Orthopaedic Surgery, Keck School of Medicine, University of Southern California (R.M., J.D.C.), Los Angeles; and Cedars-Sinai Kerlan-Jobe Institute (J.C.), Santa Monica, California, U.S.A.

The authors report the following potential conflicts of interest or sources of funding: R.M. receives research grant fees from Arthrex, JRF, and BioD LLC; royalties from Lippincott and Thieme; and stock/stock options from Aligned, ITS Implants, and Cayenne Medical. Full ICMJE author disclosure forms are available for this article online, as [supplementary material](#).

Received March 17, 2016; accepted May 27, 2018.

Address correspondence to Raffy Mirzayan, M.D., Department of Orthopaedic Surgery, Kaiser Permanente, 1011 Baldwin Park Blvd, Baldwin Park, CA 91706, U.S.A. E-mail: [lakersdoc@gmail.com](mailto:lakersdoc@gmail.com)

© 2018 by the Arthroscopy Association of North America. Published by Elsevier. This is an open access article under the CC BY-NC-ND license (<http://creativecommons.org/licenses/by-nc-nd/4.0/>).

2212-6287/16230

<https://doi.org/10.1016/j.eats.2018.05.005>

**Table 1.** Pearls and Pitfalls for BioCartilage Application With Carbon Dioxide Insufflation of Knee

Pearls	Pitfalls
The knee is filled to a pressure of 15 mm Hg at a flow rate of 15 L/min.	Visualization could be impaired by nonoptimal pressure settings.
Fog-reduction solution is applied to the lens to prevent moisture.	Fog on the lens can make the procedure and visualization extremely challenging.
Defect bed preparation is key for a successful outcome. A set of curettes and shavers is used for this purpose.	Failure to prepare the bony bed could result in defective repair tissue formation and less than optimal results.
A smooth 0.062-inch Kirschner wire at low revolutions per minute is used to minimize heat formation and avoid damaging the subchondral bone.	Microfracture awls can disrupt the subchondral bone and overgrowth of bone postoperatively compromising repair outcomes.
BioCartilage is mixed with 0.8 ml of ACP to make a thick solution that can stay in the defect.	A more fluid mixture of BioCartilage and ACP could make the application of the product a challenging step.
An accessory superomedial inflow portal should be used for carbon dioxide insufflation.	Using the same inflow through the arthroscope trocar will not keep the knee continuously insufflated.

ACP, autologous conditioned plasma.

A prospective trial comparing saline solution versus carbon dioxide knee insufflation for anterior cruciate ligament reconstruction found improved visualization, faster operative times, and no major complications with the use of carbon dioxide.<sup>7</sup>

We describe a technique of carbon dioxide insufflation for knee arthroscopy during BC augmentation of microfracture surgery. We believe this safe technique provides more than adequate visualization, as well as a dry environment, to make the arthroscopic application of BC significantly more efficient.

## Surgical Technique

### Preoperative Preparation and Positioning

The patient is positioned supine on the operating table for knee arthroscopy. A tourniquet is applied to the upper thigh as high as possible to maximize the operative field. A post is placed approximately at the level of the tourniquet laterally on the operative leg to be used as counter-pressure while valgus is being applied to open the medial knee. The extremity is prepared and draped in standard fashion. A marking pen is used to outline the patella, tibial tubercle, and patellar tendon as landmarks for the case. The lower extremity is exsanguinated with an Esmarch bandage and the tourniquet inflated. A list of pearls and pitfalls of this procedure can be found in [Table 1](#), and advantages and limitations are shown in [Table 2](#).

### Arthroscopy and Insufflation

A standard anterolateral portal is placed in the “soft spot.” The anteromedial portal is placed under direct visualization (30° arthroscope) by first inserting an 18-gauge spinal needle to mark the portal site and ensure adequate access to the desired repair location. A third, superomedial portal is created under direct visualization for the inflow cannula, which is inserted through

the vastus medialis obliquus muscle ([Video 1](#), [Fig 1](#)). Carbon dioxide insufflation is carried out through this portal. By use of an insufflation pump, the knee is filled to a pressure of 15 mm Hg at a flow rate of 15 L/min. Although not required in saline solution arthroscopy, fog-reduction solution (Medline, Mundelein, IL) is required with carbon dioxide. This is applied to the lens to prevent moisture.

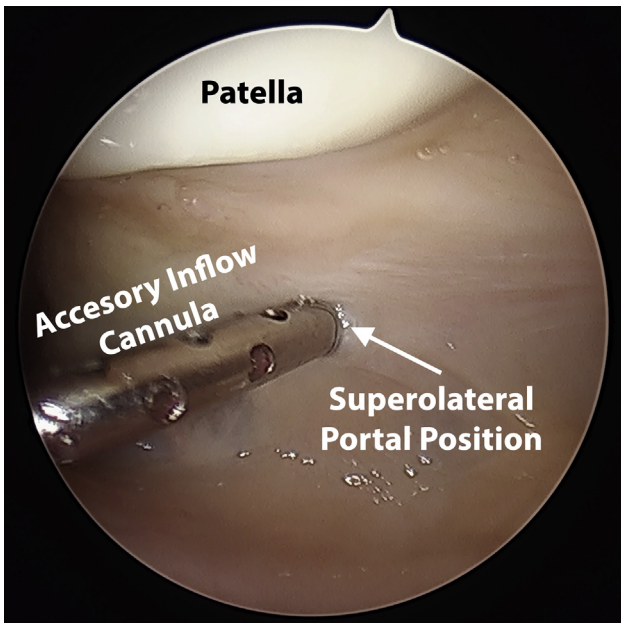
The surgeon performs a standard diagnostic arthroscopy, evaluating all compartments of the knee. Debridement of the Hoffa fat pad and debris in the field of view can easily be performed with a shaver without saline solution.

### Microfracture and Bed Preparation

Microfracture is carried out as described by Mithoefer et al.<sup>13</sup> The lesion is identified ([Fig 2](#)) and debrided, maintaining perpendicular walls of healthy surrounding cartilage at the margin of the lesion. The defect is measured ([Fig 3](#)). The calcified cartilage layer is removed with a set of shavers and curettes. A smooth 0.062-inch Kirschner wire or a PowerPick (Arthrex) at low revolutions per minute is used to perform the microfracture. This minimizes heat formation and negates the need for saline solution irrigation without aggressively disrupting the subchondral plate, as well as

**Table 2.** Advantages and Disadvantages of Carbon Dioxide Insufflation of Knee for BioCartilage Treatment

Advantages
Effective means to keep defect dry
Availability of described technology in most operating rooms
Inexpensive
Reliable
Safe (multiple previous reports)
Disadvantages
Arthroscopic surgeons not used to this technology
Fogging of lens



**Fig 1.** The accessory inflow cannula is inserted through the superomedial portal through the vastus medialis obliquus of a left knee, as viewed from the anterolateral portal. This secondary inflow cannula should be used for carbon dioxide insufflation.

lowering the risk of subchondral edema and overgrowth of intralesional osteophytes postoperatively. The number of holes (marrow vents) required is based on the cartilage defect. Vents are created systematically from the periphery of the defect and normal cartilage junction spaced approximately 2 to 3 mm apart. Additional vents are created in the central portion of the defect until they adequately fill the defect (Fig 4).

#### BC Preparation and Application

The BC is mixed with 0.8 ml of autologous conditioned plasma. This amount of the products makes the resulting paste thicker and more likely to stay within the defect.

The trocar is inserted through an anterior portal. The plunger is carefully and slowly pressed, advancing the paste into the defect. It is best to underfill the defect relative to the surrounding cartilage to avoid hypertrophic cartilage formation. An elevator can be used to spread the paste evenly over the defect (Fig 5). Fibrin glue (Evicel; Johnson & Johnson Wound Management, Somerville, NJ) is then applied over the BC to seal the product over the defect and allow curing for approximately 15 minutes (Fig 6).

#### Postoperative Management

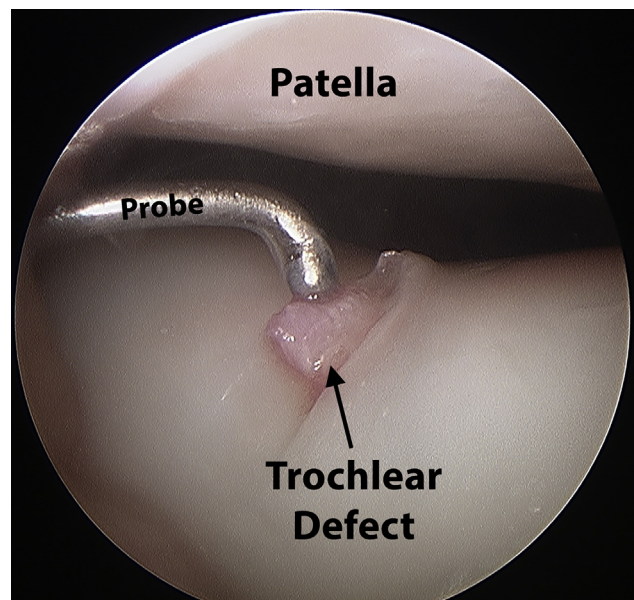
The patient's knee is immobilized in extension for 24 hours, and range of motion is initiated with continuous passive range of motion for the first 3 weeks. The patient is kept non-weight bearing for

6 weeks, but there is no restriction on range of motion. The patient is allowed weight bearing as tolerated at 6 weeks. However, impact activities are not permitted until 4 months postoperatively.

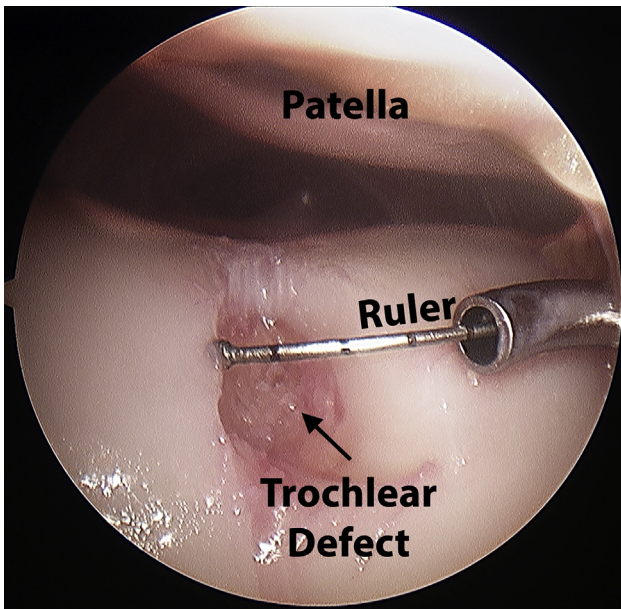
#### Discussion

This study describes a surgical technique of carbon dioxide insufflation of the knee for arthroscopic application of BC in the augmentation of microfracture repair of articular cartilage defects. The use of carbon dioxide provides adequate visualization while maintaining a dry environment for preparation of the repair surface and application of the BC.

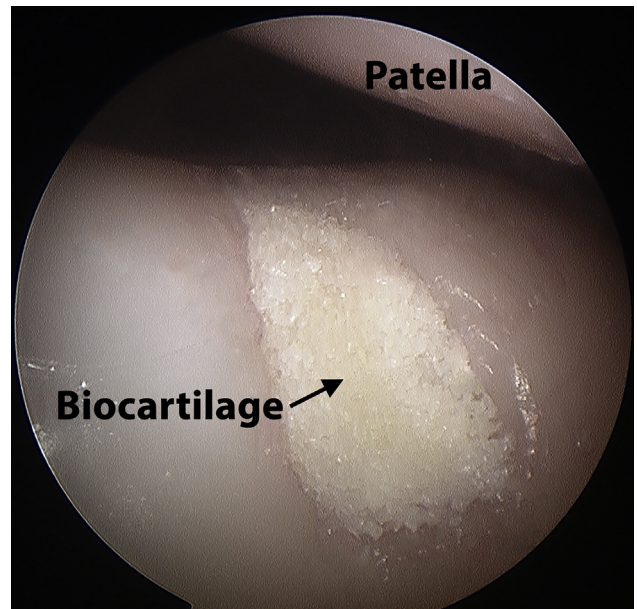
Medical-grade carbon dioxide has been safely used for decades and is used by general surgeons in the peritoneal space during endoscopic procedures. It is highly soluble in blood and effectively exhaled through the lungs.<sup>4-7</sup> Carbon dioxide in the form of gas was the preferred medium for arthroscopy until being replaced by saline solution.<sup>5</sup> A report by Riddell<sup>5</sup> described the use of carbon dioxide in over 3,000 knee arthroscopies without a complication. More recently, Coletti et al.<sup>11</sup> described the use of carbon dioxide arthroscopy for MACI, a procedure that also requires a dry bed for application. Their technique involved a standard saline solution-based arthroscopy; the knee was then drained, and carbon dioxide insufflation was used during the MACI procedure. Vascellari et al.<sup>12</sup> subsequently reviewed the group of patients treated by Coletti et al. and found no complications related to carbon dioxide use. In our experience, this technique



**Fig 2.** The full-thickness chondral defect is identified in the trochlea of the left knee (viewed from anterolateral portal). A probe can be used to further characterize the lesion and the extent of the defect.



**Fig 3.** The defect is debrided of abnormal damaged tissue and measured (left knee). The ruler can be inserted through any portal for ease of maneuvering the instruments (anteromedial portal in this case).

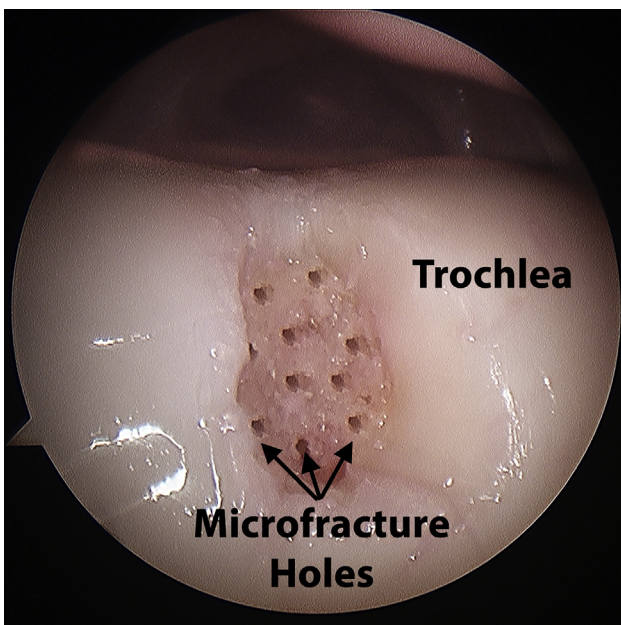


**Fig 5.** BioCartilage is applied over the trochlear defect in a left knee, as viewed from the anterolateral portal. One should note the dry nature of the paste not diluted by saline solution or blood.

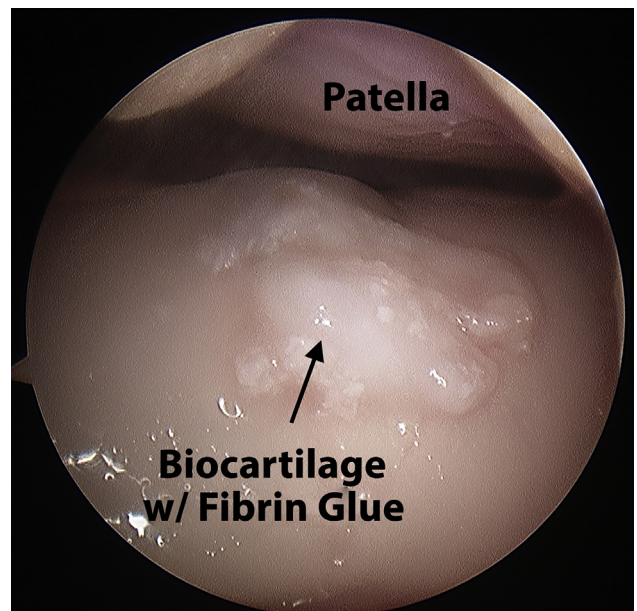
leaves residual fluid in the synovial tissues that drips into the repair bed and compromises BC application. MACI is applied as a single intact collagen scaffold graft with embedded chondrocytes and is placed with fibrin glue. Although this requires a dry environment, the graft is not as affected by residual moisture in the surrounding tissues as is BC and is therefore more

amenable to draining the knee and briefly insufflating with carbon dioxide. By using carbon dioxide for insufflation throughout the procedure, we create a more ideal dry environment for the procedure.

Imbert and Schlatterer<sup>7</sup> published a risk-benefit analysis on the use of carbon dioxide insufflation during anterior cruciate ligament repair. The use of carbon



**Fig 4.** Microfracture is performed with smooth K-wires or a PowerPick on the trochlear defect, as viewed from the anterolateral portal (left knee).



**Fig 6.** Fibrin glue is applied over the BioCartilage, as viewed from the anterolateral portal (left knee).

dioxide in their study was more in accordance with our published technique. The carbon dioxide was used from the onset of the procedure, and saline solution was used only sparingly to cool the shaver or perform irrigation. Their analysis found no difference in end-tidal carbon dioxide levels between the carbon dioxide and saline solution arthroscopy groups and found a faster operative time in the carbon dioxide group.

A fatal or nonfatal air embolism has been described in case studies during carbon dioxide arthroscopy of the shoulder.<sup>14-17</sup> However, this is attributed to insufflation of a joint above the heart and noncollapsible veins being exposed to pressurized gas. It has not been described as a complication of knee arthroscopy.<sup>15</sup> Two previous case studies have described fatal pulmonary embolisms during knee arthroscopy, but in both cases, air—not carbon dioxide—was used to expand the joint. Air is not as readily absorbed by surrounding tissues and is no longer used.<sup>18,19</sup> The most common complication of carbon dioxide knee arthroscopy is subcutaneous emphysema.<sup>4,7,12</sup> In the reported cases, the emphysema was small, was localized, and resolved within hours.<sup>7,12</sup>

In conclusion, carbon dioxide insufflation for knee arthroscopy provides an effective means of visualization and maintaining a dry environment for an effective application of BC or other resurfacing therapies with a relatively safe profile. Further clinical and basic science studies are needed to determine the real effect of this technique.

## References

- Mithoefer K, McAdams T, Williams RJ, Kreuz PC, Mandelbaum BR. Clinical efficacy of the microfracture technique for articular cartilage repair in the knee: An evidence-based systematic analysis. *Am J Sports Med* 2009;37:2053-2063.
- Oussedik S, Tsitskaris K, Parker D. Treatment of articular cartilage lesions of the knee by microfracture or autologous chondrocyte implantation: A systematic review. *Arthroscopy* 2015;31:732-744.
- Goyal D, Keyhani S, Lee EH, Hui JH. Evidence-based status of microfracture technique: A systematic review of the level I and II studies. *Arthroscopy* 2013;29:1579-1588.
- Whipple TL, Caspari RB, Meyers JF. Arthroscopic laser meniscectomy in a gas medium. *Arthroscopy* 1985;1:2-7.
- Riddell RR. CO<sub>2</sub> arthroscopy of the knee. *Clin Orthop Relat Res* 1990;252:92-94.
- Mullett CE, Viale JP, Sagnard PE, et al. Pulmonary CO<sub>2</sub> elimination during surgical procedures using intra- or extraperitoneal CO<sub>2</sub> insufflation. *Anesth Analg* 1993;76:622-626.
- Imbert P, Schlatterer B. A risk-benefit analysis of alternating low-pressure CO<sub>2</sub> insufflation and fluid medium in arthroscopic knee ACL reconstruction. *Knee Surg Sports Traumatol Arthrosc* 2014;22:1483-1490.
- Henche HR. Examination of the liquid- or gas-filled joint. In: *Arthroscopy of the knee joint*. Berlin: Springer, 1980;13-17.
- Johnson LL. *Arthroscopic surgery: Principles and practice*. St Louis: Mosby, 1986.
- Eriksson E, Sebik A. Arthroscopy and arthroscopic surgery in a gas versus a fluid medium. *Orthop Clin North Am* 1982;13:293-298.
- Coletti N, Schiavetti S, Rebuzzi E, Gervasi E. Impianto di condrociti autologhi su scaffold collagenico (MACI) con tecnica artroscopica in ambiente gassoso (CO<sub>2</sub>): Note di tecnica chirurgica. *Scalpello* 2006;20:45-49.
- Vascellari A, Rebuzzi E, Schiavetti S, Coletti N. Implantation of matrix-induced autologous chondrocyte (MACI) grafts using carbon dioxide insufflation arthroscopy. *Knee Surg Sports Traumatol Arthrosc* 2014;22:219-225.
- Mithoefer K, Williams RJ III, Warren RF, et al. The microfracture technique for the treatment of articular cartilage lesions in the knee. A prospective cohort study. *J Bone Joint Surg Am* 2005;87:1911-1920.
- Faure EA, Cook RI, Miles D. Air embolism during anesthesia for shoulder arthroscopy. *Anesthesiology* 1998;89:805-806.
- Hedge RT, Avatgere RN. Air embolism during anaesthesia for shoulder arthroscopy. *Br J Anaesth* 2000;85:926-927.
- Zmistowski B, Austin L, Ciccotti M, Ricchetti E, Williams G Jr. Fatal air embolism during shoulder arthroscopy. *J Bone Joint Surg Am* 2010;92:2125-2127.
- Pandey V, Varghese E, Rao M, et al. Nonfatal air embolism during shoulder arthroscopy. *Am J Orthop (Belle Mead NJ)* 2013;42:272-274.
- Habegger R, Siebenmann R, Kieser CH. Lethal air embolism during arthroscopy. *J Bone Joint Surg Br* 1989;71:314-316.
- Grünwald J, Bauer G, Wruhs O. Fatal complication in arthroscopy in a gaseous medium. *Unfallchirurg* 1987;90:97 [in German].