

Technical Note

Anterior Horn Meniscal Repair Using an Outside-In Suture Technique

Travis J. Menge, M.D., Chase S. Dean, M.D., Jorge Chahla, M.D., Justin J. Mitchell, M.D.,
and Robert F. LaPrade, M.D., Ph.D.

Abstract: The menisci are important structures within the knee that play a critical role in maintaining proper stability, load distribution, and joint lubrication. Injury to the menisci has been found to significantly alter the complex biomechanics of the knee, and thus affect the health and longevity of the native joint. Tears involving the anterior horn are increasingly recognized as an important pathology. Although early treatment of meniscal tears focused primarily on removal of the injured tissue, recent attention on the long-term consequences of partial or total meniscectomy has led to increased attempts at meniscus repair whenever possible. Because of the location of anterior horn tears and the technical difficulty in accessing this location arthroscopically, an outside-in repair technique is ideal for treatment of these lesions. This technical note details our surgical technique of outside-in repair of anterior horn meniscal tears.

The menisci have a critical role in the health and longevity of the knee joint. The menisci function as a secondary stabilizer of the knee and contribute to load transmission and distribution, proprioception, cartilage nutrition, and joint lubrication.¹ If left untreated, meniscal tears can result in harmful effects on the knee and predispose the knee to osteoarthritis.² While surgical repair of the meniscus has been reported to result in higher reoperation rates compared with total or partial meniscectomy, meniscal repairs likely result in improved long-term outcomes, higher activity levels, and slower progression to osteoarthritis.³

Tears of the anterior horn of the lateral meniscus have been shown to significantly increase tibiofemoral contact pressures in both the medial and lateral compartments of the knee.⁴ Furthermore, repair of these tears has been reported to restore contact pressures to normal values.⁴ Therefore, surgical repair of meniscal

lesions is indicated whenever possible. Regarding the anterior horn of the medial meniscus, the current literature is very limited but it is logical to expect similar results. The anterior horn of the medial meniscus has been reported to be particularly important for stabilizing external rotation when the knee is fully extended⁵ as well as preventing anterior femoral displacement.⁶

Commonly used techniques for meniscal repair include inside-out, outside-in, and all-inside techniques. Of these, the outside-in repair technique is ideal for anterior horn tears because it allows for adequate access to the anterior horn of the meniscus, provides a stable fixation construct, and avoids leaving prominent intra-articular material. The purpose of this surgical technique description is to describe the method of outside-in repair of anterior horn meniscal tears.

Objective Diagnosis

Tears of the anterior horn can be difficult to diagnose on both physical examination and through imaging modalities. Most commonly, a patient with an isolated anterior horn tear will present with pain in the anterior aspect of the knee with tenderness to palpation over the anterior joint line of the affected meniscus or with forced knee hyperextension. This presentation can mimic several other entities including pain in Hoffa's fat pad, patellar tendinitis, osteoarthritis, and bony contusion. Although magnetic resonance imaging is typically obtained to evaluate for tears of the menisci, previous studies suggest that magnetic resonance imaging may not provide adequate details of the anterior horn to fully confirm the

From The Steadman Clinic (T.J.M., J.J.M., R.F.L.); and Steadman Philippon Research Institute (T.J.M., C.S.D., J.C., J.J.M., R.F.L.), Vail, Colorado, U.S.A.

The authors report the following potential conflicts of interest or sources of funding: R.F.L. receives support from Arthrex; Ossur; Siemens; Smith & Nephew; Health East, Norway; and an NIH R13 grant for biologics.

Received April 26, 2016; accepted June 13, 2016.

Address correspondence to Robert F. LaPrade, M.D., Ph.D., Steadman Philippon Research Institute, The Steadman Clinic, 181 West Meadow Drive, Suite 400, Vail, CO 81657, U.S.A. E-mail: drlaprade@sprivail.org

© 2016 by the Arthroscopy Association of North America

2212-6287/16347/\$36.00

<http://dx.doi.org/10.1016/j.eats.2016.06.005>

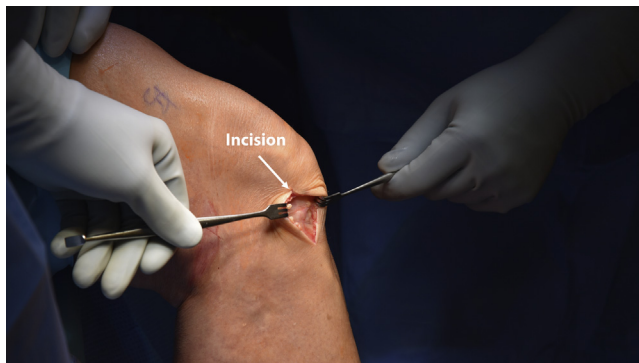

Fig 1. A vertical incision (arrow) is made through the skin and subcutaneous tissues on a right knee to expose the joint capsule by extending the lateral portal incision 2-3 cm, which is on the ipsilateral side of the affected (lateral) meniscal tear.

diagnosis.⁷ Arthroscopic intervention and probing of the tear may be required to fully confirm the diagnosis.

Surgical Technique

Surgical Indications

When a repairable tear is identified of the anterior horn of the meniscus, suture repair of the tear is preferred. Indications for an outside-in technique are similar to those established for traditional inside-out techniques; however, this technique can be performed without the use of special meniscal repair devices, as discussed in the following sections. Tears in the peripheral two-thirds of the anterior horn are typically indicated for repair because of the increased healing capacity of this location, whereas free edge tears of the central one-third may be treated with partial meniscectomy.

Patient Positioning

The patient is placed in the supine position on the operating table. After induction of general anesthesia, a bilateral knee examination is performed to evaluate the

injured knee, and abnormalities compared with the uninjured side are noted. A well-padded thigh tourniquet is placed on the operative leg and the leg is placed into a leg holder (Mizuho OSI, Union City, CA), whereas the contralateral knee is placed into an abduction stirrup (Birkova Product LLC, Gothenburg, NE). The foot of the operating table is lowered, allowing for the surgeon to freely manipulate the knee as needed. The operative extremity is then prepped and draped in the usual sterile fashion.

Diagnostic Arthroscopy

The arthroscopy is performed through standard anterolateral and anteromedial portals to confirm and evaluate the damaged meniscus, as well as any additional concomitant intra-articular pathology. The arthroscope is placed through the contralateral portal of the compartment of the involved meniscus to visualize the extent of the tear (i.e., the arthroscope is best placed through a medial portal when the lateral meniscus is torn, and vice versa). A spinal needle is used to locate proper placement for the second working portal, which is on the ipsilateral compartment of the knee as the involved meniscus ([Video 1](#)).

Outside-In Meniscal Repair

After a complete arthroscopic assessment, a 2- to 3-cm vertical incision is made in line with the portal on the same side of the knee as the anterior meniscal tear. Careful dissection is performed through the subcutaneous tissues to expose the underlying joint capsule ([Fig 1](#)).

With the arthroscope in the contralateral viewing portal, an outside-in repair is performed by first using a spinal needle from an outside-in repair kit (Meniscus Mender II; Smith and Nephew, Andover, MA) to pierce the overlying capsule. The spinal needle is then advanced under the anterior edge of the medial or lateral meniscus and through the body of the anterior horn, thus traversing the area of the tear ([Fig 2](#)).

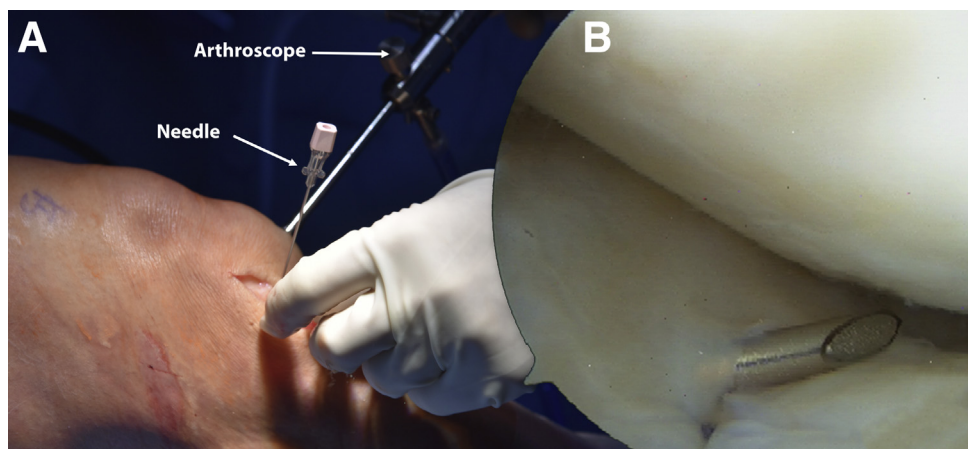


Fig 2. (A) Intraoperative photograph of right knee. A spinal needle (arrow) is advanced through the lateral capsule, under the anterior edge of the torn lateral meniscus, and through the meniscal body on a right knee. (B) Arthroscopic image of the same knee demonstrating a 30° arthroscope (arrow) placed through the contralateral medial portal for adequate visualization.

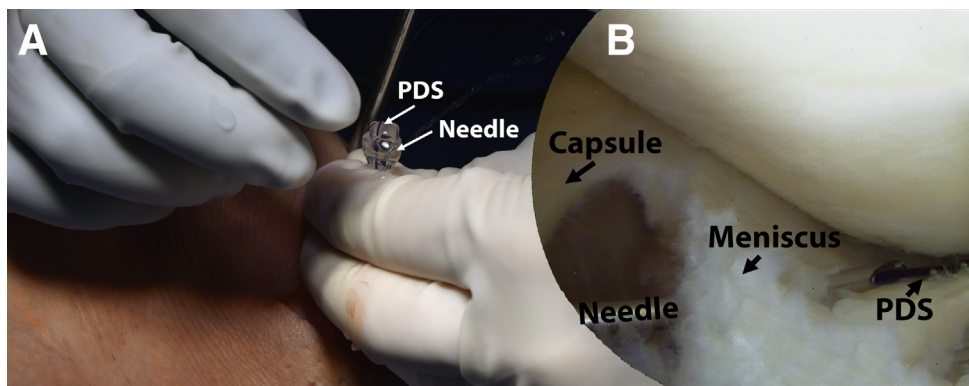


Fig 3. (A) Intraoperative photograph of right knee. The inner cannula of the needle (arrow) is removed and a No. 1 polydioxanone (PDS) suture (arrow) is passed through the needle, thus traversing the anterior lateral meniscal tear. (B) Arthroscopic image of the same knee demonstrating as visualized using a 30 arthroscope through the contralateral medial portal of a right knee. This demonstrates the passage of the PDS suture through the anterior horn of the meniscus.

The inner cannula of the needle is removed, and a No. 1 polydioxanone (PDS) suture (Ethicon, Somerville, NJ) is placed through the needle into the joint. An arthroscopic grasper is used to secure the free end of the suture while the needle is subsequently removed, leaving the suture in the joint (Fig 3).

A second pass is made with the spinal needle through the capsule, under the anterior edge of the meniscus, and through the body of the anterior horn in a similar manner as before. The inner cannula is again removed, and a looped suture retriever is passed through the second needle into the joint. The free end of the previously-passed PDS suture is then placed through the looped retriever using a grasper, and the suture pulled back out of the knee creating a mattress suture construct to secure the anterior horn (Fig 4).

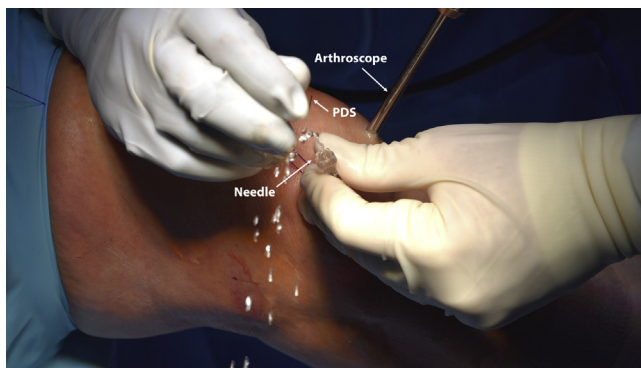

Fig 4. The spinal needle (arrow) is passed a second time in a similar manner as before through the lateral incision of a right knee, and the free end of the previously passed No. 1 polydioxanone (PDS) suture (arrow) is retrieved through the spinal needle using a grasper (arrow) and looped suture retriever. The grasper is placed through a second lateral working portal. This creates a horizontal or vertical mattress suture across the anterior horn of the lateral meniscus, depending on the type of tear and surgeon preference. A 30° arthroscope (arrow) is present in the medial portal.

Either a horizontal or vertical mattress suture configuration can be used, depending on the nature of the tear and surgeon preference. In addition, although 2 or 3 sutures are usually sufficient for smaller tears, this technique can be used to place as many sutures as necessary to adequately repair the lesion (Fig 5). Technical pearls for outside-in meniscal repair are outlined in Table 1, whereas risks and common pitfalls are discussed in Table 2.

Wound Closure

Once the outside-in repair is complete, the sutures are tied to the anteromedial/lateral capsule (Fig 6) with the knee flexed to 90° and the final construct is assessed (Fig 7). The excess fluid is drained from the knee and the incision is closed in a layer fashion with 2-0 Vicryl sutures (Ethicon) followed by a running 4-0 Monocryl

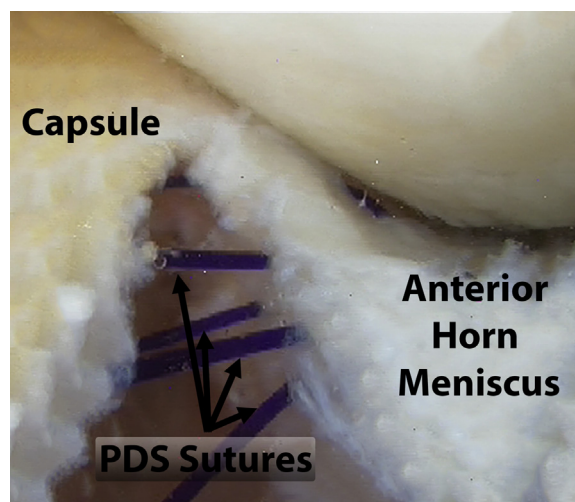


Fig 5. Two No. 1 polydioxanone (PDS) sutures (arrows) have been passed in a horizontal mattress configuration to repair the lateral meniscal tear of a right knee as viewed with a 30° arthroscope through the medial portal.

Table 1. Pearls for Surgical Treatment of Anterior Horn Meniscal Injuries

Pearls
<ul style="list-style-type: none"> • The arthroscope should be placed in the contralateral portal to the meniscus tear for optimal visualization and evaluation of anterior horn tears. • The distance between the sutures should be 3-5 mm. • Either a horizontal or vertical mattress suture configuration can be used, depending on the nature of the tear. • Use as many sutures as necessary to stabilize the tear.

suture (Ethicon) in the subdermal layer. Steri-Strips are applied followed by a soft dressing.

Postoperative Recovery and Rehabilitation

After surgery, the patient is placed in a knee immobilizer (Ossur, Reykjavik, Iceland) in full extension and allowed to partial bear (40 pounds, or 18 kg) with crutches for the first 6 weeks. Physical therapy is initiated on postoperative day 1 to begin working on passive range of motion exercises. Knee flexion is limited to 0° to 90° for the first 4 weeks, and then progressed as tolerated. Any significant squatting, lifting, or sitting cross-legged is avoided for a minimum of 4 months to avoid excess stress on the meniscal repair.

Discussion

This technical note details an outside-in technique for repair of anterior horn tears of the menisci. Although the current literature is limited regarding anterior meniscal horn tears, injury to the menisci has been found to significantly alter the complex biomechanics of the knee, and thus affect the health and longevity of the native joint. Because of the location of anterior horn tears and the technical difficulty in accessing this location arthroscopically, an outside-in repair technique is ideal for treatment of these lesions.

Table 2. Risks of Surgical Treatment of Anterior Horn Meniscal Tears, and Strategies For Avoidance

Risks/Pitfalls	How to Avoid Them
Scarring or contracture of the overlying capsule, preventing proper closure of the tear	Careful dissection and release of the anterior capsule, with removal of any scar tissue
Difficulty retrieving suture after it has been passed through meniscus	Use of a looped suture retriever passed through the spinal needle and an arthroscopic grasper
Loss of knee motion and/or stiffness postoperatively	Early gentle range of motion (0° to 90°) with an experienced physical therapist
Deep venous thrombosis	Use of intraoperative mechanical compression devices and postoperative chemical and mechanical prophylaxis as determined by patient risk factors

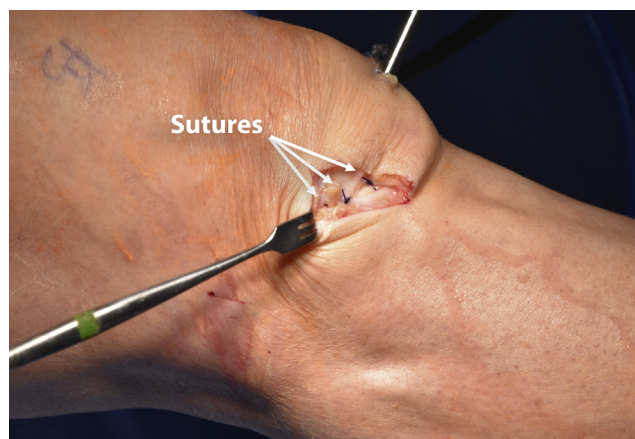
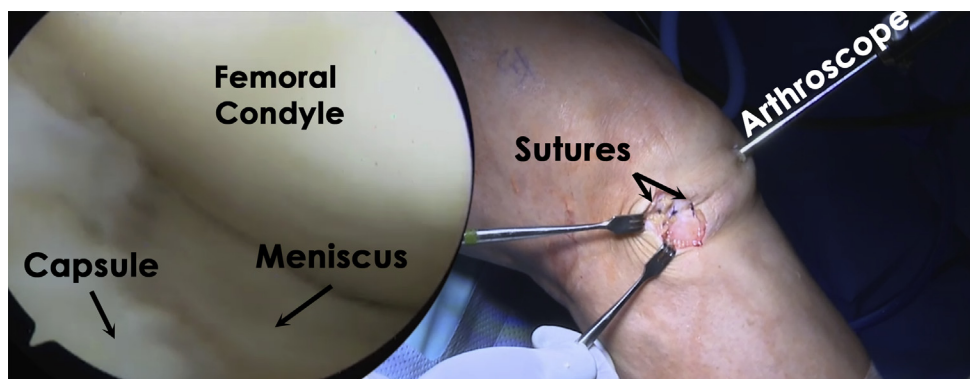


Fig 6. The suture tails (arrows) are appropriately tensioned and tied over the lateral joint capsule of a right knee, thus securing the anterior horn of the lateral meniscus to the capsule to allow healing of the tear.

Biomechanical studies have documented the importance of the anterior horn of the lateral meniscus to knee joint function. Walker et al.⁶ suggested that on the medial side of the knee, the load is shared approximately equally between the meniscus and exposed cartilage, whereas the lateral meniscus carries most of the load on the lateral side of the knee joint. Biomechanical studies have found that the maximal tibiofemoral contact pressures are located in the posterior region of the medial meniscus (with average values of 2.9 MPa) and in the anterior horn of the lateral meniscus (1.45 MPa).⁸ Prince et al.⁴ reported that nonrepaired tears and meniscectomy of the anterior horn of the lateral meniscus cause a significant increase in peak contact forces in the lateral compartment, especially at 30° of flexion where the percentage of peak contact pressure increased by 78% compared with the intact state. Furthermore, repairing the anterior horn of the lateral meniscus can restore peak contact forces to similar values of the native knee.⁴ Thus, these studies provide validation for attempts to perform anterior horn meniscal repairs clinically.

Choi and Victoroff⁹ published a case series of anterior horn tears of the lateral meniscus in 14 soccer players (mean age 20.2 years). Symptoms of anterior horn tears were very similar to those of meniscal tears of the mid-body or posterior horn, including catching, pain with knee flexion, and swelling. Of the 14 athletes, 8 repairs were performed, 5 patients underwent a partial meniscectomy, and 1 patient had a partial meniscectomy plus repair. Repairs were performed using an all-inside suture technique through a modified anterolateral portal. All patients returned to their previous level of soccer 6 months after surgery and reported full range of motion of the affected knee at 2-year follow-up. However, long-term follow-up and differences between the repaired versus resected groups were not reported.

Fig 7. The repaired anterior horn of the lateral meniscus (arrow) is visualized arthroscopically after the completion of the outside-in suture technique in a right knee.



Hagino et al.¹⁰ also reported on 8 athletes with a mean age of 18.6 years who underwent repair of the anterior horn of the lateral meniscus. Clinical findings at presentation were pain at the anterolateral aspect of the knee during knee extension and pain during weight bearing. Two tears were repaired, 5 were treated by partial excision, and 1 by rasping only. The mean Lysholm score was 65 before surgery, and improved to 89 at an average of 12 months after surgery.¹⁰ Although all patients showed improvements in their Lysholm score and returned to their previous level of sport, there were again no comparisons made between those who underwent meniscal repair and those who underwent partial excision or rasping in this relatively small cohort.

Osti et al.¹¹ described an all-inside suture anchor technique to repair tears of the anterior root of the medial meniscus. At 1-year follow-up, the average Lysholm scores significantly improved from 48 points preoperatively to 91 points postoperatively ($P < .001$). Furthermore, 5 patients (45.3%) were scored as excellent (≥ 95 points), whereas 7 more (54.6%) were considered good (85-94 points). In active patients, 89% ($n = 8$) returned to the same preoperative level of sport, and 1 patient (11%) returned to a lower level of activity. No complications were reported.¹¹

Table 3. Advantages and Limitations of an Outside-In Suture Approach to Anterior Horn Meniscal Tears

Advantages	Limitations
Significant improvements in short-term postoperative outcome measures and return to sport after repair	Long-term outcome studies are limited
Better restores native biomechanics of the torn meniscus compared with partial or total meniscectomy	Postoperative rehabilitation and weight-bearing restrictions require proper patient compliance and longer return to activity compared with meniscectomy
Anatomic fixation	High technical demand and steep learning curve

As our knowledge regarding anterior horn meniscal tears continues to evolve, repair of these tears is recommended whenever possible to restore proper kinematic and biomechanical properties about the knee. The advantages and limitations of this technique compared with partial or total meniscectomy are outlined in Table 3. Although the current literature is limited to small cohorts with short-term follow-up, these studies have shown significant improvements in postoperative outcome measures and return to sport after arthroscopic repair. Future long-term studies with larger samples are needed to assess the efficacy and patient-reported outcome measures of anterior horn meniscal repair versus meniscectomy. Because of the important role of the menisci in the health and longevity of the knee joint, we recommend our approach for anterior horn tears of both the medial and lateral meniscus as a simple and cost-effective repair method to preserve the meniscus.

References

- Allen AA, Caldwell GL Jr, Fu FH. Anatomy and biomechanics of the meniscus. *Oper Tech Orthop* 1995;5: 2-9.
- Hede A, Larsen E, Sandberg H. The long term outcome of open total and partial meniscectomy related to the quantity and site of the meniscus removed. *Int Orthop* 1992;16:122-125.
- Xu C, Zhao J. A meta-analysis comparing meniscal repair with meniscectomy in the treatment of meniscal tears: The more meniscus, the better outcome? *Knee Surg Sports Traumatol Arthrosc* 2015;23:164-170.
- Prince MR, Esquivel AO, Andre AM, Goitz HT. Anterior horn lateral meniscus tear, repair, and meniscectomy. *J Knee Surg* 2014;27:229-234.
- Chen L, Linde-Rosen M, Hwang SC, et al. The effect of medial meniscal horn injury on knee stability. *Knee Surg Sports Traumatol Arthrosc* 2015;23:126-131.
- Walker PS, Arno S, Bell C, Salvatore G, Borukhov I, Oh C. Function of the medial meniscus in force transmission and stability. *J Biomech* 2015;48:1383.

7. Shepard MF, Hunter DM, Davies MR, Shapiro MS, Seeger LL. The clinical significance of anterior horn meniscal tears diagnosed on magnetic resonance images. *Am J Sports Med* 2002;30:189-192.
8. Peña E, Calvo B, Martínez MA, Palanca D, Doblaré M. Finite element analysis of the effect of meniscal tears and meniscectomies on human knee biomechanics. *Clin Biomech* 2005;20:498-507.
9. Choi NH, Victoroff BN. Anterior horn tears of the lateral meniscus in soccer players. *Arthroscopy* 2006;22:484-488.
10. Hagino T, Ochiai S, Sato E, Watanabe Y, Senga S. Footballer's lateral meniscus: Anterior horn tears of the lateral meniscus with a stable knee. *ISRN Surg* 2011;2011:170402.
11. Osti L, Del Buono A, Maffulli N. Anterior medial meniscal root tears: A novel arthroscopic all inside repair. *Transl Med UniSa* 2014;12:41-46.