

# An Anatomic Analysis of Mid-anterior and Anterolateral Approaches for Hip Arthrocentesis: A Male Cadaveric Study

Jacob D. Mikula, B.S., Jason M. Schon, B.S., Chase S. Dean, M.D., Jorge Chahla, M.D., Renato Locks, M.D., Alex W. Brady, M.Sc., Robert F. LaPrade, M.D., Ph.D., and Marc J. Philippon, M.D.

**Purpose:** To determine the accuracy and safety of non-image-guided modified mid-anterior and anterolateral approaches to the hip joint for arthrocentesis. **Methods:** Six pairs ( $n = 12$ ) of human cadaveric hemipelvises underwent methylene blue hip injections through either a mid-anterior or an anterolateral approach. The distance from the mid-anterior approach to the lateral femoral cutaneous nerve (LFCN) was measured. Needle orientation was defined by a combination of 2 angles, calculated by the computer software analysis of digitized points. Distal Angle was defined as the angle between the lateral axis and an intermediate needle position, in the coronal plane, toward the distal axis. Anterior Angle was defined as the angle between the intermediate needle position of Distal Angle and the final position, toward the anterior axis. **Results:** Methylene blue was successfully injected into the joint capsule in all specimens. The mean distances from the needle to the LFCN for both the mid-anterior and anterolateral approaches were  $19.3 \pm 7.9$  and  $80.3 \pm 28.3$  mm, respectively. For the mid-anterior approach, Distal Angle<sub>M</sub> was a mean of  $53.9^\circ \pm 14.9^\circ$  and Anterior Angle<sub>M</sub> was a mean of  $33.4^\circ \pm 15.6^\circ$ . For the anterolateral approach, Distal Angle<sub>L</sub> was a mean of  $14.5^\circ \pm 14.2^\circ$  and Anterior Angle<sub>L</sub> was a mean of  $4.5^\circ \pm 13.6^\circ$ . **Conclusions:** This study showed that mid-anterior and anterolateral approaches for non-image-guided hip injections or arthrocentesis can avoid the LFCN and be effectively performed in males, despite the exhibited variability in the quantitative descriptions of these techniques. The landmarks and measurements presented can be used as general guidelines for clinical studies regarding hip arthrocentesis and injections. **Clinical Relevance:** The high variability of the needle placement and trajectory of the mid-anterior and anterolateral approaches performed in this study showed that these techniques were not easily quantitatively defined. However, both of these approaches appeared to be safe and effective.

The ability to enter the hip joint safely and reliably is becoming increasingly important, particularly with the increased popularity of hip arthroscopy. In addition, arthrocentesis and intra-articular injections of the hip

joint are widely used to provide targeted, local therapy to patients and as a diagnostic aid for physicians treating hip pathologies.<sup>1-3</sup> The methods used to access the hip joint capsule vary with regard to location and technique.

There are multiple approaches to percutaneously reach the hip joint, including the lateral approach,<sup>4</sup> the anterolateral approach,<sup>5</sup> and variations on the anterior<sup>4,6</sup> and mid-anterior approaches.<sup>7</sup> Disparity exists regarding the efficacy and safety of these approaches. In particular, the mid-anterior approach directly places the lateral femoral cutaneous nerve (LFCN) at risk because of its proximity to the nerve. Kurup and Ward<sup>8</sup> reported a success rate of 65% for entering the hip joint capsule with an anterolateral approach in 40 patients without radiologic assistance. A recent study by Singh et al.<sup>6</sup> documented a 67% overall success rate in 100 patients without radiologic guidance. One group<sup>2</sup> published a 93% success rate using an anterior approach in 54 hips.

From the Department of BioMedical Engineering, Steadman Philippon Research Institute (J.D.M., J.M.S., C.S.D., J.C., R.L., A.W.B., R.F.L., M.J.P.); and The Steadman Clinic (R.F.L., M.J.P.), Vail, Colorado, U.S.A.

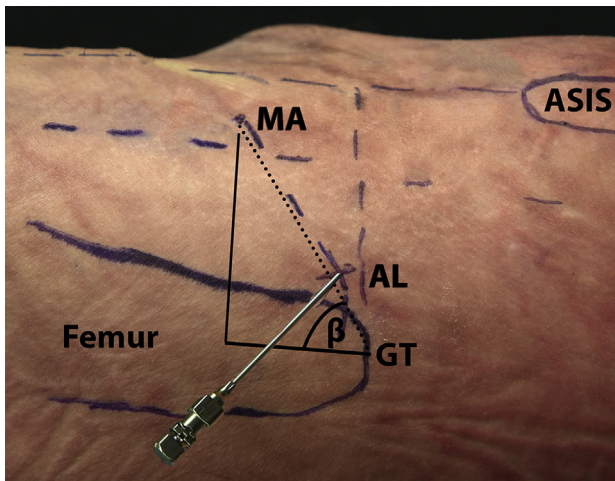
The authors report the following potential conflicts of interest or sources of funding: M.J.P. and R.F.L. receive support from Arthrex; Ossur; Siemens; Smith & Nephew; Health East, Norway; and an NIH R-13 grant for biologics. R.F.L. is a consultant and receives royalties from Arthrex, Ossur, and Smith & Nephew.

Received July 18, 2016; accepted September 28, 2016.

Address correspondence to Marc J. Philippon, M.D., Steadman Philippon Research Institute, 181 W Meadow Dr, Vail, CO 81657, U.S.A. E-mail: [m@mjphilippon.com](mailto:m@mjphilippon.com)

© 2016 by the Arthroscopy Association of North America  
0749-8063/16666/\$36.00

<http://dx.doi.org/10.1016/j.arthro.2016.09.037>



**Fig 1.** Location of the anterolateral approach (AL) in relation to the ASIS and the GT. (ASIS, anterior superior iliac spine; GT, greater trochanter; GT angle ( $\beta$ ), the angle between the longitudinal axis and the needle with the vertex at GT; MA, mid-anterior approach.)

Non-image-guided intra-articular injections are routinely performed in the shoulder, knee, and ankle joints by referencing anatomical landmarks.<sup>9,10</sup> However, previous studies reported poor results using anatomical landmarks for intra-articular hip injections.<sup>3,4</sup> Nonetheless, validation of a consistent anatomic methodology is clinically important because it is readily available in most physicians' offices, and it has no added cost and does not require an ultrasound or a fluoroscope to assess the needle position.

The purpose of this study was to determine the accuracy and safety of non-image-guided modified mid-anterior and anterolateral approaches to the hip joint for arthrocentesis. The null hypothesis was that no difference would be observed in the injection success between the 2 non-image-guided techniques.

## Methods

### Cadaveric Specimen Hip Injections

Six male paired ( $n = 12$ ) fresh-frozen human cadaveric hemipelvises and femurs (mean age: 52.3 years; range: 32-65 years) with no prior injury, surgical history, or gross anatomic abnormality were placed in a supine position on a surgical table. Male specimens were used in this study to minimize variability between specimens. The hemipelvis was fixed in a stationary position and the femur was held in maximal internal rotation for each specimen to neutralize the femoral neck anteversion, and one experienced hip arthroscopist (M.J.P.) injected 2 mL of 0.1% methylene blue (Ricca Chemical Company, Arlington, TX) into the hip with a 17-gauge, 6.0-inch

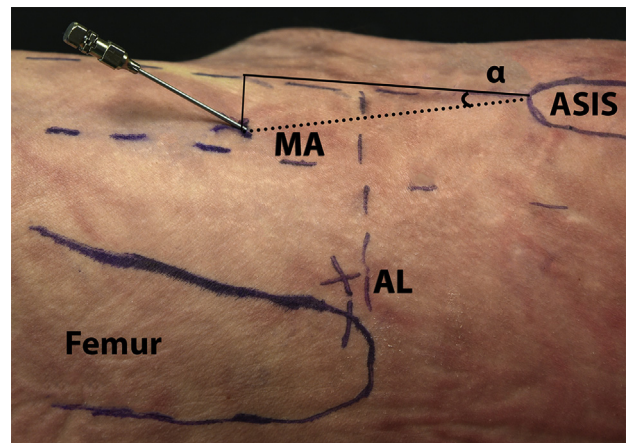
spinal needle. No traction was applied to simulate a clinical environment. The 2 different approaches compared were the anterolateral approach on one hemipelvis and the mid-anterior approach on the contralateral side. The side of the injection techniques was randomized to minimize incremental testing bias.

The standard anterolateral approach to hip injections was performed as previously described<sup>11</sup> by inserting the needle horizontally at the superomedial tip of the greater trochanter until the needle reached bone (Fig 1). The modified mid-anterior approach was performed by drawing a line along the longitudinal axis of the body starting at the anterior superior iliac spine (ASIS). An additional line was drawn longitudinally midway between the ASIS and the greater trochanter. A third line was drawn starting at the anterolateral portal roughly 45° inferior from the transverse axis. The needle was inserted just medial to the intersection of these lines (Fig 2).

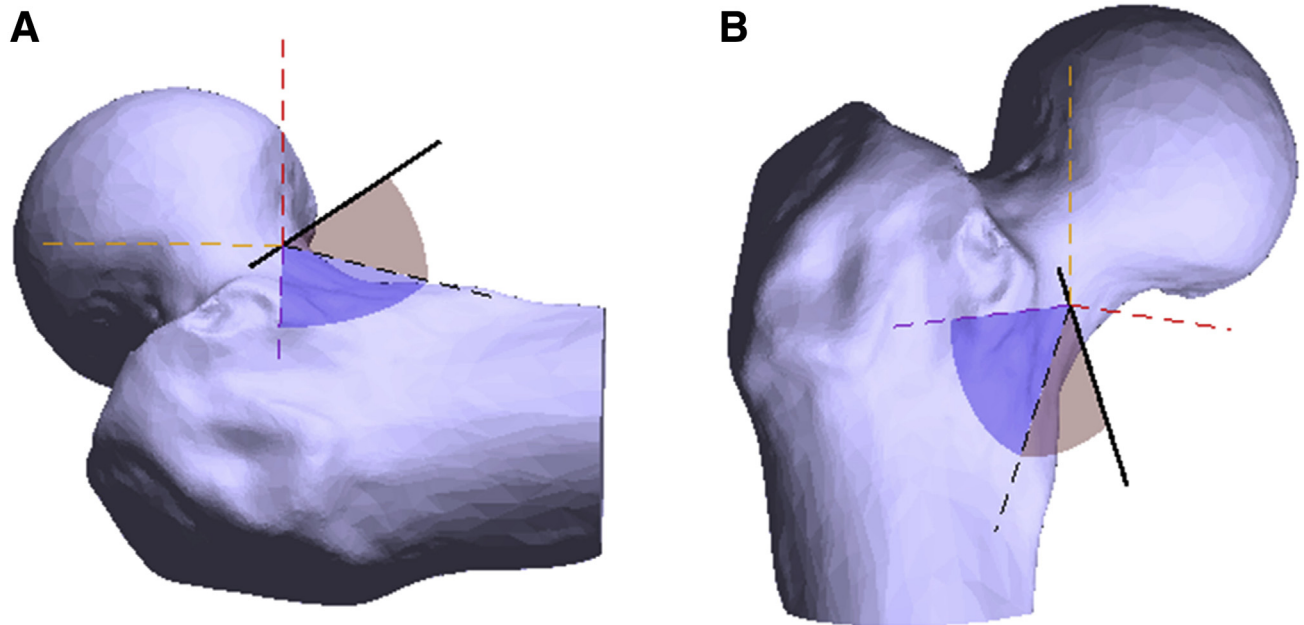
After injection of the methylene blue dye, the needle was further progressed to avoid altering the needle trajectory and a 9" 1.1-mm single trocar K-wire (Millennium Surgical, Narberth, PA) was drilled through the spinal needle to ensure that the needle did not change position throughout the dissection process. Skin measurements were performed as described below, and then the hemipelvises were dissected to measure the distance between the needles, the LFCN, and bony landmarks. In addition, the presence or absence of dye within the joint capsule was assessed.

### Distance Measurements

Skin measurements were recorded after placement of the needle for the purposes of identifying the precise location of the needle in relation to anatomic



**Fig 2.** Location of the mid-anterior approach (MA) in relation to the ASIS and the GT. (AL, anterolateral approach; ASIS, anterior superior iliac spine; ASIS angle ( $\alpha$ ), the angle between the longitudinal axis and the needle with the vertex at ASIS; GT, greater trochanter.)



**Fig 3.** Definition of needle angles. (A) Lateral-medial and (B) anterior-posterior visual depictions of how the needle angle measurements were obtained (right femur).

landmarks. All skin measurements were performed with an electronic digital caliper (Fowler Company, Newton, MA; manufacturer-reported accuracy of 0.02 mm). Two lines were drawn inferior along the longitudinal axis of the femur, one from the ASIS (ASIS line) and another from the greater trochanter line. A transverse line was drawn medially and laterally from the insertion point of the needle until it intersected with the 2 longitudinal lines.

Next, distances were measured to orient the needle with respect to the ASIS and the greater trochanter. First, the distance was measured from the needle to the intersection of the transverse line and the ASIS line, and from the ASIS to the aforementioned intersection of the lines. After the distance measurements were made, the angle between the longitudinal axis and the needle ( $\alpha$ ) with the vertex at the ASIS was calculated (Fig 2). These angles provide a means to describe the needle placement and trajectory with respect to commonly used anatomic landmarks (ASIS and greater trochanter) for hip injections. Finally, distances were measured in a similar fashion from the intersection of

the transverse line and the greater trochanter line to the needle and the greater trochanter, respectively. After the distance measurements were made, the angle between the longitudinal axis and the needle ( $\beta$ ) with the vertex at the greater trochanter was calculated (Fig 1). Finally, the skin and subcutaneous tissue were carefully dissected to expose the LFCN and the distance from the insertion point of each needle to the nearest branch of the LFCN was measured.

Inter-rater and intra-rater reliability for distance measurements and calculations were evaluated by calculating intraclass correlations (ICC) for each measure. The ICC values were interpreted as follows: ICC < 0.40 = poor agreement,  $0.4 \leq \text{ICC} < 0.75$  = fair to good agreement, ICC  $\geq 0.75$  = excellent agreement.<sup>12</sup>

### Needle Angle Measurements

All points were collected using a portable measuring device (Romer Absolute Arm, Hexagon Metrology, North Kingstown, RI) and were imported to computational modeling software (Matlab, MathWorks, Natick, MA) for analysis. A coordinate frame system was

**Table 1.** ICC Calculations for Distance Measurements and Calculations Performed for the Mid-anterior and Anterolateral Approaches

| Measurement             | Mid-anterior Approach |             | Anterolateral Approach |             |
|-------------------------|-----------------------|-------------|------------------------|-------------|
|                         | ICC (Inter)           | ICC (Intra) | ICC (Inter)            | ICC (Intra) |
| ASIS to transverse line | 0.981                 | 0.999       | 0.997                  | 0.999       |
| Needle to ASIS line     | 0.985                 | 0.994       | 0.993                  | 0.998       |
| ASIS angle ( $\alpha$ ) | 0.983                 | 0.998       | 0.991                  | 0.998       |
| GT to transverse line   | 0.949                 | 0.980       | 0.942                  | 0.895       |
| Needle to GT line       | 0.978                 | 0.983       | 0.974                  | 0.985       |
| GT angle ( $\beta$ )    | 0.961                 | 0.981       | 0.982                  | 0.881       |

NOTE. ASIS/GT to transverse line = distance from the ASIS/GT to a lateral/medial line extending from the needle. Needle to ASIS/GT line = distance from the needle to a line extending inferiorly from the ASIS/GT along the longitudinal axis of the femur. ASIS/GT angle ( $\alpha/\beta$ ) = the angle between the longitudinal axis and the needle with the vertex at the ASIS/GT.

ASIS, anterior superior iliac spine; GT, greater trochanter; ICC, intraclass correlation.

defined for the femur with the hemipelvis positioned in neutral rotation and at 0° of hip flexion. The longitudinal (superior-inferior) femoral axis, as seen in the coronal and sagittal planes, was defined by interpolating a line through the centers of 3 rings collected around the femur. The anteroposterior axis, as seen in the sagittal and transverse planes, was defined as perpendicular to the superior axis and perpendicular to the most medial and lateral points on the superior femoral ring. The mediolateral axis, as seen in the coronal and transverse planes, was defined as perpendicular to the superior and anterior axes. Three points were collected along the needle and a line was interpolated through those points to describe needle

**Table 2.** Distance Measurements and Calculations Made for the Mid-anterior Approach

| Measurement                 | Mean $\pm$ SD   | Median (Range)   |
|-----------------------------|-----------------|------------------|
| LFCN to the needle, mm      | 19.3 $\pm$ 7.9  | 18.0 (11.8-30)   |
| ASIS to transverse line, mm | 92.0 $\pm$ 11.6 | 97.1 (69.4-99.3) |
| Needle to ASIS line, mm     | 28.2 $\pm$ 9.9  | 32.2 (15.0-40.0) |
| ASIS angle ( $\alpha$ ), °  | 17.3 $\pm$ 6.7  | 18.9 (8.8-25.7)  |
| GT to transverse line, mm   | 40.4 $\pm$ 6.5  | 40.1 (31.5-48.9) |
| Needle to GT line, mm       | 77.6 $\pm$ 11.4 | 81.1 (59.8-92.7) |
| GT angle ( $\beta$ ), °     | 62.1 $\pm$ 6.0  | 61.4 (56.0-69.1) |

NOTE. LFCN to the needle = distance from the LFCN to the needle. ASIS/GT to transverse line = distance from the ASIS/GT to a lateral/medial line extending from the needle. Needle to ASIS/GT line = distance from the needle to a line extending inferiorly from the ASIS/GT along the longitudinal axis of the femur. ASIS/GT angle ( $\alpha/\beta$ ) = the angle between the longitudinal axis and the needle with the vertex at the ASIS/GT.

ASIS, anterior superior iliac spine; GT, greater trochanter; LFCN, lateral femoral cutaneous nerve; SD, standard deviation.

orientation. The Distal Angle was defined as the angle between the lateral axis and an intermediate needle position, in the coronal plane toward the inferior (femoral) axis. The intermediate needle position was used as a theoretical “placemaker” between the Distal Angle and the Anterior Angle. The Anterior Angle was defined as the angle between the intermediate needle position of Distal Angle and the final position, toward the anterior axis. Thus, by applying the rotations sequentially starting from the lateral axis, the needle was brought to the adequate orientation (Fig 3).

## Results

Inter-rater and intra-rater reliability for distance measurements and calculations yielded excellent results for both approaches (Table 1). All distance measurements and calculations for the mid-anterior and anterolateral approaches are presented in Tables 2 and 3. All data were reported as mean  $\pm$  standard deviation and median (range).

### Injection Success and Safety

Methylene blue was successfully injected into the joint capsule in all 6 specimens using the anterolateral approach and in all 6 specimens where the mid-anterior approach was used. None of the needles inserted through either approach perforated the LFCN and the closest distance to the nerve was 11.8 mm for the mid-anterior approach.

### Distance Measurements

The mean distances from the needle to the LFCN for both the mid-anterior and anterolateral approaches were 19.3  $\pm$  7.9 and 80.3  $\pm$  28.3 mm, respectively. The results presented in Tables 2 and 3 show the high

**Table 3.** Distance Measurements and Calculations Made for the Anterolateral Approach

| Measurement                 | Mean $\pm$ SD   | Median (Range)    |
|-----------------------------|-----------------|-------------------|
| LFCN to the needle, mm      | 80.3 $\pm$ 28.3 | 71.4 (57.2-131.2) |
| ASIS to transverse line, mm | 78.7 $\pm$ 12.4 | 76.0 (64.9-95.1)  |
| Needle to ASIS line, mm     | 86.7 $\pm$ 26.2 | 74.1 (66.8-127.5) |
| ASIS angle ( $\alpha$ ), °  | 47.0 $\pm$ 7.7  | 47.9 (35.1-54.7)  |
| GT to transverse line, mm   | 27.0 $\pm$ 5.3  | 25.3 (21.7-35.8)  |
| Needle to GT line, mm       | 25.2 $\pm$ 7.0  | 24.7 (16.3-37.6)  |
| GT angle ( $\beta$ ), °     | 42.7 $\pm$ 7.1  | 44.3 (33.4-50.5)  |

NOTE. LFCN to the needle = distance from the LFCN to the needle. ASIS/GT to transverse line = distance from the ASIS/GT to a lateral/medial line extending from the needle. Needle to ASIS/GT line = distance from the needle to a line extending inferiorly from the ASIS/GT along the longitudinal axis of the femur. ASIS/GT angle ( $\alpha/\beta$ ) = the angle between the longitudinal axis and the needle with the vertex at the ASIS/GT.

ASIS, anterior superior iliac spine; GT, greater trochanter; LFCN, lateral femoral cutaneous nerve; SD, standard deviation.

**Table 4.** Calculated Angles From the Mid-anterior and Anterolateral Approaches to the Hip Joint

| Angle                           | Mid-anterior Approach |                     | Angle                           | Anterolateral Approach |                     |
|---------------------------------|-----------------------|---------------------|---------------------------------|------------------------|---------------------|
|                                 | Mean $\pm$ SD         | Median (Range)      |                                 | Mean $\pm$ SD          | Median (Range)      |
| Distal Angle <sub>M</sub> , °   | 53.9 $\pm$ 14.9       | 56.7 (31.5 to 71.3) | Distal Angle <sub>L</sub> , °   | 14.5 $\pm$ 14.2        | 9.7 (1.5 to 37.5)   |
| Anterior Angle <sub>M</sub> , ° | 33.4 $\pm$ 15.6       | 34.8 (15.8 to 55.2) | Anterior Angle <sub>L</sub> , ° | 4.5 $\pm$ 13.6         | 3.5 (-11.8 to 23.0) |

NOTE. Distal Angle<sub>M/L</sub> = the angle between the lateral axis and an intermediate needle position, in the coronal plane toward the distal axis. Anterior Angle<sub>M/L</sub> = the angle between the intermediate needle position of Distal Angle<sub>M/L</sub> and the final position, toward the anterior axis. SD, standard deviation.

degree of variability amongst the measured distances and calculated angles.

### Angle Measurements

**Mid-anterior Approach.** The mean angle for the Distal Angle<sub>M</sub> was 53.9°  $\pm$  14.9° and the mean angle for the Anterior Angle<sub>M</sub> was 33.4°  $\pm$  15.6° (Table 4).

**Anterolateral Approach.** The mean angle for the Distal Angle<sub>L</sub> was 14.5°  $\pm$  14.2° and the mean angle for the Anterior Angle<sub>L</sub> was 4.5°  $\pm$  13.6° (Table 4).

### Discussion

The most important finding of this study was that there was very high variability in needle orientation and positioning with respect to anatomic landmarks and calculated angles for both the mid-anterior and anterolateral non-image-guided approaches for intra-articular injections or arthrocentesis of the hip joint. Of note, the standard deviation of the needle angle was greater than 13.5° in all specimens. For the mid-anterior approach, Distal Angle<sub>M</sub> was a mean of 53.9°  $\pm$  14.9° and Anterior Angle<sub>M</sub> was a mean of 33.4°  $\pm$  15.6°. For the anterolateral approach, Distal Angle<sub>L</sub> was a mean of 14.5°  $\pm$  14.2° and Anterior Angle<sub>L</sub> was a mean of 4.5°  $\pm$  13.6°. However, in the present study, methylene blue was successfully injected into the joint capsule in all specimens using either technique, providing support for the safety and efficacy of both approaches when performed by an experienced surgeon.

Not surprisingly, a higher distance from the insertion point of the needle to the nearest branch of the LFCN was recorded with the anterolateral approach compared with the mid-anterior approach. However, no perforations of the LFCN occurred in the present study, and all needles were placed at least 11.8 mm away from the nearest branch of the LFCN with the mid-anterior approach; this can be considered a safe distance regarding the potential risk of LFCN injury. The LFCN passes underneath the inguinal ligament before coursing distally on the surface of the sartorius muscle. Its path is inconsistent, varying anywhere from 0 to 5 branches. This places the LFCN, particularly the

most lateral branches, at increased risk during placement of the mid-anterior portal.<sup>13</sup> A previous cadaveric assessment for safe portal placement in hip arthroscopy reported a mean distance between the LFCN and the mid-anterior portal of 25.2  $\pm$  9.3 mm (range: 9-38) in 10 specimens.<sup>7</sup> The sample presented in this study had a mean distance from the mid-anterior approach to the LFCN of 19.3  $\pm$  7.9 mm (range: 11.8-30). The anterior approach, which has been reported to be located closer to the LFCN than the mid-anterior approach (mean: 15.4 mm; range: 1-28 mm),<sup>7</sup> was performed by Meidan et al.<sup>2</sup> in 45 patients. They reported 3 cases (6.6%) of LFCN irritation, but these symptoms were minor and resolved within 24 hours, supporting the safety of this distance from the nerve.

With the advent of biological treatments, joint injection arises as an essential treatment tool. A diagnostic intra-articular hip injection test provides the greatest clinical relevance regarding the presence of intra-articular hip lesions as a cause of symptoms and disability.<sup>1</sup> A recent meta-analysis reported a sensitivity of 97% and a specificity of 91% when detecting early hip osteoarthritis in symptomatic patients.<sup>14</sup> Pateder and Hungerford<sup>15</sup> showed 100% sensitivity and 81% specificity for injections to distinguish hip versus spine pain. A diagnostic injection can differentiate intra-articular and extra-articular pain sources if the relief obtained is considerable. For the above-mentioned reasons, it is vital to determine if nonguided injections are feasible, accurate, and safe to perform.

In addition to hip injections, hip arthrocentesis is a vital tool in the physician's diagnostic armamentarium. Distinguishing between septic arthritis and other causes of nontraumatic hip pain can be difficult in pediatric and adult patients; hip arthrocentesis has an important role in these clinical situations. The diagnosis is typically made by synovial fluid analysis through hip arthrocentesis, and identification and aspiration of a hip joint effusion under ultrasound guidance is a well-established procedure in the fields of orthopaedic surgery and interventional radiology.<sup>16</sup> Although this study presented a high variability regarding distance and angle measurements, the mid-anterior and anterolateral approaches (arthrocentesis) using anatomic landmarks appear to be safe and potential options in

clinical practice for differential diagnosis between septic arthritis and other causes of nontraumatic hip pain.

The current study provides a detailed analysis of insertion angles for modified mid-anterior and anterolateral approaches, and shows a large amount of variability when performing non-image-guided injections in a simulated clinical environment. Previously, Robertson and Kelly<sup>7</sup> reported approximate insertion angles for standard mid-anterior (35° cephalad, 25° posterior) and anterolateral (15° cephalad, 15° posterior) portals used for central compartment access during hip arthroscopy. The estimated trajectories in that study were presented to serve as guidelines for hip arthroscopy. Although the reported means in the present study can be used as more detailed guidelines to access the hip joint using the described methods, these results indicate that variability should not be unexpected in the clinical setting to achieve success.

A potential way to easily find the mid-anterior approach location is to draw a line along the anterior femoral cortex (ASIS line) and another line at the level of the superior aspect of the greater trochanter, perpendicular to the first one. After that, a third line is drawn at a 45° angle bisecting both lines. Then, the physician should follow the third line in its direction to the medial aspect of the thigh, seeking for a soft spot that defines the muscular interval between the tensor fascia lata and the sartorius. This spot is the entry point of the mid-anterior approach. It is important to pay special attention not to cross the ASIS line to avoid neurovascular injuries.

A recent systematic review and meta-analysis<sup>3</sup> showed a significantly higher accuracy for ultrasound-guided hip joint injections compared with those that are landmark guided. Although most subspecialties have moved away from landmark-guided hip joint injections, it continues to be used and advocated for in clinical practice.<sup>2,6,8</sup> A cadaveric study using anatomic landmarks by Leopold et al.<sup>4</sup> reported a success rate of 60% using the anterior approach and 80% using the lateral approach. Another study assessing the accuracy of landmark-based intra-articular injections to the hip joint in 43 consecutive hips with needle placement through an anterolateral approach with fluoroscopic verification showed a success rate of 65.1%.<sup>8</sup> Even with a high degree of distance and angle measurements variability, this study accomplished a 100% successful injection rates in both groups (anterolateral and mid-anterior).

### Limitations

One of the limitations of this study was the small sample size. The lack of specimens' radiographic evaluation did not allow identifying and measuring objective radiographic parameters such as the presence of osteoarthritis, neck shaft angle, and femoral neck

anteversion. Because each individual's bony anatomy is somewhat different, subtle differences in starting positions are often necessary to achieve the desired intra-articular locations. The present study did not include female and pediatric specimens; therefore, conclusions cannot yet be established about both genders and pediatric population. However, isolation of genders minimized variability between the specimens. One high-surgical volume hip-preservation surgeon (M.J.P.) performed all the injections. The surgeon's comfort with hip anatomy may allow accuracy that is difficult to obtain in a setting in which one has less familiarity with intra-articular and arthroscopic hip anatomy. Although the results of this study showed a high degree of variability in height and weight between specimens, it may be possible to standardize needle angles and position given constant sizes of hips; because of this, more research in this field is necessary.

### Conclusions

This study showed that mid-anterior and anterolateral approaches for non-image-guided hip injections or arthrocentesis can avoid the LFCN and be effectively performed in males, despite the exhibited variability in the quantitative descriptions of these techniques. The landmarks and measurements presented can be used as general guidelines for clinical studies regarding hip arthrocentesis and injections.

### Acknowledgment

The authors thank David M. Civitarese, B.A., for his assistance with specimen and supply acquisition and organization and Grant J. Dornan, M.S., for his assistance with statistical analysis.

### References

1. Byrd JW. Femoroacetabular impingement in athletes: Current concepts. *Am J Sports Med* 2014;42:737-751.
2. Mei-Dan O, McConkey MO, Petersen B, McCarty E, Moreira B, Young DA. The anterior approach for a non-image-guided intra-articular hip injection. *Arthroscopy* 2013;29:1025-1033.
3. Hoeber S, Aly AR, Ashworth N, Rajasekaran S. Ultrasound-guided hip joint injections are more accurate than landmark-guided injections: A systematic review and meta-analysis. *Br J Sports Med* 2016;50:392-396.
4. Leopold SS, Battista V, Oliverio JA. Safety and efficacy of intraarticular hip injection using anatomic landmarks. *Clin Orthop Relat Res* 2001;391:192-197.
5. Howse EA, Botros DB, Mannava S, Stone AV, Stubbs AJ. Basic hip arthroscopy: Anatomic establishment of arthroscopic portals without fluoroscopic guidance. *Arthrosc Tech* 2016;5:e247-e250.
6. Singh J, Khan WS, Marwah S, Wells G, Tannous DK, Sharma HK. Do we need radiological guidance for intra-articular hip injections? *Open Orthop J* 2014;8:114-117.

7. Robertson WJ, Kelly BT. The safe zone for hip arthroscopy: A cadaveric assessment of central, peripheral, and lateral compartment portal placement. *Arthroscopy* 2008;24:1019-1026.
8. Kurup H, Ward P. Do we need radiological guidance for hip joint injections? *Acta Orthop Belg* 2010;76:205-207.
9. Daley EL, Bajaj S, Bisson LJ, Cole BJ. Improving injection accuracy of the elbow, knee, and shoulder: Does injection site and imaging make a difference? A systematic review. *Am J Sports Med* 2011;39:656-662.
10. Heidari N, Pichler W, Grechenig S, Grechenig W, Weinberg AM. Does the anteromedial or anterolateral approach alter the rate of joint puncture in injection of the ankle?: A cadaver study. *J Bone Joint Surg Br* 2010;92:176-178.
11. Byrd JW, Pappas JN, Pedley MJ. Hip arthroscopy: An anatomic study of portal placement and relationship to the extra-articular structures. *Arthroscopy* 1995;11:418-423.
12. Fleiss J. *Statistical methods for rates and proportions*. Ed 2. New York, NY: Wiley, 1981.
13. Grothaus MC, Holt M, Mekhail AO, Ebraheim NA, Yeasting RA. Lateral femoral cutaneous nerve: An anatomic study. *Clin Orthop Relat Res* 2005;437:164-168.
14. Dorleijn DM, Luijsterburg PA, Bierma-Zeinstra SM, Bos PK. Is anesthetic hip joint injection useful in diagnosing hip osteoarthritis? A meta-analysis of case series. *J Arthroplasty* 2014;29:1236-1242.e1231.
15. Pateder DB, Hungerford MW. Use of fluoroscopically guided intra-articular hip injection in differentiating the pain source in concomitant hip and lumbar spine arthritis. *Am J Orthop (Belle Mead NJ)* 2007;36:591-593.
16. Freeman K, Dewitz A, Baker WE. Ultrasound-guided hip arthrocentesis in the ED. *Am J Emerg Med* 2007;25:80-86.