

Technical Note

Repair of Proximal Hamstring Tears: A Surgical Technique

Gilbert Moatshe, M.D., Jorge Chahla, M.D., Alexander R. Vap, M.D., Marcio Ferrari, M.D., George Sanchez, B.S., Justin J. Mitchell, M.D., and Robert F. LaPrade, M.D., Ph.D.

Abstract: Proximal hamstring tears are among the most common sports-related injuries. These injuries often occur as strains or partial tears at the proximal muscle belly or the musculotendinous junction, with avulsion injuries of the proximal attachment occurring less frequently. Regardless of the mechanism, they produce functional impairment and negatively affect an athlete's performance. Various classifications for these injuries are reported in the literature. Early surgical treatment is recommended for patients with either a 2-tendon tear/avulsion with more than 2 cm retraction or those with complete 3-tendon tears. Surgery can be performed in the chronic phase but it is technically demanding because of scar formation and tendon retraction. This technical note describes a biomechanically validated surgical technique for repair of the proximal hamstring tears.

Proximal hamstring tears are among the most common sports-related injuries and are frequently seen during eccentric muscle contractions, forced hip hyperflexion, and ipsilateral knee extension and fall accidents.^{1,2} The hamstring muscle group consists of 3 posterior thigh muscles, including the semimembranosus, semitendinosus, and the biceps femoris muscles. The tendon of the long head of the

biceps femoris inserts laterally into the ischial tuberosity, while the tendon of the semitendinosus inserts medially. These 2 tendons merge to form the conjoined tendon. The semimembranosus tendon inserts laterally into the ischium, anterolateral to the footprint of the conjoined tendon.³

Injuries to this muscle complex can result in significant disability, prolonged recovery, and loss of time from sport. Several classification systems for hamstring injuries have been developed. Traditionally, hamstring injuries have been classified according to their clinical presentation ranging from grade 1 to grade 3. This classification system includes grade 1 (mild): overstretching but minimal loss of the structural integrity of the muscle-tendon unit; grade 2 (moderate): partial tear; and grade 3 (severe): total rupture.⁴ Wood et al.⁵ described a classification system based on anatomic location of injury, degree of tear (partial or complete), degree of muscle retraction, and involvement of the sciatic nerve (sciatic nerve tethering). Type 1 injuries are osseous avulsions, type 2 are tears at the musculotendinous junction, type 3 are incomplete tendon avulsions, type 4 are complete tendon avulsions with no or minimal retraction, and type 5 are complete tendon avulsions with retraction of the tendon ends. Type 5 may be associated with sciatic nerve tethering (type 5b).⁵

Injuries to the hamstring muscle complex can be largely separated into injuries of the muscle belly and those of the proximal tendon. Although most injuries to this muscle group are categorized as muscle strains,

From the Steadman Philippon Research Institute, (G.M., J.C., A.R.V., M.F., G.S., J.J.M., R.F.L.), Vail, Colorado, U.S.A.; The Steadman Clinic (R.F.L.), Vail, Colorado, U.S.A.; Department of Orthopaedic Surgery, Oslo University Hospital (G.M.), Oslo, Norway; and OSTRC, Norwegian School of Sports Sciences (G.M.), Oslo, Norway.

The authors report the following potential conflicts of interest or sources of funding: R.F.L. receives personal fees and institutional support from Smith & Nephew Endoscopy, Ossur Americas, and Arthrex. R.F.L. receives royalties and is a paid consultant for Smith & Nephew; is a paid consultant for Ossur; and receives royalties and is a paid consultant for Arthrex. In addition, R.F.L. receives institutional support from Siemens Medical Solutions USA, Small Bone Innovations, ConMed Linvatec, and Opedix. The Steadman Philippon Research Institute has received financial support not related to this research from all the above-mentioned organizations. G.M. has received research grants from Health South East, Norway, and from Arthrex. The financial support is not related to this work.

The investigation was performed at the Steadman Philippon Research Institute, Vail, Colorado, U.S.A.

Received August 12, 2016; accepted October 4, 2016.

Address correspondence to Robert F. LaPrade, M.D., Ph.D., Steadman Philippon Research Institute, 181 West Meadow Drive, Suite 1000, Vail, Colorado 81657, U.S.A. E-mail: rlaprade@thesteadmanclinic.com

© 2016 by the Arthroscopy Association of North America

2212-6287/16782/\$36.00

<http://dx.doi.org/10.1016/j.eats.2016.10.004>

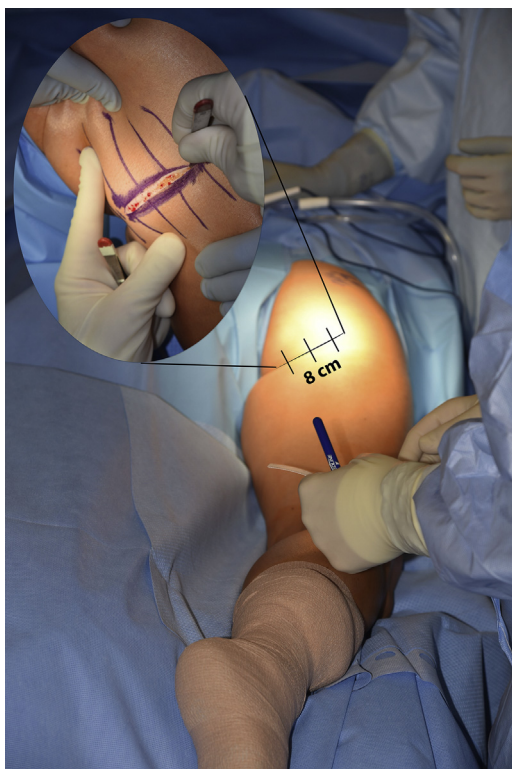


Fig 1. Image showing the patient in the prone position and the desired 8-cm incision centered over the ischium on the right side. The incision should be placed within the gluteal fold to help with postoperative cosmesis.

12% represent a tear or avulsion of the proximal attachment at the ischial tuberosity.⁶ Muscle strain and injuries to the musculotendinous junction can be treated successfully with nonoperative management. However, significant injuries, such as proximal tendon avulsions, treated nonsurgically have been reported to yield poor outcomes. When surgical treatment is warranted, early intervention within the first 4 weeks is recommended in patients with either a 2-tendon tear/avulsion with more than 2 cm retraction or those with complete 3-tendon tears.^{2,7} Surgical treatment can be performed in the chronic phase (>4 weeks), but it is often challenging because of scar tissue formation, which causes increased difficulty of a neurolysis of the sciatic nerve and mobilization of the retracted tendons.

Because treatment of proximal hamstring avulsion injuries can be challenging for both diagnosis and management, the purpose of this technical note is to describe our preferred approach for surgical repair of proximal hamstring tears and provide an overview of the rehabilitation protocol following surgery.

Patient Presentation and Physical Examination

Patients often report a history of an acute, sharp pain in the posterior thigh, which can be accompanied by an

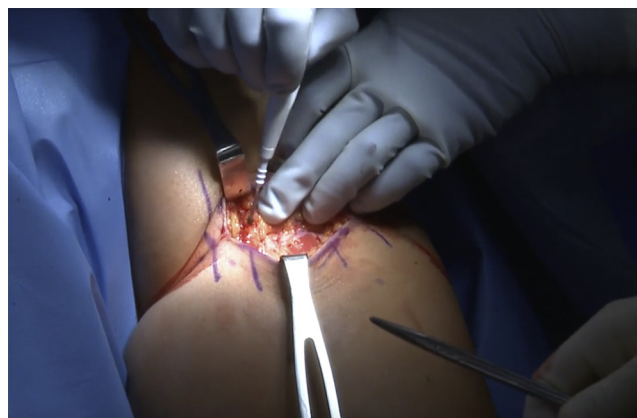

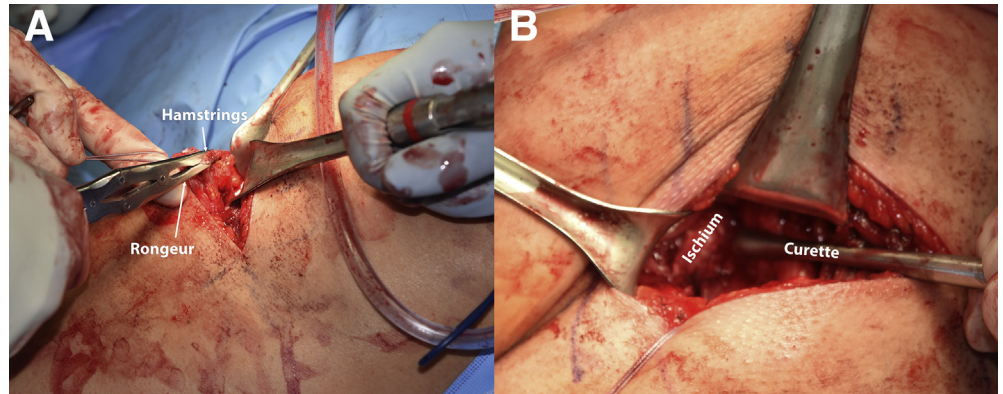
Fig 2. With the patient in the prone position, dissection is then carried down through the subcutaneous tissues to identify the inferior border of the gluteus maximus on the right side. Following gluteus maximus mobilization, a blunt broad retractor is used for proximal retraction. In cases of acute rupture, once the posterior fascia has been opened, blunt dissection down to the ischium may be easily performed.

audible pop during activity. Some patients report an insidious onset whereas others may have an acute or chronic onset. On examination, the patient may have ecchymosis at the posterior thigh with typical “stiff-legged” gait. Moreover, on palpation, tenderness may be elicited with confirmation of a defect. However, a defect may not always be easy to palpate because of the overlying soft tissue. Following palpation, hip and knee range of motion is assessed and any asymmetry is noted. Hamstring muscle strength, resisted active knee flexion, and eccentric loading with active knee flexion are measured while the examiner extends the knee to

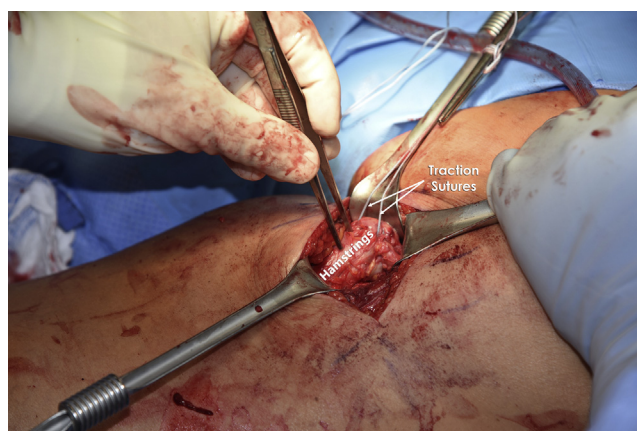

Fig 3. Intraoperative image showing mobilizing of the right hamstring tendons and placing of traction sutures. Once the sciatic nerve has been identified and tenolysis has been completed, traction sutures consisting of No. 2 Fiberwire are placed through the tendon. All adhesions should be then removed, allowing for full mobilization and excursion of the tendon.

Fig 4. (A) The ruptured end of the hamstrings is cleared of all scar tissue with a rongeur. (B) The ischium is cleared of all soft tissues with a rongeur. The bony surface is then prepared with a combination of a curette and a rasp.



30°. In addition, some provocation tests can be performed to evaluate the severity of the injury, including the Puranen-Orava test, bent knee stretch test, and modified bent knee stretch test.¹

A plain radiograph may suffice and adequately demonstrate an avulsion fracture from the ischial tuberosity. Magnetic resonance imaging is recommended to visualize the proximal injury location, number of involved tendons, extent of injury, degree of retraction, and concomitant soft tissue lesions in the zone of injury. Ultrasonographic imaging may be helpful in the acute phase, but use of this imaging modality is examiner-dependent.

Surgical Technique

Patient Positioning

The patient is brought to the operative suite and general anesthesia is performed supine and then the patient is placed in the prone position. Padded chest rolls are placed under all bony and soft tissue prominences, bilaterally, to prevent any pressure spots. A nonsterile clear self-adhesive impermeable drape is then placed around the proximal hip. The drape is placed directly adjacent to, and along the perineal area for maximum surgical exposure. A second self-adhesive drape is then placed around the superior aspect of the

hip. During this step, it is important to maintain exposure of the posterior gluteal fold. The entire operative extremity is then prepared with chloraprep. An impervious stockinet is placed around the foot, and the lower leg is then wrapped with an elastic wrap. Impervious self-adhesive drapes are placed around the proximal hip and thigh (Video 1).

Surgical Approach and Repair

Exposure of Ischium. The gluteal crease is identified and the ischium is palpated. An 8-cm cutaneous mark is drawn out centered over the ischium (Fig 1).

A full-thickness skin incision is made transversely with a No. 10 blade along the gluteal fold. Hemostasis is obtained with electrocautery. Dissection is then carried down through the subcutaneous tissues to identify the inferior border of the gluteus maximus (Fig 2). Metzenbaum scissors are used to incise the inferior fascia, thereby allowing for proximal mobilization of the gluteus maximus. Following gluteus maximus mobilization, a blunt broad retractor is used for proximal retraction. In cases of acute rupture, once the posterior fascia has been opened, blunt dissection down to the ischium may be easily performed. A large hematoma and fluid collection is often encountered. In a chronic rupture, a layer of adhesions and scar tissue overlying

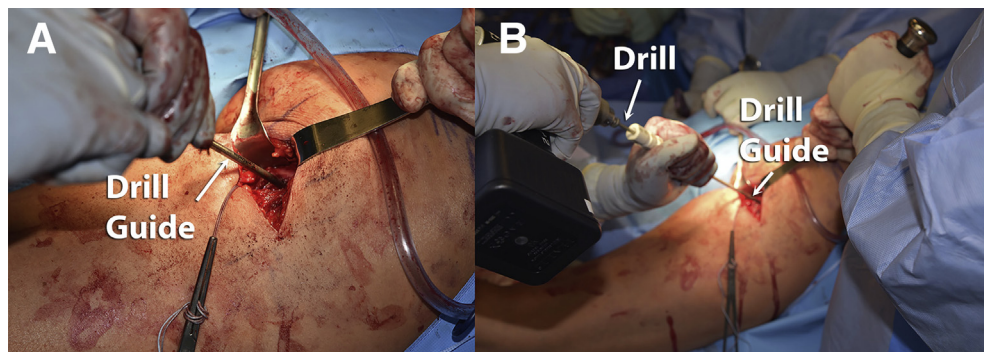


Fig 5. Intraoperative picture demonstrating the drilling for placement of suture anchors on the right ischium. (A) Drill guide for 2.9-mm Osteoraptor anchor is placed along the ischium in the previously prepared bony bed. (B) The anchor position is predrilled. Of note, anchors should be separated by 3 mm.

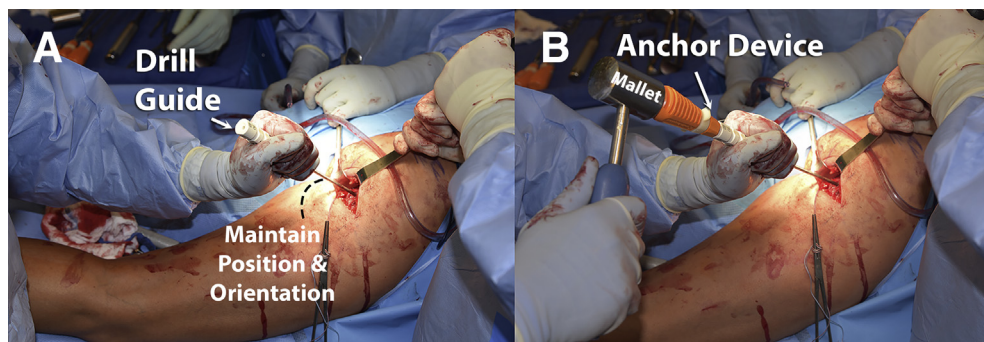


Fig 6. (A) Intraoperative image showing suture anchor placement on the right ischium. The drill guide is left in place to ensure accurate anchor placement orientation and (B) anchor device insertion through the guide. After inserting the anchors, traction force is applied on the sutures to ensure that the anchors can hold.

the ischium and the hamstring tendons is commonly encountered. This layer is incised and careful dissection is performed to identify the ischium and the hamstring tendons. Once the tendons have been recognized, the sciatic nerve should then be identified. The sciatic nerve is located laterally to the proximal hamstring tendons and ischium. Once the sciatic nerve is dissected away from the surrounding soft tissues, and if necessary, a neurolysis of the nerve can be performed. Following completion of neurolysis, No. 2 Fiberwire (Arthrex, Naples, FL) traction sutures should be placed through the tendons (Fig 3).

With traction on the tendons, all adhesions and scarring are removed to allow full mobilization. Deep blunt retractors are then placed inferiorly, medially, and laterally, allowing full exposure of the ischium.

Anchor Placement and Suture Fixation. A rongeur is used to remove all soft tissue from the ischial attachment site of the proximal hamstrings. A curette and a rasp can then be used to freshen the bony surface (Fig 4).

Once the bony surface has been prepared, the repair anchors are inserted. The drill guide for a 2.9-mm

Osteoraptor anchor (Smith & Nephew, Andover, MA) is then placed along the ischium (Fig 5). From the proximal to distal aspect of the ischium, anchors should be placed with 3 mm of separation between each (Fig 6).

For a stable construct, up to a total of 5 anchors is recommended.⁸ Once the anchors are secured, a free needle is used to pass the sutures sequentially through

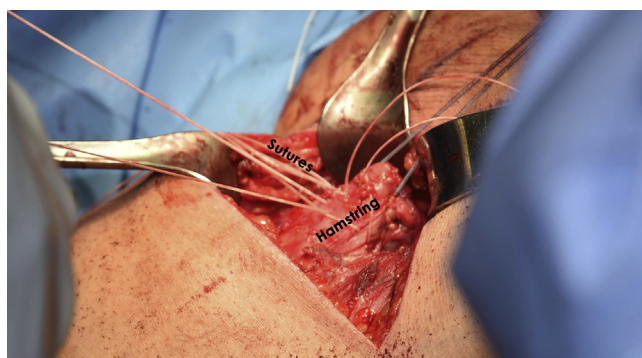


Fig 7. Intraoperative image showing hamstring repair on the right side. The free ends of each suture are sequentially passed through the end of the tendon with a free needle. The sutures are passed proximally to distally. Once all sutures have been passed, the respective limbs are tied in a square-knot fashion.

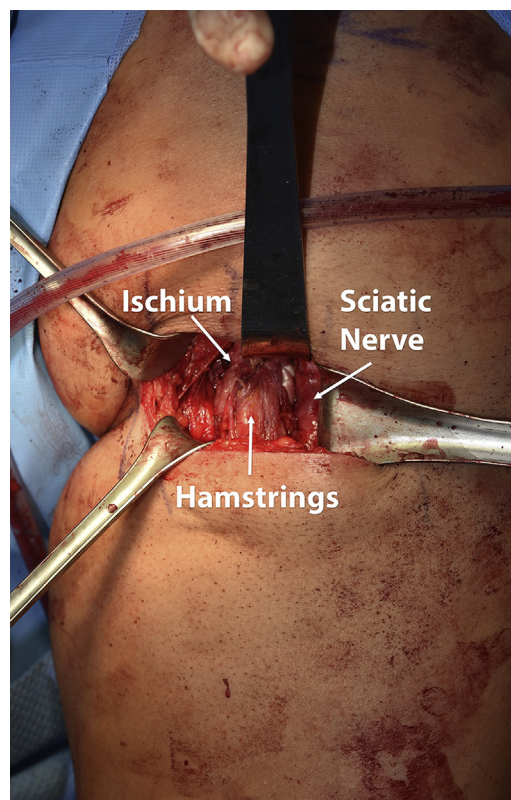


Fig 8. Intraoperative image showing hamstring repair on the right side. Five-anchor repair provides an extremely secure fixation of the hamstrings to the ischium. The sciatic nerve should be protected throughout the case. The nerve is located just lateral to the hamstring and the ischium.

Table 1. Advantages and Disadvantages of Proximal Hamstring Reconstruction

Advantages	Disadvantages
Often the defect can be palpated through the skin, guiding the correct placement of the incision.	In chronic cases, the palpation of the defect may be unreliable.
The incision performed in the gluteal fold provides a reliable exposure and adequate subsequent cosmetic healing.	A transverse incision in the gluteal fold can be difficult for exposure in patients with a hypertrophic gluteus maximus or a deep subcutaneous fat layer (a longitudinal incision can be performed).
Proximal hamstring repair improves outcomes in both acute and chronic injuries.	Chronic injuries can lead to muscle atrophy and fibrosis, thereby increasing the difficulty of the repair.
When performed in an acute setting, the complications and reruptures of proximal hamstring repair are lower.	Augmentation with autografts/allografts may be considered in chronic cases.
This approach provides an effective way to do a meticulous hemostasis, avoiding hematoma formation.	If the hemostasis is not done correctly, hematoma formation can lead to a greater risk of infection and sciatic nerve compression.

the tendon with full-thickness bites. Each free suture limb should be passed through the tendon (Fig 7).

Each suture can then be tied with squared surgical knots. If the repair exhibits overtensioning or tendon approximation up to the ischium is difficult, the knee may be flexed to relieve tension off of the repair. Once all knots have been tied, the knee should be guided through a range-of-motion examination to evaluate the repair integrity and ensure the hamstrings have not been overtensioned. Following completion, the repair should be inspected and it should be verified that the sciatic nerve is not tethered (Fig 8). The advantages and disadvantages as well as the pearls and pitfalls associated with this technique are reported in Table 1 and Table 2, respectively.

Postoperative Rehabilitation

Following proximal hamstring repair, patients are restricted to toe-touch weight bearing and must use crutches with a knee brace in full extension for the first 6 weeks postoperatively to protect the surgical repair.

Additionally, during these first 6 weeks, trunk and excessive hip flexion are limited, with no active hamstring exercises allowed. A supervised physical therapy program lasting 4 months is recommended. Major milestones to be achieved by this physical therapy program include helping patients regain the ability to complete daily living tasks during the first 6 weeks, then integrate light hamstring-strengthening exercises (e.g., standing leg curls) and total leg-strengthening exercises (e.g., heel raises, general hip strengthening) during weeks 6 to 8, with the goal of reaching full range of motion by end of week 8. During weeks 8 to 12, nonimpact aerobic exercises (e.g., stationary bike, Stairmaster) are initiated and total leg-strengthening exercises increase in intensity as tolerated. By the end of week 12, the patient should be able to perform daily living tasks without restriction and nonimpact aerobic activities without pain. Physical therapy for this injury is designed to first protect the surgical repair, and then gradually to restore functionality with a steady progress in exercise intensity.

Table 2. Pearls and Pitfalls of Proximal Hamstrings Reconstruction

Pearls	Pitfalls
Patient positioning must allow for free mobilization of the limb.	Because of the prone position of the patient during the procedure, induction of general anesthesia must be done with care.
The correct knowledge of the anatomy of the proximal hamstrings and surrounding nerves is essential for a successful treatment outcome.	In chronic cases, the anatomy can be considerably distorted as a result of fibrosis and muscle atrophy.
Identifying the posterior femoral cutaneous nerve and sciatic nerve is essential to avoid iatrogenic injury to these structures.	Adhesions will lead to greater difficulty in performing a sciatic nerve neurolysis and successful identification of surrounding nerves.
A sciatic neurolysis may be necessary to protect the nerve and avoid iatrogenic injuries if it is tethered to the hamstring tear.	Care must be taken with the use of deep retractors to avoid damage to surrounding neurovascular structures.
Incisions through the gluteus maximus can be performed in line with its fibers if the identification of the proximal hamstrings "footprint" cannot be reached with retraction of this muscle.	Superior gluteal nerve injuries can occur with this approach; therefore, dissection must be performed carefully to minimize the risk of injury.
The sciatic nerve is situated lateral to the tendons; therefore, a neurolysis is more easily performed if started at the distal aspect of the nerve.	Be careful when removing tissue from the proximal tendon to avoid excessive shortening.
Whenever the proximal lesion is an avulsion from the ischial tuberosity, all remaining soft tissue must be removed at its bony attachment to establish a large osseous contact surface.	
The use of a brace that restricts hip flexion may be used for protection of the surgical repair.	

Discussion

This technical note details our technique for an anatomic proximal hamstring repair. Given that hamstring strains account for 25% to 30% of all muscle strains, the hamstrings are regarded as one of the most highly affected body sites in the injured athletic population.^{3,9,10} There is a wide range of injuries within the proximal insertion of the hamstrings, which vary from musculotendinous strains (disruption of the musculotendinous junction) to avulsion injuries (injury to the tendon bone unit). It has been consistently reported that the most affected muscle of the 3 is the biceps femoris.¹¹⁻¹³ However, there is conflicting literature regarding which is the second most commonly injured proximal hamstring muscle.¹⁴⁻¹⁶ The mechanism of injury is generally forced eccentric contraction with the knee extended and the hip in hyperflexion and a forced eccentric contraction of the hamstring muscle complex.^{2,17} Usually, these lesions occur during sports participation or slip and fall accidents and can produce significant functional impairment that can greatly affect athletes.¹⁷⁻²⁰

Nonoperative treatment of proximal hamstring injuries is most commonly recommended for low-grade partial tears and insertional tendinopathy. However, nonoperative treatment in athletes has been reported to produce less than optimal results, with complaints of ongoing cramping and weakness seen in up to 80% of these athletes.²¹ Surgical treatment is recommended for patients with either a 2-tendon tear/avulsion with >2 cm retraction or those with complete 3-tendon tears. Several surgical repair procedures have been described in the literature, including both endoscopic and open approaches.⁹ Currently, transosseous fixation techniques have been substituted by suture anchor systems, which have emerged as the gold standard treatment probably because of less technical demand and decreased risk of surrounding tissue damage.²²

A recent systematic review concluded that although the quality of the studies is poor, surgical repair of proximal hamstring avulsions appeared to result in satisfying outcomes based on subjective patient reporting.²³ However, decreased strength, residual pain, and decreased activity level were reported by a significant number of patients after repair. Minimal differences in outcomes of acute and delayed repairs were found.²³ Concerning the repair technique, a cadaveric study from our group indicated that repairs using 5 small anchors yield similar results to the intact tendon and were significantly stronger than repairs using only 2 large or 2 small anchors in the repair of complete avulsions of the proximal hamstring tendons.⁸ Thus, this is the rehabilitation protocol that this study uses. Lastly, Harvey et al. recommended fixation

of the hamstrings at full extension because increasing hip flexion from 0° to 90° increased the displacement of proximal hamstring repairs.²⁴

Given the positive outcomes noted in the literature, we recommend repair of avulsion injuries to the proximal hamstring. In this technical note, we present our approach for an anatomic proximal hamstring repair. This technique has been validated biomechanically, and we believe it provides a strong repair that can tolerate rehabilitation and give good long-term results. Future long-term studies with larger sample sizes are necessary to assess patient satisfaction and efficacy of proximal hamstring repair.

References

1. Ahmad CS, Redler LH, Ciccotti MG, Maffulli N, Longo UG, Bradley J. Evaluation and management of hamstring injuries. *Am J Sports Med* 2013;41:2933-2947.
2. Cohen S, Bradley J. Acute proximal hamstring rupture. *J Am Acad Orthop Surg* 2007;15:350-355.
3. Philippon MJ, Ferro FP, Campbell KJ, et al. A qualitative and quantitative analysis of the attachment sites of the proximal hamstrings. *Knee Surg Sports Traumatol Arthrosc* 2015;23:2554-2561.
4. Clanton TO, Coupe KJ. Hamstring strains in athletes: Diagnosis and treatment. *J Am Acad Orthop Surg* 1998;6:237-248.
5. Wood DG, Packham I, Trikha SP, Linklater J. Avulsion of the proximal hamstring origin. *J Bone Joint Surg Am* 2008;90:2365-2374.
6. Koulouris G, Connell D. Evaluation of the hamstring muscle complex following acute injury. *Skeletal Radiol* 2003;32:582-589.
7. Harris JD, Griesser MJ, Best TM, Ellis TJ. Treatment of proximal hamstring ruptures—A systematic review. *Int J Sports Med* 2011;32:490-495.
8. Hamming MG, Philippon MJ, Rasmussen MT, et al. Structural properties of the intact proximal hamstring origin and evaluation of varying avulsion repair techniques: An in vitro biomechanical analysis. *Am J Sports Med* 2015;43:721-728.
9. Guanche CA. Hamstring injuries. *J Hip Preserv Surg* 2015;2:116-122.
10. Lempainen L, Banke IJ, Johansson K, et al. Clinical principles in the management of hamstring injuries. *Knee Surg Sports Traumatol Arthrosc* 2015;23:2449-2456.
11. Orchard J, Steet E, Walker C, Ibrahim A, Rigney L, Houang M. Hamstring muscle strain injury caused by isokinetic testing. *Clin J Sport Med* 2001;11:274-276.
12. Woods C, Hawkins RD, Maltby S, Hulse M, Thomas A, Hodson A. The Football Association Medical Research Programme: An audit of injuries in professional football—analysis of hamstring injuries. *Br J Sports Med* 2004;38:36-41.
13. De Smet AA, Best TM. MR imaging of the distribution and location of acute hamstring injuries in athletes. *AJR Am J Roentgenol* 2000;174:393-399.

14. Bencardino JT, Mellado JM. Hamstring injuries of the hip. *Magn Reson Imaging Clin N Am* 2005;13:677-690. vi.
15. Beltran L, Ghazikhanian V, Padron M, Beltran J. The proximal hamstring muscle-tendon-bone unit: A review of the normal anatomy, biomechanics, and pathophysiology. *Eur J Radiol* 2012;81:3772-3779.
16. De Paulis F, Cacchio A, Michelini O, Damiani A, Saggini R. Sports injuries in the pelvis and hip: diagnostic imaging. *Eur J Radiol* 1998;27:S49-S59 (suppl 1).
17. Cohen SB, Rangavajjula A, Vyas D, Bradley JP. Functional results and outcomes after repair of proximal hamstring avulsions. *Am J Sports Med* 2012;40:2092-2098.
18. Chahal J, Bush-Joseph CA, Chow A, et al. Clinical and magnetic resonance imaging outcomes after surgical repair of complete proximal hamstring ruptures: Does the tendon heal? *Am J Sports Med* 2012;40:2325-2330.
19. Chakravarthy J, Ramisetty N, Pimpalnerkar A, Mohtadi N. Surgical repair of complete proximal hamstring tendon ruptures in water skiers and bull riders: A report of four cases and review of the literature. *Br J Sports Med* 2005;39:569-572.
20. Cross MJ, Vandersluis R, Wood D, Banff M. Surgical repair of chronic complete hamstring tendon rupture in the adult patient. *Am J Sports Med* 1998;26:785-788.
21. Lempainen L, Sarimo J, Mattila K, Vaittinen S, Orava S. Proximal hamstring tendinopathy: Results of surgical management and histopathologic findings. *Am J Sports Med* 2009;37:727-734.
22. Sandmann GH, Hahn D, Amereller M, et al. Mid-term functional outcome and return to sports after proximal hamstring tendon repair. *Int J Sports Med* 2016;37:570-576.
23. van der Made AD, Reurink G, Gouttebauge V, Tol JL, Kerkhoffs GM. Outcome after surgical repair of proximal hamstring avulsions: A systematic review. *Am J Sports Med* 2015;43:2841-2851.
24. Harvey MA, Singh H, Obopilwe E, Charette R, Miller S. Proximal hamstring repair strength: A biomechanical analysis at 3 hip flexion angles. *Orthop J Sports Med* 2015;3. 2325967115576910.